

## Original Research Article

# Comparative study of outcomes of type 1 tympanoplasty with and without anterior tucking

Sonee Thingujam\*, Jayita Poduval

Department of Otorhinolaryngology Head and Neck Surgery, Aarupadai Veedu Medical College and Hospital, Puducherry, India

**Received:** 09 May 2021

**Revised:** 17 September 2021

**Accepted:** 18 September 2021

**\*Correspondence:**

Dr. Sonee Thingujam,

E-mail: drsoneebee@gmail.com

**Copyright:** © the author(s), publisher and licensee Medip Academy. This is an open-access article distributed under the terms of the Creative Commons Attribution Non-Commercial License, which permits unrestricted non-commercial use, distribution, and reproduction in any medium, provided the original work is properly cited.

### ABSTRACT

**Background:** Type-1 tympanoplasty is the functional restoration of the normal middle ear by repairing the tympanic membrane (TM). Different techniques are still evolving to devise a way to give optimal graft uptake and hearing improvement with minimal instrumentation. Various studies have been done to assess the role of anterior tucking in type-1 tympanoplasty and to assess its superiority over other methods in repairing subtotal perforations and large perforations involving the anterior quadrant.

**Methods:** This study was done to compare the outcomes of endoscopic type-1 tympanoplasty with and without anterior tucking. 60 cases of chronic otitis media (COM) mucosal type were divided into 2 groups of 30 patients each. Group 1 underwent endoscopic type-1 tympanoplasty with anterior tucking and group 2 underwent endoscopic type-1 tympanoplasty without anterior tucking. The outcomes were evaluated after 6 months and compared in terms of graft uptake and hearing gain.

**Results:** The mean air-bone gap improvement was  $13.16 \pm 2.65$  in group 1 and  $12.90 \pm 3.78$  in group 2, which had statistically insignificant differences indicating similar hearing outcomes in both the groups. 96.7% successful graft uptake was achieved in group 1 and 90% in group 2, showing statistically insignificant differences indicating similar graft uptake rates in both the groups.

**Conclusions:** Anterior tucking with endoscopic type-1 tympanoplasty could provide good graft support and efficient hearing improvement but cannot be labelled as a mandatory step in repairing subtotal perforations or large perforations involving anterior quadrant as the outcomes are comparable to the endoscopic type-1 tympanoplasty done without anterior tucking.

**Keywords:** Type-1 tympanoplasty, Anterior tucking, Chronic otitis media

### INTRODUCTION

The TM is a pearly grey coloured semitransparent oval-shaped membrane that forms the lateral wall of the middle ear cavity (MEC) that isolates the MEC from the external auditory canal (EAC), thus acting as a protector of the middle ear. It has a major contribution to the normal hearing mechanism. TM perforation is the most common acquired disease of TM, which can result from

either trauma or infection due to acute or COM. Although traumatically perforated TM tends to regenerate and heal in a spontaneous manner, perforation due to COM heals poorly.<sup>1</sup> TM perforation leads to disturbance in conducting pathway of sound, causing conductive hearing loss.

Tympanoplasty is a surgical procedure that eliminates the pathology of the middle ear and provides a normal

middle ear hearing mechanism with or without repair of TM, whereas myringoplasty is limited only up to TM repair without further manipulating the ossicles or middle ear. Since the inception of the surgical procedures for repair of the perforated TM in 1640 by Banzer and the description of tympanoplasty in 1951 by Wullstein, myringoplasty and tympanoplasty has come a long way and has evolved tremendously.<sup>2</sup> The ideal technique of performing the surgery to give optimal results is still evolving. Studies are still going on to devise a way to give optimal graft uptake and maximum postoperative hearing improvement with minimal instrumentation. As per the classification of Wullstein, type 1 tympanoplasty is the functional restoration of the normal middle ear by repairing the TM.<sup>3</sup> Success of type-1 tympanoplasty is subjected to numerous factors like technique, size and site of perforation, graft material, duration of the dry ear, associated middle ear cleft pathology, state of the contralateral ear, smoking, socioeconomic status and history of earlier ear surgery.<sup>4,6</sup>

Transcanal endoscopic repair of TM perforation has been in practice since the 1990s. Its superiority is less invasiveness and allows multi-angled complete visualization of the TM and other areas that generally remain out of sight or difficult with the microscope.<sup>7,8</sup> Various studies have been done comparing the conventional microscopic postauricular approach and endoscopic transcanal approach for TM repair with comparable outcomes with regard to graft success and hearing gain and the endoscopic method having additional advantages of anterior margin visibility, minimal invasiveness, lesser operative time, lesser postoperative pain and better cosmesis.<sup>9-14</sup> Regarding the size, large and subtotal perforations have lesser rates of success of graft uptake whereas in terms of the site, anterior and marginal perforations have been reported for having a negative impact over the success of type-1 tympanoplasty.<sup>15-17</sup> There are numerous studies highlighting the problematic anterior quadrant perforation repair for which several modified techniques and methods have been incorporated like the Gerlach quilt method, anterior hitch method, Kerr flap technique, 360-degree subannular tympanoplasty, anterior interlay myringoplasty, window shade technique, circumferential flap method and anterior tucking technique.<sup>18-24</sup> In the literature, tympanoplasty with anterior tucking by a microscopic postauricular approach using temporalis fascia had success rates varying from 88% to 98%.<sup>25,26</sup>

## METHODS

This prospective comparative study was carried out in the department of otorhinolaryngology, Aarupadai Veedu medical college and hospital, Puducherry after obtaining clearance from the institutional ethical committee from October 2018 to September 2020 to compare the outcomes of type 1 tympanoplasty with anterior tucking and without anterior tucking, both done through endoscopic transcanal approach. The success of graft

uptake and hearing gain was evaluated and compared after 6 months. Inclusion criteria were patients of both sexes between 15 to 60 years of age having COM mucosal type, inactivity for 4 weeks or more with large perforation involving anterior quadrant or subtotal perforation and mild to moderate conductive hearing loss less than 45 dB. Patients with COM mucosal type active stage, COM squamosal type, patients with sensorineural or mixed hearing loss or conductive hearing loss above 45 dB, patients having COM with effusion in contralateral ear, COM with complications, patients having active infection of the nose, paranasal sinuses or throat and patients with a history of previous otological surgeries were excluded from the study. 60 patients of COM (mucosal type) undergoing type 1 tympanoplasty who fulfilled the inclusion and exclusion criteria were inducted after taking an informed and written consent.

All the patients presenting with clinical features of chronic otitis media and mucosal type were evaluated by taking the complete clinical history and thorough ear, nose and throat examination followed by investigations that included X-ray bilateral mastoids (Law's view) and pure tone audiometry. Air bone gap (AB gap) was assessed by subtracting the average bone conduction threshold (BC) from the average air conduction threshold (AC). The average values were calculated in 3 frequencies, that is, 500, 1000 and 2000 Hz. The diagnostic nasal examination was done to rule out any nasal pathology. Routine haematological tests were done before pre-anaesthetic assessment. Group 1 included 30 patients who underwent endoscopic type 1 tympanoplasty with anterior tucking (TIT+AT) and group 2 included 30 patients who underwent endoscopic type 1 tympanoplasty without anterior tucking (TIT).

Informed and written consent was documented. Xylocaine test was done by giving 0.1 ml of 2% xylocaine intradermally. Tetanus injection 0.5 ml was given intramuscularly. Preoperative dose of antibiotic was given 30 minutes before the surgery. All of the cases were done through a transcanal approach using an endoscope. Under general anaesthesia or local anaesthesia with intravenous sedation, the patient was made to lie down in a supine position with the head turned away from the surgeon at an angle of around 120 degrees achieved by carefully placing a folded towel between the opposite cheek and the table. The postauricular region was painted with alcohol and povidone-iodine solution followed by the draping of the area with sterile towel drapes to expose the surgical field. The area posterosuperior to the helix in the postauricular region and the external EAC covering all the quadrants were infiltrated with 2% lignocaine with 1:200000 adrenaline. An incision of approximately 2.5 cm was made near the hairline, posterosuperior to the helix of the pinna to reach the temporalis fascia from where it was harvested and kept aside to dry. TM was approached through the EAC using a 0-degree rigid endoscope with an outer diameter of 4 mm and having a length of 14 cm.

Under the clear endoscopic vision, the perforation edges and anterior annulus could be carefully visualized and freshening of the edges of the perforation all around was done. The tympanomeatal flap elevation was initiated by making an incision 5 mm lateral to the annulus posteriorly, the next ending it from 12 o'clock position to 7 o'clock position. Elevation of the tympanomeatal flap was done. Status of middle ear and ossicular intactness was assessed and confirmed after which medicated gelfoam was packed in the middle ear which would get absorbed spontaneously later. Placement of the properly trimmed and size-appropriate temporalis fascia graft was done was underlay technique. Readjustment was carefully done before the tympanomeatal flap was returned to its original position. EAC was packed with antibiotic soaked gelfoam to stabilize the graft and a cotton ball was placed in the external auditory orifice. The postauricular incision was sutured followed by proper dressing.

In the anterior tucking group (T1T+AT), the addition of a small 3-5 mm horizontal incision was made laterally, away from the annulus in the anterosuperior region of the wall of EAC before graft placement. Via this minute incision, the annulus was raised. After placing the temporalis fascia graft with underlay technique, a part of the graft was pulled to rest between the canal skin and the bony EAC. The following steps remained the same as the previous method. Regular postoperative follow up was done every week for one month, followed by monthly for the next 6 months. Evaluation for graft uptake and postoperative hearing gain was done after 6 months.

**Statistical analysis**

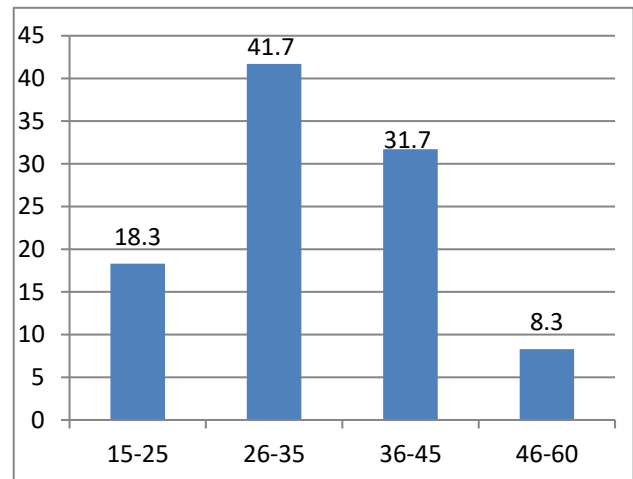
Data were presented as mean, standard deviation, percentages or the number of cases. Categorical data were analyzed using the Pearson Chi-square test. Independent sample t test was used to compare the continuous data between groups, paired sample t test was used to compare the continuous data within groups. Significance was defined by p values less than 0.05 using a two-tailed test. Data analysis was performed using IBM-SPSS version 21.0 (IBM-SPSS Science Inc., Chicago, IL).

**RESULTS**

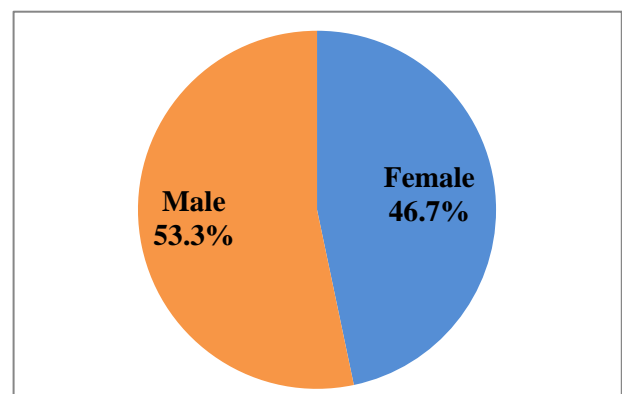
This study included 60 patients divided into two groups of 30 patients each. 30 patients in group 1 underwent endoscopic T1T+AT, while another 30 patients in group 2 underwent endoscopic T1T.

This study included patients of 15 to 60 years of age and had a maximum (41.6%) of the patients in the age group between 26 to 35 years (Figure 1). 53.3% of patients were male, whereas 46.7% were female (Figure 2). 51.6% of the total patients had left ear involvement, whereas 48.4% had involvement of the right ear (Figure 3). 60% of

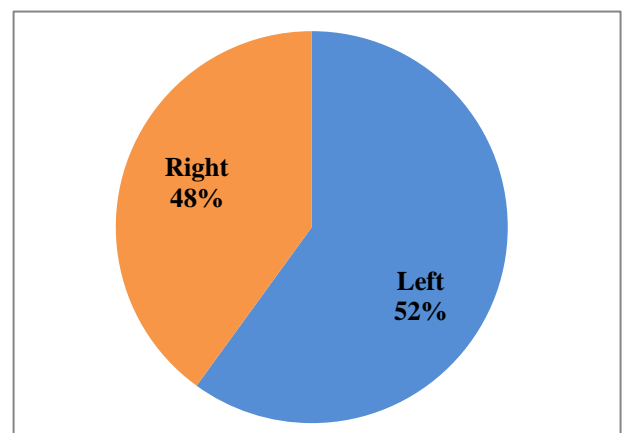
patients had large perforation, while the remaining 40% had subtotal perforation (Figure 4). There were statistically insignificant differences in the distribution of the age, gender and affected side among the study groups ( $p>0.05$ ). No statistically significant difference was noted in the distribution of the size of TM perforation among the study groups ( $p>0.05$ ) (Table 1).



**Figure 1: Age distribution of patients (in percentage).**



**Figure 2: Gender distribution of patients.**



**Figure 3: Affected side of COM.**

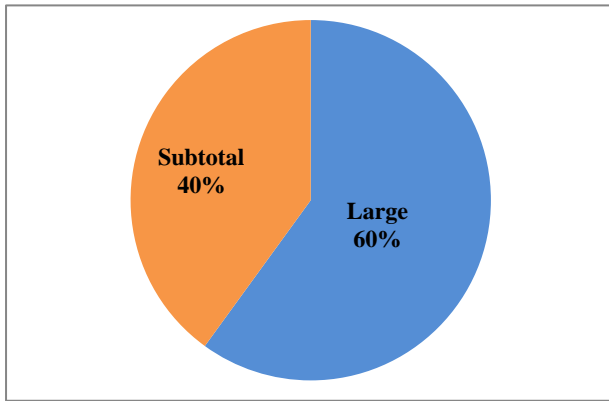


Figure 4: Size of TM perforation.

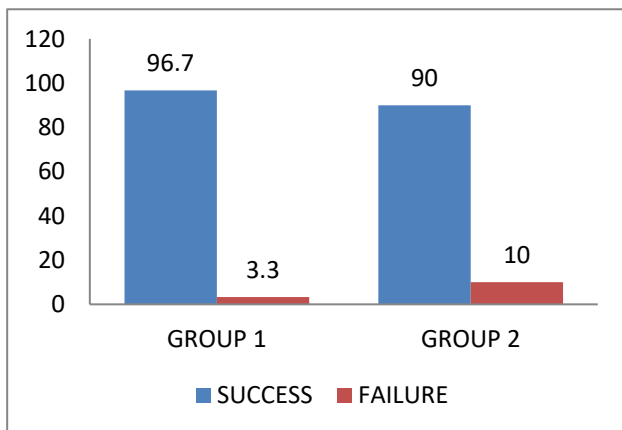


Figure 5: Graft uptake.

The mean preoperative AC in group 1 was 41.13±2.94 dB and group 2 was 41.76±3.07 dB, whereas the mean of

preoperative BC in group 1 was 11.30±2.46 dB and group 2 was 11.86±2.31 dB. The mean preoperative AB gap in group 1 was 29.83±2.32 dB and group 2 was 29.90±2.74 dB. There were statistically insignificant differences in AC, BC and AB gap between the 2 study groups (p>0.05) (Table 2).

In group 1 wherein the patients underwent endoscopic T1T+AT, the mean preoperative AC was 41.13±2.94 dB whereas postoperative AC was 27.80±3.25 dB, the mean preoperative BC was 11.30±2.46 dB while postoperative BC was 11.13±2.20 dB and the mean preoperative AB gap was 29.83±2.32 dB whereas postoperative AB gap was 16.67±2.91 dB. There were statistically significant improvements noted in AC and AB gap after endoscopic T1T with AT (p<0.0001), whereas BC improvement was statistically insignificant (p=0.319). In group 2 wherein the patients underwent endoscopic T1T without anterior tucking, the mean preoperative AC was 41.76±3.07 dB whereas postoperative AC was 28.81±4.67 dB, the mean preoperative BC was 11.86±2.31 dB whereas postoperative BC was 11.81±2.29 dB and the mean of preoperative AB gap was 29.90±2.74 dB whereas postoperative AB gap was 17±4.84 dB. There were statistically significant improvements noted in the AC and AB gap after endoscopic T1T (p<0.0001), whereas there was statistically insignificant BC improvement (p=0.755) as shown in Table 3.

The mean AB gap improvement in group 1 was 13.16±2.65 dB and group 2 was 12.90±3.78 dB. Comparison of AB gap improvement in group 1 and group 2 showed a statistically insignificant difference with a p value of 0.759, indicating similar hearing outcomes in both groups (Table 4).

Table 1: Distribution of size of TM perforation in group 1 and group 2.

Perforation size		Group 1	Group 2	Total	P value
Large	N	19	17	36	0.598
	%	52.8	47.2	100	
Subtotal	N	11	13	24	
	%	45.8	54.2	100	
Total	N	30	30	60	
	%	50.0	50.0	100	

Table 2: Preoperative AC, BC, AB gap in group 1 and group 2.

Pre-operative		Mean ± standard deviation	P value
AC	Group 1	41.13±2.94	0.423
	Group 2	41.76±3.07	
BC	Group 1	11.30± 2.46	0.370
	Group 2	11.86± 2.31	
AB gap	Group 1	29.83± 2.32	0.915
	Group 2	29.90± 2.74	

**Table 3: Preoperative and postoperative AC, BC, AB gap (in dB) in group 1 and group 2.**

Groups		Mean	Standard deviation	P value
Group 1	Preoperative AC	41.13	2.94	<0.0001
	Postoperative AC	27.80	3.25	
	Preoperative BC	11.30	2.46	0.319
	Postoperative BC	11.13	2.20	
	Preoperative AB gap	29.83	2.32	<0.0001
	Postoperative AB gap	16.67	2.91	
Group 2	Preoperative AC	41.76	3.07	<0.0001
	Postoperative AC	28.81	4.67	
	Preoperative BC	11.86	2.31	0.755
	Postoperative BC	11.81	2.29	
	Preoperative AB gap	29.90	2.74	<0.0001
	Postoperative AB gap	17.00	4.84	

**Table 4: Postoperative AB gap improvement.**

Groups		Mean±standard deviation	P value
AB-gap improvement (dB)	Group 1	13.16±2.65	0.759
	Group 2	12.90±3.78	

**Table 5: Postoperative graft uptake.**

Groups		Graft uptake		Total	P value
		Failure	Success		
Group 1	N	1	29	30	0.301
	%	3.3	96.7	100	
Group 2	N	3	27	30	
	%	10.0	90.0	100	
Total	N	4	56	60	
	%	6.7	93.3	100	

Graft success was seen in 93.3% of the total patients in which 96.7% successful graft uptake was noted in the first group and 90% graft success was noted in the second group as shown in Figure 5 showing a statistically insignificant difference in graft success with a p value of 0.301 indicating similar successful graft uptake rates in both the groups (Table 5).

**DISCUSSION**

There are numerous studies about the problematic repair of subtotal perforations and large perforations involving anterior quadrant for which several modified techniques and methods have been tried and evolving that can be incorporated for optimal results and to minimize the failure. Studies have been done to assess the role of anterior tucking in TIT and to compare it with various other techniques of repairing the TM. A study done by Prakash et al assessed the role of TIT+AT in repairing subtotal TM perforation through microscopic post auricular approach and underlay technique using temporalis fascia which concluded that TIT with anterior tucking gives satisfactory results with a graft success rate of 95.3% and 12.7 dB improvement of AB gap.<sup>24</sup>

This study aimed to compare the outcome of the endoscopic TIT with or without anterior tucking. Two groups, namely group 1 underwent endoscopic TIT+AT and group 2 underwent endoscopic TIT having thirty patients each. The study had a maximum (41.6%) of patients in the age group between 26 to 35 years. 53.3% were male and 46.7% were female. Maximum (40%) of the total patients were from the lower socio-economic class (class 5). 60% of total patients had large perforation while the remaining 40% had subtotal perforation. No statistically significant difference was there in the distribution of patients among the two groups in terms of age, gender, affected side and size of perforation.

In our study, 96.7% of patients had successful graft uptake in endoscopic TIT+AT done with underlay technique using temporalis fascia. The results were comparable with the results reported by Prakash et al for TIT+AT having a graft success rate of 95.3% and 12.7 dB improvement of AB gap.<sup>24</sup> Dhanapala et al reported a 98% graft success rate and mean hearing gain of 7.95 dB after 3 months of TIT with anterior tucking done for large central perforations by underlay method using temporalis fascia.<sup>25</sup>

A prospective randomized control trial was conducted by Shanbag et al in 2018 to compare the outcome of anterior tucking and cartilage support tympanoplasty for repairing subtotal TM perforations by postauricular underlay technique using temporalis fascia.<sup>26</sup> Postoperative evaluation done after 6 months showed that TIT+AT had a graft success rate of 88% with 13.9 dB mean conductive hearing gain compared to 100% graft success and 17.4 dB mean conductive hearing gain in the other group that underwent cartilage support tympanoplasty.

A study conducted by Burse et al to compare anterior tucking and cartilage support tympanoplasty for subtotal TM perforation repair reported successful graft uptake of 96% in both groups with significant hearing improvement.<sup>27</sup> However, the difference was significant between the postoperative hearing gain with anterior tucking group having 10.12 dB as mean AB gap whereas cartilage support group had a mean AB gap of 14.48 dB showing a better hearing gain in TIT+AT done using temporalis fascia.

In this study, 90% successful graft uptake was achieved with AB gap improvement of 12.9 dB in patients who underwent endoscopic TIT without anterior tucking done with underlay technique using temporalis fascia. This was comparable to results reported by Jyothi et al from the study done to compare endoscopic and microscopic myringoplasty, which had a successful graft uptake of 91.6% with AB gap improvement of 16 dB in the group operated through endoscopic transcanal approach.<sup>10</sup> Similar result was reported with 88% successful graft uptake after endoscopic underlay TIT done with temporalis graft.<sup>28</sup> However, Harugop et al reported 11.37 dB mean AB gap improvement but a lesser graft success rate of 82% after endoscopic myringoplasty done for medium to subtotal perforations.<sup>11</sup> Similar conclusion of 83% graft success rate was shown in a randomized control trial done by Lade et al.<sup>29</sup> In a retrospective study done by Tseng et al among patients who underwent endoscopic transcanal repair of anterior perforation of TM, there was the overall success of 93% for the graft uptake and 10.3 dB mean AB gap improvement.<sup>12</sup> On further classification, those with a perforation size of less than 50% had a 96% success rate and those with more than 50% perforation size had an 80% success rate. Nevertheless, all of these studies emphasized that the endoscopic technique gives as good results as the microscopic technique with regard to graft uptake and hearing gain, but endoscopic technique comes with advantages of intra-operative proper visibility of the complete TM, less surgical time and better postoperative recovery and cosmesis.

In our study, the outcomes were comparable with regard to graft uptake and hearing gain between the 2 groups indicating that the additional step of anterior tucking in the type I tympanoplasty provides good graft support and favorable hearing outcomes but it was not a mandatory step.

The limitations of this study were the relatively low number of patients and the absence of long-term postoperative follow up of the patients.

## CONCLUSION

There is an ongoing search for new and better techniques of TIT to achieve an optimal result and minimize the failure of the surgery. In the quest for evolving the different techniques of TIT, among the various methods to combat the problematic repair of anterior quadrant perforations, anterior tucking combined with TIT could provide good graft support, giving an efficient result in hearing improvement and thus minimizing the chances of failure of the surgery. However, this step in TIT is not mandatory as it is comparable to the endoscopic type I tympanoplasty without anterior tucking regarding graft success and hearing gain.

*Funding: No funding sources*

*Conflict of interest: None declared*

*Ethical approval: The study was approved by the Institutional Ethics Committee*

## REFERENCES

1. Sinkkonen ST, Jero J, Aarnisalo AA. Tympanic membrane perforation. *Duodecim*. 2014;130(8):810-8.
2. Sarkar S. A review on the history of tympanoplasty. *Indian J Otolaryngol Head Neck Surg*. 2013;65(3):455-60.
3. Wullstein H. Theory and practice of tympanoplasty. *Laryngoscope*. 1956;66(8):1076-93.
4. Onal K, Uguz MZ, Kazikdas KC, Gursoy ST, Gokce H. A multivariate analysis of otological, surgical and patient-related factors in determining success in myringoplasty. *Clin Otolaryngol*. 2005;30(2):115-20.
5. Sharma SK, Kumar D, Singh R, Upadhyay VP, Dubey AK. Study of the etiological factors of failures of myringoplasty: a observational study. *Indian J Otolaryngol Head Neck Surg*. 2019;71(2):1562-6.
6. Darouassi Y, Aljalil A, Ennouali A, Hanine MA, Chebraoui Y, Bouaity B, et al. Prognostic factors of myringoplasty: study of a 140 cases series and review of the literature. *Pan Afr Med J*. 2019;33:323.
7. El-Guindy A. Endoscopic transcanalmyringoplasty. *J Laryngol Otol*. 1992;106(6):493-5.
8. Tarabichi M. Endoscopic middle ear surgery. *Ann Otol Rhinol Laryngol*. 1999;108(1):39-46.
9. Pap I, Tóth I, Gede N, Hegyi P, Szakács Z, Koukkoullis A, et al. Endoscopic type I tympanoplasty is as effective as microscopic type I tympanoplasty but less invasive-a meta-analysis. *Clin Otolaryngol*. 2019;44(6):942-53.
10. Jyothi AC, Shrikrishna BH, Kulkarni NH, Kumar A. Endoscopic myringoplasty versus microscopic

- myringoplasty in tubotympanic CSOM: a comparative study of 120 cases. *Indian J Otolaryngol Head Neck Surg.* 2017;69(3):357-62.
11. Harugop AS, Mudhol RS, Godhi RA. A comparative study of endoscope assisted myringoplasty and microscope assisted myringoplasty. *Indian J Otolaryngol Head Neck Surg.* 2008;60(4):298-302.
  12. Tseng CC, Lai MT, Wu CC, Yuan SP, Ding YF. Endoscopic transcanal myringoplasty for anterior perforations of the tympanic membrane. *JAMA Otolaryngol Head Neck Surg.* 2016;142(11):1088-93.
  13. Lakpathi G, Reddy LS, Anand. Comparative study of endoscope assisted myringoplasty and microscopic myringoplasty. *Indian J Otolaryngol Head Neck Surg.* 2016;68(2):185-90.
  14. Kaya I, Sezgin B, Sergin D, Ozturk A, Eraslan S, Gode S, et al. Endoscopic versus microscopic type 1 tympanoplasty in the same patients: a prospective randomized controlled trial. *Eur Arch Otorhinolaryngol.* 2017;274(9):3343-9.
  15. Mishra P, Sonkhya N, Mathur N. Prospective study of 100 cases of underlay tympanoplasty with superiorly based circumferential flap for subtotal perforations. *Indian J Otolaryngology.* 2007;59(3):225-8.
  16. Gersdorff M, Garin P, Decat M, Juantegui M. Myringoplasty: long-term results in adults and children. *Am J Otol.* 1995;16(4):532-5.
  17. Bhat NA, De R. Retrospective analysis of surgical outcome, symptom changes, and hearing improvement following myringoplasty. *J Otolaryngol.* 2000;29(4):229-32.
  18. Sharp JF, Terzis TF, Robinson J. Myringoplasty for the anterior perforation: experience with the Kerr flap. *J Laryngol Otol.* 1992;106(1):14-6.
  19. Primrose WJ, Kerr AG. The anterior marginal perforation. *Clin Otolaryngol Allied Sci.* 1986;11(3):175-6.
  20. Moras K, Lasarado S, Shivaraj R, Aramani A, Pinto G. 360 degree subannular tympanoplasty a retrospective study of 200 cases. *J Evol Med Dent Sci.* 2015;4:5455.
  21. Hay A, Blanshard J. The anterior interlay myringoplasty: outcome and hearing results in anterior and subtotal tympanic membrane perforations. *Otol Neurotol.* 2014;35(9):1569-76.
  22. Peng R, Lalwani AK. Efficacy of "hammock" tympanoplasty in the treatment of anterior perforations. *Laryngoscope.* 2013;123(5):1236-40.
  23. Schraff S, Dash N, Strasnick B. "Window shade" tympanoplasty for anterior marginal perforations. *Laryngoscope.* 2005;115(9):1655-9.
  24. Prakash MD, Abhilasha S. The role of anterior tucking of graft in subtotal perforation of tympanic membrane. *Int J Otorhinolaryngol Head Neck Surg.* 2018;4(3):759-63.
  25. Dhanapala N, Hussain SM, Reddy LS, Bandadka R. Comparative study of clinical and audiological outcome between anterior tucking and circumferential flap methods of type I tympanoplasty in large central perforation. *Indian J Otol.* 2018;24(3):190-3.
  26. Shanbag R, Arunkumar JS, Chand MS, Garag SS. Comparative study of anterior tucking and cartilage support tympanoplasty with respect to graft uptake and hearing outcome. *Int J Otorhinolaryngol Head Neck Surg.* 2019;5(1):69-76.
  27. Burse KS, Kulkarni SV, Bharadwaj CC, Shaikh S, Roy GS. Anterior tucking vs. cartilage support tympanoplasty. *Odisha J Otorhinolaryngol HNS.* 2014;8(2):18-20.
  28. Bartel R, Levorato M, Adroher M, Cardelus S, Diaz A, Lacima J, et al. Transcanal endoscopic type 1 tympanoplasty in children: cartilage butterfly and fascia temporalis graft. *Int J Pediatr Otorhinolaryngol.* 2019;121:120-2.
  29. Lade H, Choudhary SR, Vashishth A. Endoscopic vs microscopic myringoplasty; a different prospective. *Eur Arch Otorhinolaryngol* 2014;271(7):1897-902.

**Cite this article as:** Thingujam S, Poduval J. Comparative study of outcomes of type 1 tympanoplasty with and without anterior tucking. *Int J Otorhinolaryngol Head Neck Surg* 2021;7:1604-10.