

## Case Report

# Carcinosarcoma of the nasopharynx: a case report

Monica Kotu<sup>1\*</sup>, Ian Paul Olwoch<sup>2</sup>, Thabo Kgomo<sup>1</sup>

<sup>1</sup>Department of Otorhinolaryngology, Sefako Makgatho Health Sciences University, Pretoria, South Africa

<sup>2</sup>School of Medicine University of Limpopo, Polokwane, South Africa

**Received:** 10 July 2021

**Revised:** 18 August 2021

**Accepted:** 19 August 2021

**\*Correspondence:**

Dr. Monica Kotu,

E-mail: [monicak@wol.co.za](mailto:monicak@wol.co.za)

**Copyright:** © the author(s), publisher and licensee Medip Academy. This is an open-access article distributed under the terms of the Creative Commons Attribution Non-Commercial License, which permits unrestricted non-commercial use, distribution, and reproduction in any medium, provided the original work is properly cited.

### ABSTRACT

Carcinosarcoma is a malignant tumor with a dual histological appearance, a squamous epithelial (sarcomatous), and a mesenchymal component. Carcinosarcomas are characterized by a high recurrence rate, metastatic spread, and high morbidity and mortality. Carcinosarcoma can arise from any squamous epithelial lining but rare in the sino-nasal tract. We are presenting a case of a 19-year-old male with a 3-month history of recurrent epistaxis associated with nasal blockage, anosmia, and bilateral complete loss of vision over a few weeks. Carcinosarcoma of the sino-nasal tract is a rare entity and can mimic any sino-nasal malignancy. The optimal treatment of this disease is controversial and lacks a clear guideline, therefore challenging to the treating oncologists. Carcinosarcoma of the head and neck is a rare and aggressive tumor. It poses diagnostic and treatment challenges.

**Keywords:** Carcinosarcoma, Nasopharynx, Sinonasal malignancy

### INTRODUCTION

Carcinosarcoma is a malignant tumor consisting of a mixture of two cell lineage, carcinomatous and mesenchymal (a term broadly used to include cartilage, bone, fat, and hematopoietic tissues).<sup>1,2</sup> Carcinosarcoma is also referred to as a true malignant mixed tumor.<sup>2,3</sup> The early pathologist, like Rudolph Virchow has always considered that the origin of this pathology has a dual origin and thus labelled it as carcinosarcoma.<sup>1</sup> Virchow believed that the component of both sarcomatous and carcinomatous was simultaneously triggered to undergo malignant changes. The probability exists therefore that the sarcomatous tissues are invaded by the carcinomatous cell lineage that results in what is referred to as carcinosarcoma.<sup>1</sup> Carcinosarcoma of the nasopharynx and sino-nasal tract are rare, with only a few described in the literature. The perused literature shows few cases in Asia, South America, Europe, North Africa and no reported cases in Southern Africa. The disease causes diagnostic challenges. The management of this disease is

controversial as there are no set treatment guidelines. The disease is aggressive and carries a poor prognosis.<sup>4</sup>

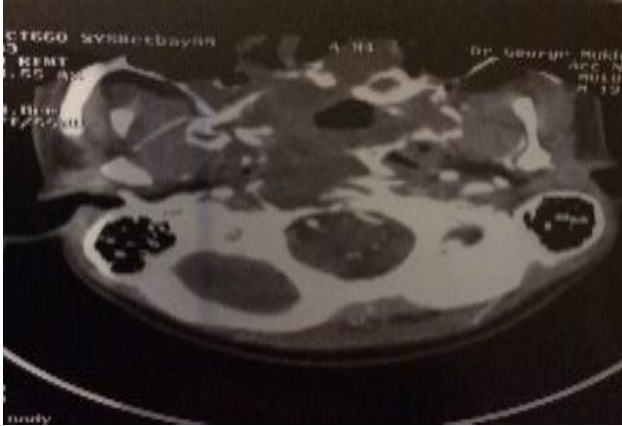### CASE REPORT

A 19-year-old male presented with a 3-month history of recurrent epistaxis associated with nasal blockage, anosmia, and bilateral complete loss of vision over a few weeks. The patient had no risk factors of smoking, alcohol consumption, exposure to radiation, or wood dust. He had no cervical lymphadenopathy and HIV serology was negative.

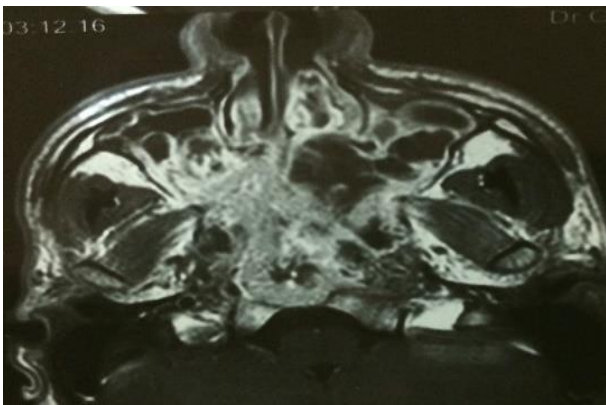
On examination, a solid mass was visualized in the right nostril.

MRI and CT scans of the brain and paranasal sinuses were done. An extensive lobulated mass involving the nasopharynx, maxillary sinuses, ethmoid sinuses, nasal passages, pterygopalatine fossae, infratemporal fossae, sphenoid sinuses, and circumferential encasement of the

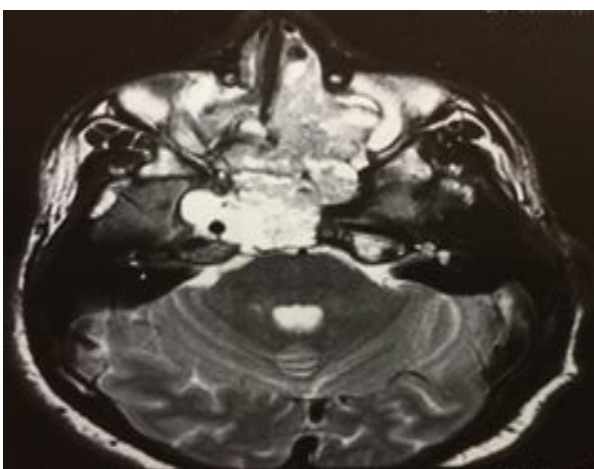
right carotid artery and extension of the mass into the cavernous sinus. Trans-nasal biopsy was done, histology revealed carcinosarcoma of the nasopharynx. The tumor was inoperable. Curative radiotherapy (77 gray) was given but appeared ineffective. The patient demised shortly thereafter.



**Figure 1: CT scan: aggressive nasopharyngeal tumour eroding the skull base.**



**Figure 2: MRI T1 with gadolinium: heterogenous enhancement.**



**Figure 3: MRI T2: heterogenous intensity mass.**

## DISCUSSION

Carcinosarcoma of the head and neck is an uncommon clinical entity that mimics common squamous cell carcinoma.<sup>2</sup> Carcinosarcoma may arise from any squamous epithelia of the body such as the gastrointestinal tract, pelvis, and aerodigestive tract.<sup>6</sup> In the head and neck, it is common in the larynx and salivary glands.<sup>4,5</sup> In the sino-nasal cavity, the maxillary sinus is the common site.<sup>8,9</sup> It is extremely rare in the nasopharynx and has aggressive behavior.<sup>2-4</sup>

The clinical presentation is often non-specific and may include nasal blockage, epistaxis, headache, and facial pain.<sup>5,8</sup> In the perused literature, the disease is dominant in elderly males.<sup>2,10</sup> The risk factors include smoking and alcohol use.<sup>4,8</sup> Our patient had no risk factors.

The treatment is controversial. Others advocate a combination of surgery and radiotherapy while the role of chemotherapy is not clear.

## CONCLUSION

Carcinosarcoma is rare and carries the worst prognosis. The disease is poorly understood as it sometimes resembles the common squamous cell carcinoma. The clinical presentation and radiological features are non-specific and can mimic other sino-nasal and nasopharyngeal tumors. Tissue biopsy is therefore imperative. The rarity of it is a challenge in terms of conducting randomized trials to assess the best treatment options and outcomes. A multicentre collaboration is needed to achieve this goal.

The epidemiology of this tumor is unknown in Southern Africa, as we could not find a single case report in the literature. The purpose of the article, therefore, is to add to the existing information about carcinosarcoma of the Nasopharynx and to identify potential risk factors in our geographic area.

*Funding: No funding sources*

*Conflict of interest: None declared*

*Ethical approval: Not required*

## REFERENCES

1. Saphir O, Vass A. Carcinosarcoma. Am J Cancer. 1938;33:331-61.
2. Singh G, Sharma D. Carcinosarcoma of head and neck; clinicopathological characteristics, treatment, and outcomes of unique neoplasm. Int J Radiat Ther. 2017;3(5):269-70.
3. Said MS. True Malignant mixed tumor (Carcinosarcoma). Medscape reference. 2015.
4. Patel TD. A case control-analysis of survival outcomes in sino-nasal carcinosarcoma. Am J Otolaryngol. 2015;36:200-04.

5. Lim AL, Zahirrudin Z. A rare case of Nasopharyngeal Carcinosarcoma. *Med J Malaysia.* 2012;67:428-9.
6. Kumar T, Kothari K. Carcinosarcoma of upper aerodigestive tract: A case study. *Indian J Surg Oncol.* 2011;2(4):316-31.
7. Dhruva JT, Mittal RS, Sharma A. Sino-nasal teratocarcinosarcoma involving nasal cavity, nasopharynx, and all paranasal sinuses with bilateral orbital and intracranial extension: A rare case report. *Asian J Neurosurg.* 2017;12:232-40.
8. De Cruz S. A rare case of invasive sino-nasal carcinosarcoma. *Int J Surg.* 2020;70:243-8.
9. Hasnaoui J. Carcinosarcoma of the maxillary sinus: A rare case report. *Annals of Med Surg.* 2017;19: 41-4.
10. Yuen J, Varadarajan V, Stavrakas M, Muquit S, Khalil H. A case of Invasive Sino-nasal Carcinosarcoma: The importance of early detection. *Case Rep Otolaryngol.* 2018;274-6.

**Cite this article as:** Kotu M, Olwoch IP, Kgomo T. Carcinosarcoma of the nasopharynx: a case report. *Int J Otorhinolaryngol Head Neck Surg* 2021;7:1531-3.