

Original Research Article

Endoscopic endonasal dacryocystorhinostomy-an experience in a tertiary care hospital

Atishkumar B. Gujrathi, Paritosh A. Kamble*, Shashin Khadkekar, Nishikant Gadpayale, Yogesh Paikrao, Harshada Kurande, Indutai Rathod

Department of Otorhinolaryngology, Dr. Shankarrao Chavan Govt. Medical College and Hospital, Nanded, Maharashtra, India

Received: 06 July 2021

Revised: 18 August 2021

Accepted: 19 August 2021

***Correspondence:**

Dr. Paritosh A. Kamble,

E-mail: darkprinceofpersiattd@gmail.com

Copyright: © the author(s), publisher and licensee Medip Academy. This is an open-access article distributed under the terms of the Creative Commons Attribution Non-Commercial License, which permits unrestricted non-commercial use, distribution, and reproduction in any medium, provided the original work is properly cited.

ABSTRACT

Background: Dacryocystorhinostomy is a surgical procedure by which the lacrimal flow is diverted into the nasal cavity by making an opening in the lacrimal sac when the nasolacrimal duct gets blocked. The operation can be carried out using either an external or endonasal surgical approach.

Methods: This is a clinical observational study done on 50 patients with chronic dacryocystitis with obstruction at the level of sac or nasolacrimal duct. This study was conducted at Dr. Shankarrao Chavan government medical college, Nanded, during the period of 2 years (2018-2020). Patients were evaluated and operated for endoscopic endonasal dacryocystorhinostomy.

Results: The mean age of studied cases was 33.92 ± 12.13 years. The M:F ratio was 0.78. Epiphora was the predominant complaint in all cases 100%. Swelling of lacrimal sac was present in 24% cases and Pain on affected side was present in 18% cases. 6% patients had fistula on the side of block. 12% patients had mucocele and 14% patients had pyocele on the affected side. Left and right side was involved in 54% and 40% cases respectively. The disease presented bilaterally in 06% cases. 80% patients had no complications after endonasal endoscopic dacryocystorhinostomy (EEDCR) surgery. Rate of surgical success was 92%.

Conclusions: Nasolacrimal duct obstruction is more common among females and in middle aged persons. EEDCR is treatment which provides patients relief from the symptoms without any scar and also preserves nasolacrimal pump system with high success rate. It may prove better surgical technique in chronic dacryocystitis.

Keywords: Dacryocystitis, Endonasal dacryocystorhinostomy, EEDCR

INTRODUCTION

The lacrimal apparatus starts from the lacrimal gland and ends at the nasolacrimal ducts. The apparatus consists of the lacrimal gland and the lacrimal pathway. The integrity of the lacrimal apparatus in its secretory function and in its drainage, mechanism is most vital for the normal functioning of the eye. Any factor which upsets the drainage mechanism distal to the sac or at the

nasolacrimal duct level can lead to the clinical condition of dacryocystitis.

The incidence of nasolacrimal duct obstruction is estimated to involve approximately 10 percent at 40 years increasing to 35-40 percentages at 90 years of age.^{1,2} Epiphora is the primary symptom. However, stasis of tears in the lacrimal sac causes recurrent infections of the sac leading to chronic dacryocystitis. The traditional treatment for chronic nasolacrimal duct obstruction has

conventionally been surgery, in the form of an external dacryocystorhinostomy performed by an ophthalmic surgeon. In EEDCR method, the lacrimal sac is approached through the nasal cavity using nasal endoscopes. The advantages of this approach are avoidance of a facial scar, maintenance of the normal lacrimal pump mechanism, avoids disruption of the medial palpebral ligament and angular vessels, and prevents trauma to the medial orbital tissues, which can occur in an external dacryocystorhinostomy operation. EEDCR has been gaining popularity, largely due to technological advances in endoscopes and other modern instruments of rhinology surgery. EEDCR is indicated when medical therapy has failed to achieve resolution of the disease. This approach avoids an external scar and neurovascular disruption along the tract exposing the lacrimal sac. In addition, there is minor traumatization, preservation of lacrimal pump function, and reduction of surgical time. The success rate of EEDCR is comparable to that of the traditional external procedure, with minimal morbidity and the possibility to treat simultaneous sino-nasal diseases.³⁻⁵ Furthermore, any concomitant nasal pathology contributing to nasolacrimal duct obstruction, such as enlarged agger nasi cells can also be corrected simultaneously. The aim of endoscopic dacryocystorhinostomy is to not only establish a free passage between lacrimal sac and nasal cavity but also to keep this passageway patent. However, it is difficult to make definite evidence-based determinations about the relative efficacy of EEDCR because of the deficiencies in the reported literature. So, this study aimed to report the experience in endonasal endoscopic dacryocystorhinostomy of the oto-rhino-laryngology, at Tertiary care hospital.

METHODS

This is a clinical observational study done on 50 patients with dacryocystitis with obstruction at the level of sac or nasolacrimal duct in the department of otorhinolaryngology of Dr. Shankarrao Chavan government medical college, Nanded between January 2019 to June 2020. Institutional ethics committee approval for the study was obtained. All patients diagnosed as acute or chronic dacryocystitis, chronic dacryocystitis due to acquired and/or congenital nasolacrimal duct obstruction and age group 5 and above were included in this study. Patients having nasolacrimal duct obstruction secondary to malignancy were excluded. Thorough history was obtained from the patients including onset and duration of epiphora, associated swelling and pain. This was followed by a thorough local examination. Inspection of eyelid was done to check any evidence of laxity of eyelid, ectropion. Eyelid margins were examined. Upper and lower puncta were examined. Nasal examination was done by anterior rhinoscopy. Regurgitation on pressure over the lacrimal sac (ROPLAS) was performed. Lacrimal sac syringing was done to check the level of block canalicular probing was done to determine level of block. Diagnostic nasal

endoscopy was performed. Computed tomography scan of paranasal sinus is performed if indicated. Confirmed diagnosis is established and patients are subjected to preoperative evaluation. All patients were induced under with sedation except children and uncooperative patients or patients undergoing bilateral surgery were induced with general anaesthesia with orotracheal intubation and EEDCR was performed. A posterior based, Inferior based or 'H' Shaped flap was taken. In some cases, silastic lacrimal tubes are passed through superior and inferior puncta visualized in nasal cavity, pulled into nasal cavity and secured together by tying the ends together on the nasal side. In some cases, a cotton pledget soaked in mitomycin-C in a concentration of 0.1 mg per ml in sterile water solution was placed in the stomal site for 5 minutes and later removed. Patient was shifted to Ward after surgery and the anterior nasal pack is removed after 12 hours. Lacrimal syringing is done to check for patency of stoma by enquiring with patient the flow of fluid in oropharynx. Lacrimal syringing is done with 2 ml injection. Dexamethasone to reduce inflammation as well as injection gentamicin to reduce chances of infection. Topical nasal decongestants applied for 3 times per day for next one week. Crusts and debris in the nasal cavity are removed after 48 hours and the patient is discharged from the hospital. The patient is instructed to report back to the operating surgeon after a week for review. Patient was followed up on day 7, 1 month and 6 months from discharge. During this review, the operated site is visualized endoscopically. Synechiae if present are broken with help of bipolar cautery. Also, lacrimal irrigation is done with sterile saline to ensure the patency of stoma. Following the above procedures, the findings were recorded in the proforma (case record form). These findings were entered in Microsoft excel 2010. Statistical analysis was carried out with the help of SPSS (version 20) for windows package (SPSS Science, Chicago, IL, USA). The results were compiled by using suitable tables and graphs wherever necessary. The variations were analysed as a percentage of the total and reported. Quantitative data is presented with the help of mean, standard deviation qualitative data is presented with frequency and percentage tables. Charts and diagrams were drawn wherever necessary.

RESULTS

The minimum age of participant was 6 years whereas maximum was 69 years. The mean age of participants was 33.92 years with standard deviation ± 12.13 . The maximum patients i.e., 34% were belonged to 28-38 age group. There were 44% male's patients and 56% were females. 100% study patients were presented with complaints of watering from eyes, followed by 18% with pain and 12% of the patients had swelling on affected side (Table 1). 64% of patients showed delayed mucoid regurgitation from opposite punctum on sac syringing whereas 36% had delayed watery regurgitation from opposite punctum on sac syringing. The 6% patients had history of fistula on the side of block, whereas 12%

patients had mucocele and 14% patients presented with pyocele on the affected side as shown in the Table 1. Left side was most commonly involved (54%) whereas right side was involved in 40% of cases. The disease presented bilaterally in 06% cases. 94% patients were given local anaesthesia with IV sedation and 6% of patients were given GA. In 66% patients, posterior flap was used followed by in 22 % H shaped flap and in 6% inferior flap was used after surgery as shown in the Table 2. Whereas silastic stents were used in 4% of patients, topical mitomycin-C was applied in 11 patients and septoplasty was done in 07 patients (Table 2). The 4% patients had intra-operative bleeding whereas 2% of the patients had post-operative bleeding 4% patients had periorbital edema due to breach of lamina papyracea whereas 4% of patients developed synechia at the stoma site and 6% of patients developed granulation tissue at stoma site as shown in the Table 3. The 80% patients had no complications after EEDCR surgery. The 94% patients showed free flow after intra-operative syringing. The 94% patients showed free flow on post-operative day 7 syringing. The 92% patients showed free flow on 1 month follow-up. The 92% patients showed free flow on 6 months follow up as shown in the Table 4. The 96% have healthy stoma on of immediate postoperative diagnostic nasal endoscopy. The 98% patients showed healthy stoma on post-operative diagnostic nasal endoscopy after 1 week and 1-month post-surgery Table 5). Rate of surgical success in this study was 92% (Table 4).

Surgical success

It can be defined as subjective resolution of all symptoms of lacrimal obstruction for a minimum period of 6 months and the patency of the stoma by lacrimal sac syringing and observing a patent stoma in the lateral wall of the nose, as visualized by nasal endoscopy.

Surgical failure

It can be defined as persistence or recurrence of symptoms during the follow-up period (minimum follow-up period being 6 months) and closure of the stoma in the lateral nasal wall during follow-up period due to any cause.

Table 1: Distribution of patients according to presentation of clinical symptoms and clinical findings (n=50).

Variables	No. of patients	Percentage (%)
Clinical symptoms		
Watering	50	100
Swelling	12	24
Pain	09	18
Clinical findings		
Fistula	03	06
Mucocele	06	12
Pyocele	07	14

Table 2: Distribution of patients according to type intervention used in surgery, (n=50).

Type of flap	No. of patients	Percentage (%)
Posterior flap	33	66
H shaped flap	11	22
Inferior based flap	06	12
Stent	02	04
Mitomycin-C	11	22
Septoplasty	07	14

Table 3: Distribution of the patients according to the type complications occurred after doing surgery, (n=50).

Complications occurred	No. of patients	Percentage (%)
Bleeding-intra-operative	02	04
Bleeding-post-operative	01	02
Periorbital edema	02	04
Orbital cellulitis	00	00
Orbital abscess	00	00
Synechia at site of stoma	02	04
Granulation at site of stoma	03	06

Table 4: Distribution of patients according to result of sac syringing, (n=50).

Result of syringing	POD-1		POD- 3		Post op-1 Month		Post op-3 months		Post op-6 months	
	N	%	N	%	N	%	N	%	N	%
Free flow	47	94	47	94	46	92	46	92	46	92
Complete block	02	04	02	04	03	06	03	06	03	06
Partially patent	01	02	01	02	01	02	01	02	01	02
Total	50	100	50	100	50	100	50	100	50	100

Table 5: Distribution of patients according to result of diagnostic nasal endoscopy, (n=50).

Diagnostic nasal endoscopy	POD-1		POD-7		Post op-1 month	
	N	%	N	%	N	%s
Epithelised stoma	48	96	49	98	49	98
Synechiae at site of stoma	01	02	01	02	00	00
Granulation at site of stoma	01	02	00	00	01	02
Total	50	100	50	100	50	100

Table 6: Relation between types of flaps, mitomycin and stent used in surgery and outcome of surgery, (n=50).

Type of procedure	Subtype	Surgical success no. of patients (%)	Surgical failure no. of patients (%)	Chi square value	P value	Interpretation
Flaps	H shaped, (n=11)	11 (100)	00	1.66, df=2	0.44 (>0.05)	There is no significant relationship between type of flap used and rate of surgical success
	Inferior flap, (n=06)	05 (83.33)	01(16.16)			
	Posterior, (n=33)	30 (90.90)	03 (9.09)			
Mitomycin applied	Yes, (n=11)	10 (90.9)	01 (9.09)	0.022, df=1	0.87 (>0.05)	There is no significant relationship between mitomycin-C applied and rate of surgical success
	No, (n=39)	36 (92.3)	03 (7.69)			
Stent used	Yes, (n=02)	02 (100)	00	0.18, df=1	0.67 (>0.05)	There is no significant relationship between stent used and rate of surgical success

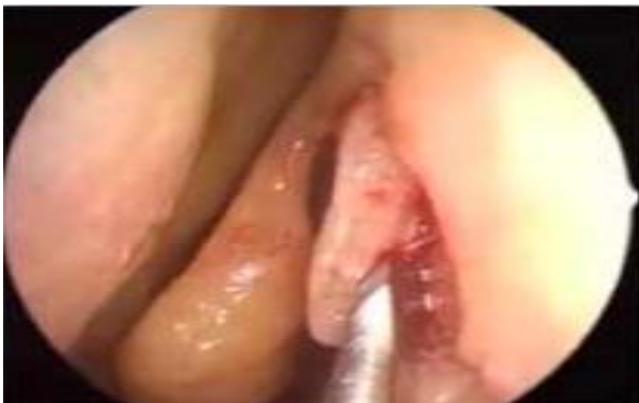

Figure 1: Taking vertical incision and mucosal flap elevation.

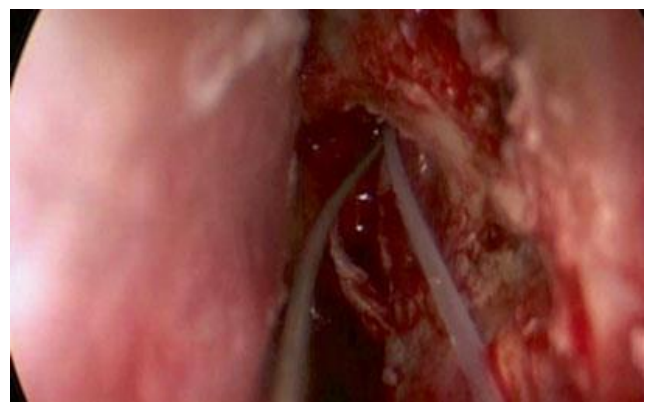


Figure 3: Endonasal view of the silastic stent insertion.

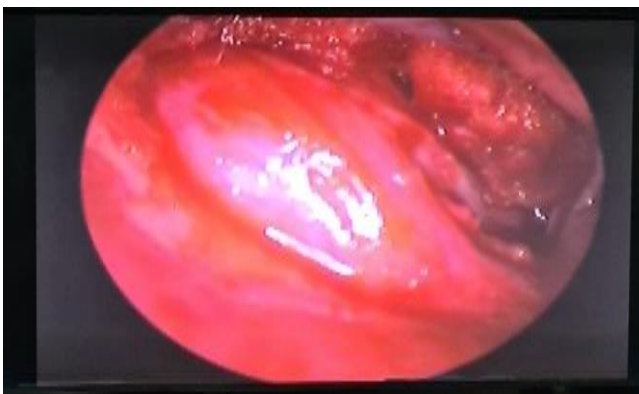

Figure 2: Tenting of lacrimal sac.

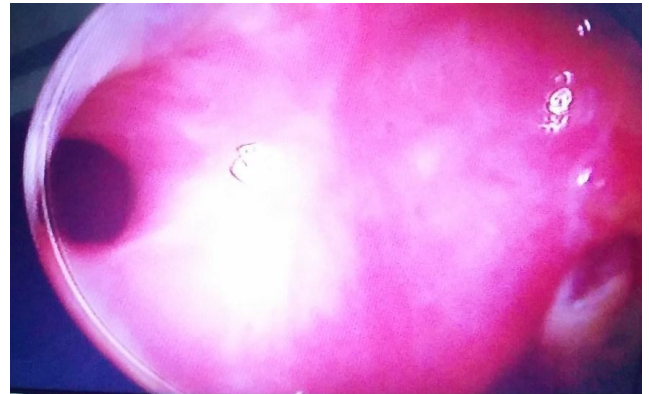


Figure 4: Patent stoma at the end of 6 months.

DISCUSSION

Dacryocystorhinostomy is a surgical procedure by which the lacrimal flow is diverted into the nasal cavity by making an opening in the lacrimal sac when the nasolacrimal duct gets blocked. The operation can be carried out using either an external or endonasal surgical approach. The aim of the study to evaluate advantages, disadvantages and complications of endoscopic dacryocystorhinostomy. The mean age of patients in present study was 33.92 ± 12.13 which is less than the study conducted by Alzarei et al and Lee et al.^{6,7} In present study the range of patient's age was 6-69 years which was near to age range of study conducted by Kulkarni i.e., 11-65 years.⁸ In our study, 44% were males and 28% were females. The percentage of female proportion is higher than male proportion in all studies. In this study, most common presenting complaint (100%) was watering from eyes similar to a study conducted by Alzarei et al and Filho et al stated that epiphora was the predominant complaint in all cases of nasolacrimal duct obstruction.^{6,9} In our study other complaints were: pain (18%) and swelling (24%). A study conducted by Alzarei et al epiphora (100%) and swelling of lacrimal sac (11%) were the presenting complaints. The 64% of patients showed delayed mucoid regurgitation from opposite punctum on sac syringing whereas 36% had delayed watery regurgitation from opposite punctum on sac syringing.⁶ Also, these patients were subjected to ROPLAS test. 90% patients had shown positive results for the test. 6% patients had history of fistula on the side of block. Whereas 12% patients had mucocele and 14% patients presented with pyocele on the affected side. 74% of the cases were newly diagnosed cases, whereas 16% of the cases were previously operated for External dacryocystorhinostomy. 10% of the cases were revision EEDCR surgeries. Similarly, 16.7% had history of nasal surgery which is much less than this present study.⁶ In our study, left side was most commonly involved (54%) whereas right side was involved in 40% of cases. The disease presented bilaterally in 6% cases. Ceylan et al conducted a study to compare lacrimal sac flap preserving techniques with or without fibrin glue in patients undergoing endoscopic endonasal dacryocystorhinostomy where 49% were diagnosed with right sided chronic DCR and 51% were diagnosed with left sided chronic DCR which is nearly same to our study.¹⁰ In present study, 94% patients had given Local anaesthesia with IV sedation and 6% had given GA for EEDCR surgical procedure whereas Priya et al conducted a study to study the EEDCR with special reference to mitomycin-C, the all patients in her study were operated with for local anaesthesia under IV sedation.¹¹ During EEDCR procedure, in 66% patients, posterior flap was used followed by in 22 % H shaped flap and in 6% inferior flap was used after surgery. It was found that there is no significant relationship between type of flap used and rate of surgical success (Table 5). In this study, mitomycin-C was applied to 22% patients whereas in study conducted by Priya et al mitomycin was applied in

51% cases to see the effect of intraoperative topical application of mitomycin-C during EEDCR surgical procedure.¹¹ Kulkarni et al conducted a study to compare the endonasal dacryocystorhinostomy with and without adjunctive topical use of mitomycin C.⁸ He found that synechiae formation was seen in 16% and granulation formation was seen in 6% which is higher than our study. It was found that there is no significant relationship between mitomycin applied and rate of surgical success (Table 6). In 4% patients' stent was used after surgery. It was found that there is no significant relationship between stent used and rate of surgical success. In our study, 94% patients showed free flow after intraoperative syringing, 4% complete block and 2% partial patent after surgery. The 92% patients showed free flow on sac syringing on 1 month follow-up. Most of the patients (92%) have healthy stoma on Post-operative Diagnostic nasal endoscopy. The 2% patients showed synechiae and 2% patients showed granulation formation after EEDCR on post-operative diagnostic nasal endoscopy. Yarmohammadi et al conducted a study to evaluate the results of a teamwork revision endoscopic dacryocystorhinostomy (DCR) in eyes with previously failed external DCR.¹² Complications encountered during endoscopic DCR were bleeding (minimal), granulations, synechiae, pain over root of nose and swelling over lower eyelid. Priya et al found that 21% patients formed synechiae after EEDCR. The overall comparison of synechiae and granulation formation after EEDCR is higher in other above compared studies than our study. In our study, most of the patients (80%) patients had no complications during or after surgery. Vaghela et al conducted a study to evaluate the results endonasal dacryocystorhinostomy in patients with dacryocystitis and found that patients operated with endoscopic endonasal DCR did not have any intraoperative or postoperative complications.¹³ Ceylan et al conducted a study in which 93% patients had no any complications after EEDCR procedure.¹⁰ In present study 4% patients had intra-operative bleeding whereas 2% of the patients had post-operative bleeding 4% patients had periorbital edema due to breach of lamina papyracea whereas 4% of patients developed synechiae at the stoma site and 6% of patients developed granulation tissue at stoma site. In this study, surgical success rate of EEDCR 92%. A similar study conducted by Alzarei et al in that study surgical success rate of EEDCR was almost equal to our present study (i.e., 90%).⁶ The overall surgery success rate of the entire study population was 86.3% in study conducted by Lee et al to learn the curve for endoscopic endonasal dacryocystorhinostomy. Priya et al conducted a study in which success rate of EEDCR at the end of 3 months was 100%.¹¹ This was maintained till 6 months with a fall to 97% at the end of 1 year.

CONCLUSION

Nasolacrimal duct obstruction is more common among females and in middle aged persons. EEDCR is treatment which provides patients relief from the symptoms without

any scar and also preserves nasolacrimal pump system with high success rate. Due to no facial scar the treatment is well accepted by patients. There are various techniques for EEDCR with high success rates. The higher surgical success rate and minimal post-operative complication along with postoperative monitoring of lacrimal sac neostoma can make EEDCR procedure an effective treatment modality for chronic dacryocystitis. It may prove better surgical technique along with a good follow up care post-operatively for chronic dacryocystitis patients.

Funding: No funding sources

Conflict of interest: None declared

Ethical approval: The study was approved by the Institutional Ethics Committee

REFERENCES

1. Fergie N, Jones NS. Dacryocystorhinostomy. In: Michael Gleeson, George G Browning, Martin J Burton, Ray Clarke et al, editors. Scott-Brown's Otorhinolaryngology, Head and Neck Surgery. 7th ed. vol 2. Great Britain: Hodder Arnold. 2008;1689-98.
2. Dalgleish R. Idiopathic acquired lacrimal drainage obstruction. *Bri J Ophthalmol.* 1967;51:463-8.
3. Wormald PJ. Powered endoscopic dacryocystorhinostomy. *Laryngoscope.* 2002;112:69-72.
4. Eloy P, Bertrand B, Martinez M, Hoebeke M, Watelet JB, Jamart J. Endonasal dacryocystorhinostomy: indications, technique and results. *Rhinology.* 1995;33:229-33.
5. Hartikainen J. Prospective randomized comparison of endonasal endoscopic dacryocystorhinostomy and external dacryocystorhinostomy. *Laryngoscope.* 1998;108:1861-6.
6. Mukhtar SA, Jamil AZ, Ali Z. Efficacy of External Dacryocystorhinostomy (DCR) with and without Mitomycin-C in Chronic Dacryocystitis. *J College Physicians Surgeons Pakistan.* 2014;24(10):732-5.
7. Alzarei AH, Ardi TE, Alshihri KA, Algarni SN, Alameri DH, Almutari T. Endoscopic dacryocystorhinostomy: The experience of a tertiary care hospital in the kingdom of Saudi Arabia. *Med J Cairo University.* 2011;79(2).
8. Lee JJ, Lee HM, Bin LH, Seo SW, Ahn HB, Lee SB. Learning Curve for Endoscopic Endonasal Dacryocystorhinostomy. *Korean J Ophthalmol.* 2017;31(4):299.
9. Kulkarni G. Comparative study of endonasal dacryocystorhinostomy with and without adjunctive topical use of mitomycin C. *J otolaryngol-ENT res.* 2017;7(2):62-5.
10. Araujo Filho BC, Voegels VL, Butugan O, Neto CD, Lessa MM. Endoscopic dacryocystorhinostomy. *Braz. J Otorhinolaryngol.* 2005;71(6):721-5.
11. Ceylan SM, Erdoğan C, Sozen T, Kanmaz MA, Disikirik I, Jafarov S et al. The Fibrin Glue Application Enhances Surgical Success Rate in Endonasal Endoscopic Dacryocystorhinostomy with Lacrimal Sac Preservation. *Ear Nose Throat J.* 2021;100(5):483S-8.
12. Priya M, Puttevar MP, Kumar SJ, Bakshi SS. Study of Endonasal Endoscopic Dacryo-cystorhinostomy with Special Reference to Mitomycin-C. *Indian J Otolaryngol Head Neck Surg.* 2019;71:1972-80.
13. Yarmohammadi ME, Ghasemi H, Jafari F, Izadi P, Nadoushan MJ, Chin NS. Teamwork endoscopic endonasal surgery in failed external dacryocystorhinostomy. *J Ophthal Vision Res.* 2016;11(3):282.
14. Vaghela M, Patel A, Patel V, Dhanani A. Evaluation of the results endonasal dacryocystorhinostomy in patients with DCR. *Int J Otorhinolaryngol Head Neck Surg.* 2017;3(2):184.

Cite this article as: Gujrathi AB, Kamble PA, Khadkekar S, Gadpayale N, Paikrao Y, Kurande H et al. Endoscopic endonasal dacryocystorhinostomy-an experience in a tertiary care hospital. *Int J Otorhinolaryngol Head Neck Surg* 2021;7:1593-8.