

## Case Report

# A child's mysterious ear

Preeti Shetti, Shivani Gupta\*, Paramita Debnath

Department of Otorhinolaryngology and Head and Neck Surgery, KLE University KAHER University, Belagavi, Karnataka, India

**Received:** 24 June 2021

**Accepted:** 19 August 2021

**\*Correspondence:**

Dr. Shivani Gupta,

E-mail: shivanigpt52@gmail.com

**Copyright:** © the author(s), publisher and licensee Medip Academy. This is an open-access article distributed under the terms of the Creative Commons Attribution Non-Commercial License, which permits unrestricted non-commercial use, distribution, and reproduction in any medium, provided the original work is properly cited.

### ABSTRACT

Foreign body in ear is an emergency encountered by an otolaryngologist and if not removed it can lead to serious complications. Most commonly foreign body in ear is lodged in external auditory canal while it's rare to find it in middle ear. We report a case of foreign body in the middle ear in a 3-year-old child who presented to us with chronic discharging ear who was then suspected to be unsafe ear and so was taken up for exploration under microscope. A pink polypoidal mass arising from middle ear mucosa was found and following its removal- to our surprise; a blackish rubbery debris filling the middle ear cavity and attic area along with embedded foreign body was extracted. We conclude that pediatric patients with chronic ear discharge not responding to antibiotics should raise a suspicion of FB in the middle ear and explored timely.

**Keywords:** Middle ear, Foreign body, Child, Cortical mastoidectomy

### INTRODUCTION

The inherent inquisitiveness of children about their surroundings and the natural body orifices makes them vulnerable to foreign bodies.<sup>1</sup> Regarding the ear, while most foreign bodies are lodged in the external auditory canal, it is rare for the middle ear to harbour any foreign object. Such situations often invite complications and pose a challenge for the clinicians.

### CASE REPORT

A-3-years-old male child complaints of foul-smelling discharge from left ear since 1 year, profuse, continuous, mucopurulent with history of deaf mutism and family history of consanguineous marriage.

On otoscopic examination, mucopurulent discharge filling the EAC which on cleaning showed a pinkish polypoidal mass occupying the left external auditory canal. Patient was on conservative management for the

past 1 year and was not relieved. So, we admitted the patient and started him on antibiotic coverage.

High-resolution computed tomography temporal bone was done which revealed soft tissue mass occupying left EAC, mastoid, middle ear, ossicles were not visualized (Figure 1).

Symptoms persisted in spite of 5 days of injectable antibiotics and so decision for exploration was taken under general anesthesia.

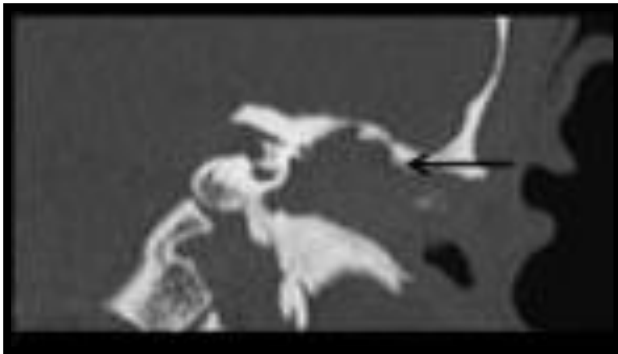On microscopy, pink fleshy polypoidal mass seen arising from the left middle ear mucosa, bleeding on touch, probable all around, attached to ME inflamed mucosa and was excised by sharp dissection along with granulation tissue (Figure 2).

To our surprise, blackish debris present in the middle ear cavity, attic and antrum along with embedded foreign body -a green rubber band which was extending into

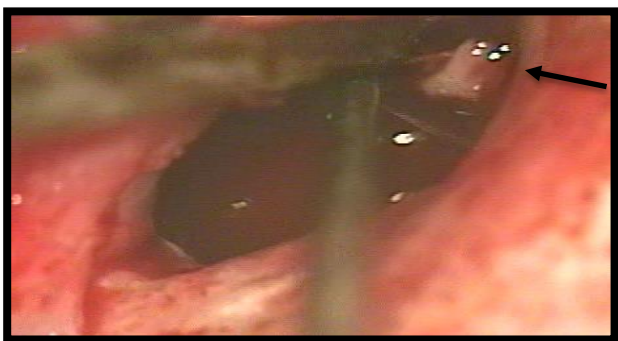
mastoid cavity was seen and removed using suction and probe (Figure 3 and 4).

Decision for cortical mastoidectomy was taken, granulation tissue was seen and removed and patency achieved in the mastoid cavity (Figure 5).

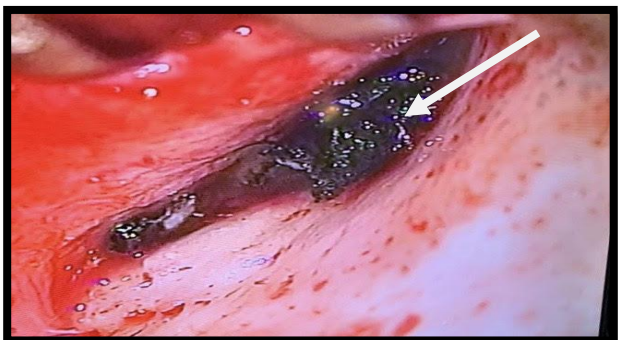
Middle ear was examined and all ossicles were eroded except for the stapes footplate. Middle ear cavity was obliterated with gel foam and postauricular suturing done in layers.



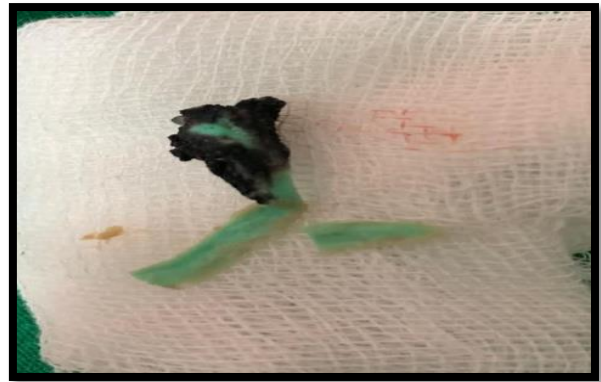
**Figure 1: HRCT temporal bone showing soft tissue mass occupying left EAC, mastoid, middle ear and ossicles not visualized.**



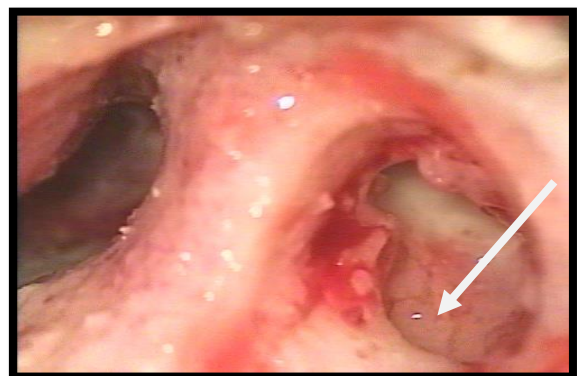
**Figure 2: On microscopy, pink fleshy polypoidal mass seen arising from the left middle ear mucosa.**



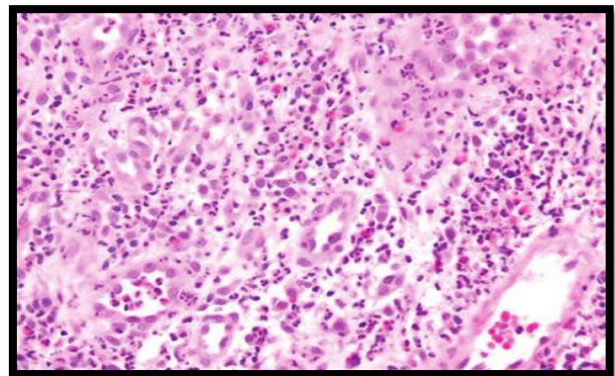
**Figure 3: Blackish debris present in the middle ear cavity, attic and antrum.**



**Figure 4: The embedded foreign body “a green rubber band”.**



**Figure 5: Granulation tissue seen on cortical mastoidectomy.**



**Figure 6: HPE of granulation tissue with mixed inflammatory infiltrate.**

We decided to postpone the tympanic membrane repair till the infection was controlled and mucosal oedema and granulations subsided.

The postoperative period was satisfactory. The child was put on adequate antibiotic coverage and his parents were counselled regarding aural hygiene and to keep away from vulnerable objects. The ear was maintained discharge-free.

Histopathology Section showed, granulation tissue with mixed inflammatory infiltrate without evidence of granulomatous lesion which was suggestive of acute on chronic inflammatory reaction (Figure 6).

## DISCUSSION

In developing countries where there is a large-scale ignorance about the medical illness, neglected FB can lead to a variety of complications. FB of otorhinolaryngology is commonly seen in children. In the ear, FB of the external auditory canal is more common. A thorough review of the recent literature suggests very few instances of foreign bodies in the middle ear, and those were mostly iatrogenic or accidental. Iatrogenic causes include inadvertent injury by hearing aid moulds, medially displaced grommets causing middle or inner ear complications, or cochlear implants acting as foreign bodies. Apart from the welding incidents, accidental entry of foreign bodies in the middle ear cleft is uncommon or appears grossly underreported.<sup>1-3</sup> Foreign bodies in the external auditory canal can be removed by forceps, probe or by syringing, occasionally under an operating microscope, and rarely by a post-aural incision. Meticulous suction clearance under an operating microscope is an ideal option instead of routine syringing procedure in the out-patients' department when dealing with an actively discharging ear or when a perforation in the tympanic membrane is suspected. Middle ear foreign bodies are also removed by common instruments via the trans canal approach. In fact, about 99.5% of aural foreign bodies in the Nigerian study were successfully removed by these conventional methods irrespective of their positions in the external or middle ear, and only 1 adult person required posterior tympanotomy. The need for exploratory tympanotomy for extraction of non-iatrogenic middle ear foreign body in children is rarely reported. There are only few instances of extraction of non-iatrogenic middle ear foreign body by tympanotomy documented in the literature.<sup>1</sup>

There are very few cases of foreign body middle ear leading to disastrous complications in the child. There was one documented case where a twig had entered the middle ear through the tympanic membrane in a 16-year-old boy, causing damage to the ossicular chain and severing the chorda, but it was successfully removed without requiring a tympanotomy.<sup>4</sup> Cases of accidental entry of metal-pieces during welding are all reported in adults.

The second documentation of removal of an impacted, non-iatrogenic middle ear foreign body i.e., stone by tympanotomy in child was reported by Dutta et al in 2013.<sup>1</sup> This study was somewhat similar to our study except that in our study there was no self-induced history of foreign body insertion nor prior history of CSOM.

In the case reported by Garag et al a foreign body i.e., plastic electrical cap embedded in granulation tissue and

polyp from the middle ear and was removed by surgical exploration with final histopathology consistent with foreign body granuloma.<sup>5</sup> This case had similar presentation like our case except for the intraoperative findings which is unique for our case.

We report case of unusual foreign body in the middle ear who presented to us with complaints of chronic ear discharge with aural polyp and blackish rubbery debris along with it. As per our knowledge, no such case of middle ear foreign body has been reported till date in the literature. There have been instances of self-induced foreign body in the middle ear being sandstone and plastic cannula, but the instance of a green rubber band been staying in the ear for a long duration while damaging the entire conduction mechanism in the ear is the first one.

## CONCLUSION

This case report highlights that Pediatric patients with chronic ear discharge not responding to antibiotics should raise a suspicion of FB in the middle ear. The etiology of an indolent, chronic discharging ear in the pediatric population should be explored with caution. Our main message via this report is to put forth the ideology wherein a simple foreign body can cause destruction of the middle ear cleft and if not treated on time can lead to dreaded complications.

*Funding: No funding sources*

*Conflict of interest: None declared*

*Ethical approval: Not required*

## REFERENCES

1. Dutta M, Ghatak S, Biswas G. Chronic Discharging Ear in A Child: Are We Missing Something? Med J Malaysia. 2013;68:368-71.
2. Eleftheriadou A, Chalastras T, Kymizakis D, Sfetsos S, Dagalakis K, Kandiloros D. Metallic Foreign Body in Middle Ear: an unusual cause of hearing loss. Head Face Med. 2007;3:23.
3. Iseh KR, Yahaya M. Ear foreign bodies: Observations on the clinical profile in Sokoto, Nigeria. Ann African Med. 2008;7(1):18-21.
4. Brian N, Jamie S, David DG. "I Can't Taste Ice Cream": An Unusual Case of Tinnitus and Dysgeusia. Pediatric Emergency Care. 2004;20(12):832-4.
5. Garag SS, Shanbag RD, Rashmi S, Arunkumar JS. Foreign body of middle ear masquerading cholesteatoma. Indian J Otol. 2015;21:64-6.
6. Katarkar A, Katarkar S, Jain A, Modh SD, Shah RP. Difficult-case of middle ear foreign body: An unusual case report with review of literature. Southeast Asian J Case Rep Rev. 2013;2:178-85.
7. Harris KC, Conley SF, Kerschner JE. Foreign Body Granuloma of the External Auditory Canal. Paediatrics. 2004;113:371

8. Mertens J, Bubmann M, Reker U. Welding spark injuries of the ear. Observations of personal case material. *Laryngorhinootologie*. 1991;70(8):405-8.

**Cite this article as:** Shetti P, Gupta S, Debnath P. A child's mysterious ear. *Int J Otorhinolaryngol Head Neck Surg* 2021;7:1555-8.