

## Case Series

# Cysticercosis of head and neck region

Nitish Baisakhiya\*, Sujata Maini, Kartikey Pandey

Department of ENT and Head and Neck Surgery, LN Medical College and JK Hospital, Bhopal, Madhya Pradesh, India

**Received:** 14 June 2021

**Accepted:** 07 August 2021

**\*Correspondence:**

Dr. Nitish Baisakhiya,

E-mail: [nitish.baisakhiya@gmail.com](mailto:nitish.baisakhiya@gmail.com)

**Copyright:** © the author(s), publisher and licensee Medip Academy. This is an open-access article distributed under the terms of the Creative Commons Attribution Non-Commercial License, which permits unrestricted non-commercial use, distribution, and reproduction in any medium, provided the original work is properly cited.

### ABSTRACT

Cysticercosis is a major public health problem especially in developing countries like ours. Disease can be prevented by increasing the public awareness about personal hygiene and sanitation. The disease commonly affects the central nervous system and the condition is referred to as neurocysticercosis. Neurocysticercosis is probably the commonest parasitic infestation of the central nervous system (CNS). Although the extracranial involvement is exceedingly rare. The head and neck regions commonly affected are tongue, sternocleidomastoid muscle, masseter muscle and strap muscles of the neck. Isolated cases of cysticercosis have been reported in the literature in head and neck region. We are reporting the case series of seven cases of extracranial cysticercosis presenting in different parts of head neck region. Two cases presented with a tongue nodule, two cases in the region of masseter muscle, one case in the pre-maxillary region and one in the sternocleidomastoid muscle in the neck. All cases were dealt with a clinical suspicion of cysticercosis as the condition is endemic in our region. The empirical treatment was started in all the cases after demonstration of cyst on ultrasonography. The cases responded to the oral albendazole combined with corticosteroid therapy. As the disease is a common entity in our country all cases presenting with firm, long standing, single swelling in the head neck region should be dealt with suspicion of cysticercosis. Early diagnosis and treatment can prevent the hazardous intracranial complications and mortality.

**Keywords:** Cysticercosis, Neurocysticercosis, Head and neck region, Ultrasonography

### INTRODUCTION

Cysticercosis is caused by larval stage of the *Taenia solium*. It has a special affinity to the neural tissue. The disease can develop in the meninges, eye and adnexa, muscles, heart, retro peritoneal and head and neck region.<sup>1</sup> The disease is transmitted by oro-fecal route by accidental consumption of eggs from contaminated water, vegetables or uncooked pork. The eggs hatch into the larva in the intestine. The larva enters the blood stream and invades the host tissues.<sup>2</sup> The condition is endemic in the region of uncontrolled pig breeding and poor sanitation. The condition is poorly reported in our country due to multiple factors like asymptomatic nature of the disease for years, lack of awareness among patients, physician and surgeon, poor socio economic condition and religious factors. We are reporting a case series cysticercosis in different parts

of the head and neck region who were diagnosed on ultrasonography (USG) and managed conservatively.

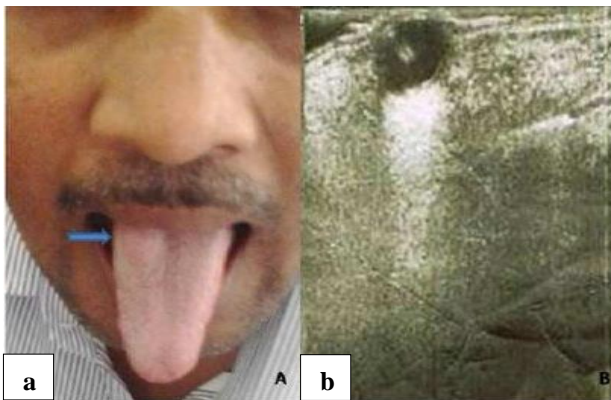
### CASE SERIES

Average age of the patients was 36 years, the youngest case was 17 years old and eldest case was 48 years of age. There were 4 males and 3 females. One out of the seven cases was a non-vegetarian by diet and the rest were vegetarian. All cases were clinically suspected of the disease and confirmed by USG. One of the cases was accidentally diagnosed on computed tomography (CT) scan of paranasal sinus. All the cases were treated by albendazole 400 mg three times a day for 21 days along with prednisolone (1 mg/kg) in tapering doses. Cases were reviewed after 21 days and reassessed clinically and radiologically. All the cases responded to the treatment

with resolution of the symptoms and disappearance of the lesion.

**Case 1**

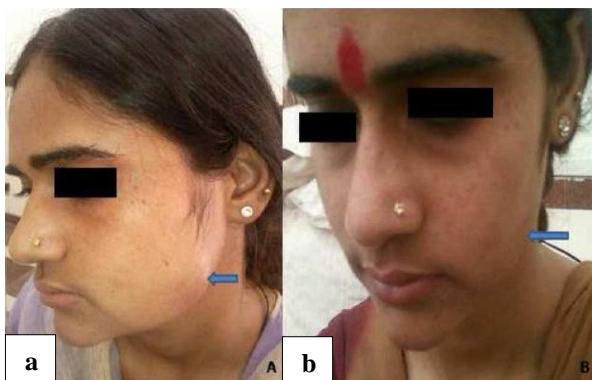
A 43 years male presented to us with a painless swelling gradually increasing in size on the dorsum of the tongue on right side since last 5 years. On gross examination there was a firm, oval, non-tender, cystic swelling sized approximately 1×1.5 cm on the dorsum of the tongue. The USG of the same showed a cyst of size 8×8.6 mm with an echogenic scolex of size 1.6 mm seen in the tongue tissue (Figure 1a and b).



**Figure 1: (a) Clinical photograph of tongue case, and (b) USG picture of the tongue patient.**

**Case 2**

A 17 years female presented with a painless swelling over left cheek for past 18 months. On gross examination, the swelling was approximately 1×1.2 cm in size, oval in shape, firm non tender and non fluctuable in nature. Sonography revealed a homogenous, hypo echoic soft tissue lesion of 2×1.4 cm in size within the masseter muscle of the left side. A well-defined echogenic area of 5×3 mm with a small calcified scolex was seen within the lesion (Figure 2 a and b).



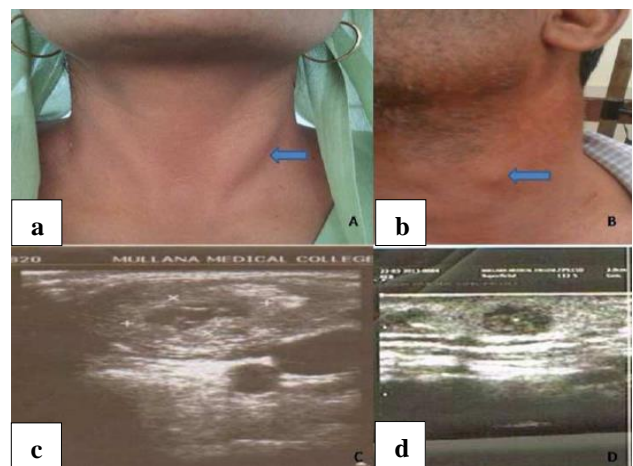
**Figure 2: (a) Clinical pretreatment photo of cysticercosis lesion on the LT cheek, and (b) clinical photo post treatment showing disappearance of the lesion.**

**Case 3**

A 36 year old male presented with a swelling on the left side of cheek since 4 months. He was treated elsewhere for the same without any improvement. On examination there was a firm cystic, non-tender swelling about 2.5×2 cm in size present on the left side of the cheek. The USG confirmed the presence of cyst with echogenic scolex in the masseter muscle.

**Case 4**

A 45 year old female patient presented to us with a painless swelling over left side of neck since 6 months. Gross examination revealed 2.5×1.5 cm sized, oval, non-tender, mobile, cystic and non fluctuable swelling in the neck. USG revealed a well-defined anechoic area of 9×8 mm with a small calcified scolex within the lesion (Figure 3a and c).



**Figure 3: (a) Clinical photo of LT SCM lesion in female patient, (b) clinical photo of LT SCM lesion in male patient, (c) and (d) USG pictures showing the lesion in the SCM and subcutaneous region.**

**Case 5**

A 48 years old male presented to us with the painless swelling over left side of neck side since 1 year. Gross examination showed a 2×1 cm firm, non-tender, cystic non fluctuable swelling on the anterior aspect of left side of the neck. USG showed calcified scolex measuring 0.5×0.6 cm in the subcutaneous tissue anterior to sternocleidomastoid muscle.

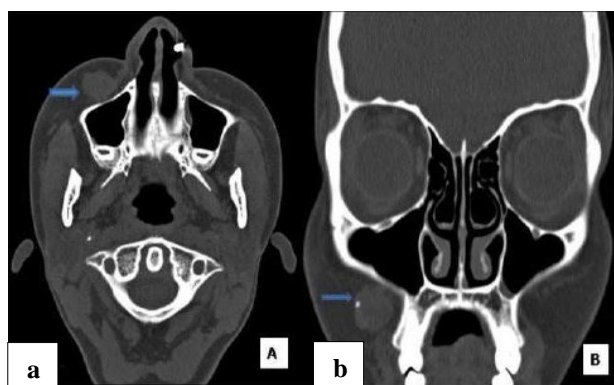
**Case 6**

A 32 year old male patient presented with a visible swelling on the right side of the neck since last 7 months. On gross examination a swelling about 2.5×3.5 cm in size firm and non-tender in nature was noted in the region of left sternocleidomastoid muscle. The swelling was mobile in horizontal direction while it showed limited mobility in vertical direction. USG confirmed the diagnosis of

cysticercosis by demonstrating a typical hypo echoic cyst with hyper echoic region within it suggestive of a scolex (Figure 3 b and d).

### Case 7

A 30 years old female presented with a history of painless swelling gradually increasing in size in the right upper alveolar region since 1 year. There was no other associated dental problem. On examination a firm, non-tender, mobile swelling was felt on right side of pre-maxillary region without involving underlying maxillary bone. CT scan showed a cystic swelling with calcification on the right pre-maxillary region without involving underlying alveolar margin (Figure 4 a and b).



**Figure 4: CT images of the lesion in the RT pre-maxillary region with calcification within.**

### DISCUSSION

Cysticercosis is caused by larval stage of the *Taenia solium* or commonly called as pork tape worm. It passes its life cycle in two hosts. Humans are the definitive host who harbours the adult worm while pigs are the intermediate host who harbour the larval stage. The eggs liberate the oncosphere in the alimentary canal of the intermediate host. The oncosphere enter the systemic circulation and get lodged in different organs and muscles of the intermediate host. The life cycle is completed when undercooked pork infested with cysticerci is consumed by human beings. However human beings can also become an intermediate host by consuming food and water contaminated with eggs of *Taenia solium*. Exogenous autoinfection can occur by ano-oral contamination in patients harboring the adult worm or endogenous autoinfection in which the eggs of the adult tapeworm living in the small intestine return to the stomach due to reverse peristalsis.<sup>2</sup>

Cysticercosis has been designated as a “biological marker” of the social and economic development of a community. Neurocysticercosis is endemic in most developing countries of Asia, Latin America, Central and South Africa. It is the single most common cause of epilepsy in the developing countries.<sup>3,4</sup> Most of the cases in the head and neck region presents with a asymptomatic (without pain or compressive symptoms) firm cystic swelling in the

area which has a thick muscle mass or rich in vascularity like tongue and masseter muscle region. Swelling becomes painful when secondarily infected. Neurocysticercosis can also present with the extra cranial cyst in disseminated cysticercosis.<sup>5</sup> Extracranial cysticercosis in the head and neck region is the rare site of occurrence in spite of large muscle mass. The condition is equally prevalent among both the genders. It commonly affects the young adults between 3<sup>rd</sup> and 4<sup>th</sup> decade of life. In our case series also the average age of patients was 36 years.<sup>1</sup>

Except one young case of 17 years of age rest were from the third and fourth decade. USG is a cost effective, sensitive, specific and non-invasive diagnostic tool to diagnose the extracranial cysticercosis. Sonography shows a well-defined, elliptical fluid filled cystic lesion with hyperechoic area within it suggestive of a scolex.<sup>6</sup> Neuroimaging modalities like CT scan and magnetic resonance imaging (MRI) have greatly improved the accuracy in the diagnosis of neurocysticercosis. The neuroradiologic findings depend on the stage of larval development, involution, location and number of cysts. On neuroimaging, four stages of cyst formation have been described. Vesicular stage of the cyst is seen on CT as hypodense cystic lesion containing a hyperintense small scolex. In the colloidal vesicular stage, larva begins to disintegrate and the host inflammatory response makes the surrounding parenchyma edematous. CT depicts this stage as ring enhancing cystic lesions with hyperintense fluid content and surrounding edema. In the granular nodular stage, cyst retracts and forms granulomatous nodule. In the final calcified stage, the granulomatous lesion is shrunken and completely calcified.<sup>7</sup> On CT the lesion appears as single or multiple calcified nodules.

The detection of a cystic space containing the cysticercus cellulose is a diagnostic feature on histopathological examination. Role of fine needle aspiration cytology (FNAC) to diagnose the condition is controversial. Different authors claimed different results. It demonstrates cellulose, hooklets and fragments of wall with inflammation.<sup>8</sup> Tissue diagnosis is not essential to start the treatment. Medical therapy in form of oral albendazole and corticosteroids show remarkable improvement.

### CONCLUSION

As the disease is a common entity in our country all cases presenting with firm, long standing, single swelling in the head neck region should be dealt with suspicion of cysticercosis. Early diagnosis and treatment can prevent the hazardous intracranial complications and mortality. Spreading awareness about the disease by mass health education, improving sanitation can play an important role in prevention of the disease.

*Funding: No funding sources*

*Conflict of interest: None declared*

*Ethical approval: Not required*

## REFERENCES

1. Babber M, Baisakhiya S, Manjhi P, Sharma N, Chopra N. Extraocular muscle Cysticercosis Masquerading Idiopathic orbital inflammatory syndrome (IOIS). *Delhi J Ophthalmol*. 2012;23(1):53-4.
2. Dalton HP, Nottebart HC. *Interpretive medical microbiology*. New York: Churchill Livingstone.1986.
3. Carpio A, Escobar A, Hauser WA Cysticercosis and epilepsy: a critical review. *Epilepsia*. 1998;39:1025-40.
4. Powell SY, Proctor AJ, Wilmore B. Cysticercosis and epilepsy in Africa: a clinical and neurological study; *Ann Trop Med Parasitol*. 1986;60:142-58.
5. Bandyopadhyay D, Sen S, Disseminated cysticercosis with huge muscle hypertrophy. *Indian J Dermatol*. 2009;54(1):49-51.
6. Scully RE, Mark EJ, McNeely WF. Case records of the Massachusetts General Hospital weekly clinicopathological exercises, case 26-1994. *N Engl J Med*. 1994;330:1887.
7. Sharda D, Chawala S, Gupta RK. Imaging and spectroscopy of neurocysticercosis; in *Taenia solium cysticercosis. From basic to clinical science*. Singh G, Prabhakar S, editors. Wallingford: CABI Publishing. 2002;311-28.
8. Kamal MM, Grover SV. Cytomorphology of subcutaneous cysticercosis, A report of 10 cases. *Acta Cytol*. 1995;39:40.

**Cite this article as:** Baisakhiya N, Maini S, Pandey K. Cysticercosis of head and neck region. *Int J Otorhinolaryngol Head Neck Surg* 2021;7:1912-5.