

## Case Report

# Nonrecurrent laryngeal nerve-an anatomical deviation

E. Siva Kumar, C. A. Swapna\*, Lavanya Karanam

Department of ENT, Sri Narayani Hospital and Research Centre, Sripuram, Vellore Tamil Nadu, India

**Received:** 13 June 2021

**Revised:** 08 August 2021

**Accepted:** 10 August 2021

**\*Correspondence:**

Dr. C. A. Swapna,

E-mail: [swapnaiju@gmail.com](mailto:swapnaiju@gmail.com)

**Copyright:** © the author(s), publisher and licensee Medip Academy. This is an open-access article distributed under the terms of the Creative Commons Attribution Non-Commercial License, which permits unrestricted non-commercial use, distribution, and reproduction in any medium, provided the original work is properly cited.

### ABSTRACT

Thyroidectomy is one of the most dispute and discussed surgery. Identification of recurrent laryngeal nerve is the most important step in this surgery. Among postop complications of thyroidectomy, the commoner is haematoma, transient hypocalcaemia and hoarseness. We report a rare case of nonrecurrent laryngeal nerve in a 25-year-old male with swelling in the right thyroid lobe. A 25-year-old male presented to the ENT OPD with complaints of swelling in thyroid region for 6 months with no other symptoms. On examination there was a 2×3 cm size nodule in the right lobe of thyroid. Rest of ORL examination was normal. On ultrasonogram there was an enlarged right lobe of thyroid with a nodular goitre. Fine needle aspiration cytology showed colloid goitre. Patient was planned for right hemithyroidectomy. Right side type 1 nonrecurrent laryngeal nerve was identified at the level of superior pole of thyroid branching from vagus and entering the larynx at the level of cricothyroid joint was identified intraoperatively. In conclusion, nonrecurrent laryngeal nerve though a very rare anomaly forms a crucial anatomical structure in thyroid surgery and is prone to injury. It is one of the preventable complications during thyroid surgery leading to postop vocal cord palsy. An in-depth anatomical knowledge and diligent surgical technique will help in identification and preservation of nonrecurrent laryngeal nerve.

**Keywords:** Nonrecurrent laryngeal nerve, An anatomical variant, Thyroid surgery

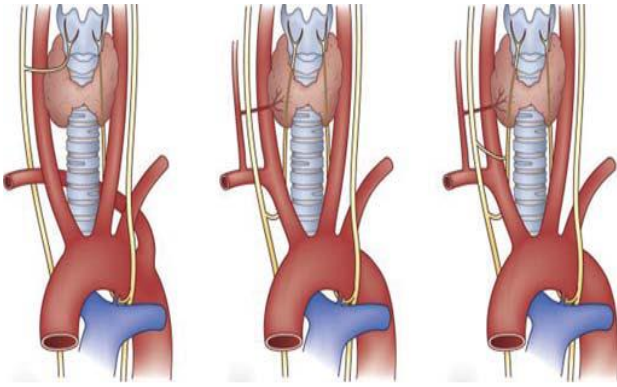
### INTRODUCTION

Thyroidectomy is one of the most dispute and discussed surgery. Identification of recurrent laryngeal nerve is the most important step in this surgery. Among postop complications of thyroidectomy, the commoner is haematoma, transient hypocalcemia and hoarseness.

Recurrent laryngeal nerve is a branch of vagus nerve, it loops around subclavian artery on the right and arch of aorta on the left side before entering larynx behind cricothyroid joint. It supplies all muscles of larynx except cricothyroid. Unilateral recurrent laryngeal nerve injury leads to voice change and bilateral causes stridor.

Recurrent laryngeal nerve injury is the most common reason of litigation after thyroid surgery in west.<sup>1</sup> Hence it should be thoroughly identified and preserved. Rarely it can have a nonrecurrent course where it arises from vagus and without forming a loop enters larynx behind cricothyroid joint as non-recurrent laryngeal nerve. Occasionally both are present and join to form a common distal nerve as shown in the Figure 1 A to C.<sup>2</sup>

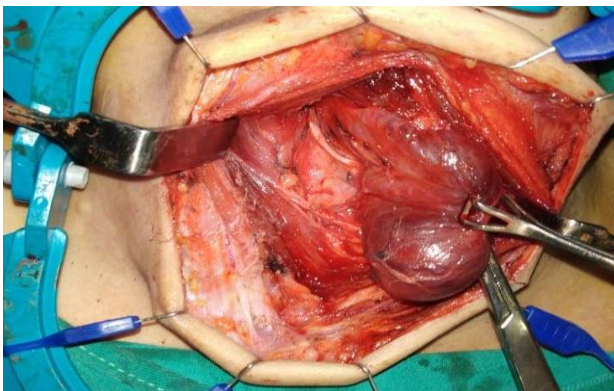
Incidence of this rare anatomical variant is around 0.3%-0.8% on the right side and 0.004% on the left side.<sup>3</sup> Due to its variability in course, thickness, branching pattern and associated anomalies it forms a very important aspect for all head and neck surgeons.



**Figures 1 (A-C): Anomalous variations in the course of the right recurrent laryngeal nerve. (A) The nonrecurrent laryngeal nerve arises from the vagus and courses medially into the larynx in the setting of an aberrant origin of the right subclavian artery, (B) the normal course of the recurrent laryngeal nerve arises from the vagus after it passes beneath the subclavian artery and (C) the unusual coexistence of the nonrecurrent and the recurrent laryngeal nerve join to form a common distal nerve.**

### CASE REPORT

A 25-year-old male presented to the ENT OPD with complaints of swelling in thyroid region since 6 months. There were no symptoms of compression over adjacent structures. On examination there was a 2×3 cm size nodule in the right lobe of thyroid. Rest of ORL examination was normal. On ultrasonogram there was an enlarged right lobe of thyroid with a nodular goitre. Fine needle aspiration cytology showed colloid goitre. All laboratory investigations were within normal limits with a euthyroid profile.



**Figure 2: Intraoperative picture of type 1 right nonrecurrent laryngeal nerve arising from vagus.**

Provisional diagnosis of right sided solitary nodular goitre was made. Patient was planned for right Hemithyroidectomy. Under general anaesthesia, Kochers incision placed and the right lobe of thyroid identified and middle thyroid vein ligated. Right side nonrecurrent laryngeal nerve was identified at the level of superior

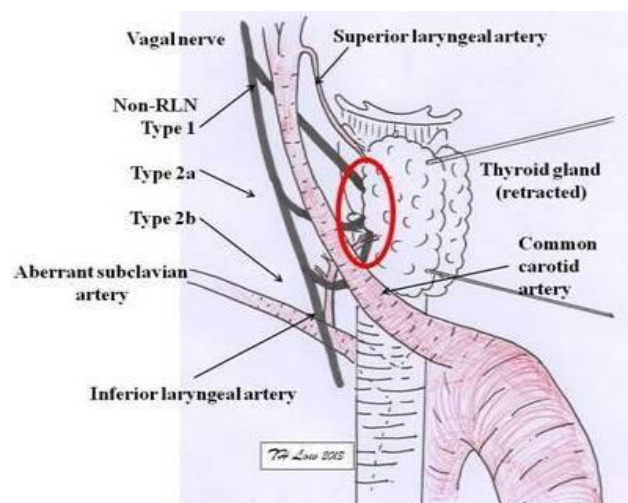
pole of thyroid branching from vagus and entering the larynx at the level of cricothyroid joint. Parathyroid glands were preserved. Postop period was uneventful.

Histopathological examination showed follicular variant of papillary thyroid carcinoma- invasive. Maximum tumour dimension is 2.5 cm. Extrathyroidal extension and lymph vascular invasion was not present (pT2Nx). Patient was planned for a completion thyroidectomy after 10 days. On completion thyroidectomy the remnant thyroid gland was removed after preserving parathyroids and left recurrent laryngeal nerve identified to have a normal course. Postop voice of patient was normal. There were no complications like hypocalcaemia and repeat IDL was normal. Histopathological examination showed no lesion in the left lobe. Patient was further given radioactive iodine therapy.

### DISCUSSION

In 1823, nonrecurrent laryngeal nerve was first described by Steadman in a cadaver study.<sup>4</sup> Recurrent laryngeal nerve is the nerve of sixth branchial arch associated with sixth arch arteries. The dorsal branches of fifth and sixth arch arteries disappear and recurrent laryngeal nerve navigates along fourth arch arteries. The fourth arch arteries on the right form right subclavian artery and on the left form aortic arch. Hence recurrent laryngeal nerve loops around these arteries.<sup>5</sup> This explains association of right nonrecurrent laryngeal nerve with anomaly of right subclavian artery.

In 1932, the association of this anomaly with aberrant subclavian artery was reported.<sup>6</sup> In 80% of the cases, the right sub-clavian artery travels behind the oesophagus, 15% between the oesophagus and trachea, and in 5% of the cases it courses in front of the trachea. This is called arteria lusoria.<sup>7</sup> Left Nonrecurrent laryngeal nerve is rare and is associated with aortic arch anomalies like situs inversus.<sup>2</sup>



**Figure 3: Types of nonrecurrent laryngeal nerve.<sup>9</sup>**

According to Toniato's assessment from 31 cases of NRLN (2004), there are 2 types of NRLN, with respect to their origin.<sup>8</sup> Type 1 indicates that the NRLN is closely related to the superior thyroid vessels. Type 2 is further divided into sub-types A and B. Type 2a shows that NRLN is parallel and over the trunk of the inferior thyroid artery, meanwhile in type 2b, the NRLN runs parallel to but under or between the branches of the inferior thyroid artery.

In our case it is type 1 right nonrecurrent laryngeal nerve. After originating from vagus it was found to enter the larynx behind the cricothyroid joint. There was no coexisting recurrent laryngeal nerve. Hence it mandates in the absence of recurrent laryngeal nerve in tracheoesophageal groove in its usual course, a nonrecurrent laryngeal nerve should be searched for and preserved.

Another possibility is rarely a branch of sympathetic trunk as a part of the sympathetic-recurrent laryngeal anastomotic branches mimics nonrecurrent laryngeal nerve.<sup>10</sup> Many preoperative investigations such as ultrasonogram, CT or MRI can be used to visualise the arteria lusoria, thereby can predict the occurrence of nonrecurrent laryngeal nerve.<sup>11</sup> Due to the rare incidence, such extensive imaging is not warranted.

## CONCLUSION

In conclusion, non-recurrent laryngeal nerve though a very rare anomaly forms a crucial anatomical structure in thyroid surgery and is prone to injury. It is one of the preventable complications during thyroid surgery leading to postop vocal cord palsy. Hence head and neck surgeons should be aware of nonrecurrent laryngeal nerve incidence, course and associated anomalies and variations.

To provide cost effective treatment and due its very less incidence expensive preoperative imaging for its identification is avoided. An in-depth anatomical knowledge and diligent surgical technique will help in identification and preservation of nonrecurrent laryngeal nerve.

## ACKNOWLEDGEMENTS

Author would like to thanks Prof. Dr. Balaji Nandagopal, director and trustee of Sri Narayani hospital and research centre for giving us access to use the necessary clinical data for manuscript preparation.

*Funding: No funding sources*

*Conflict of interest: None declared*

*Ethical approval: Not required*

## REFERENCES

1. Dralle H, Lorenz K, Machens A. Verdicts on malpractice claims after thyroid surgery: emerging trends and future directions. *Head Neck.* 2012;34(11):1591-6.
2. Townsend CM, Beauchamp DR, Evers MB, Mattox KL. Sabiston textbook of surgery: The biological basis of modern surgical practice (19th ed). Philadelphia, PA: Elsevier 2012;886.
3. Uludag M, Isgor A, Yetkin G, Citgez B. Anatomic variations of thenon-recurrent inferior laryngeal nerve. *BMJ Case Rep.* 2009.
4. Stedman GW. A singular description of some of the nerves and the arteries of the neck and the top of the thorax. *Edin Med Surg J.* 1823;19:564-65.
5. O'Neill JP, Fenton JE. The recurrent laryngeal nerve in thyroid surgery. *Surgeon.* 2008;6:373-77.
6. Pemberton J, Beaver MG. Anomaly of the right recurrent laryngeal nerve. *Surg Gynecol Obstet.* 1932;54:594-95.
7. Brandon MH, Silvia S, Matthew Graves J. The non-recurrent laryngeal nerve: a meta-analysis and clinical considerations. *Peer J.* 2017;5:e3012.
8. Toniato A, Mazzarotto R, Piotto A, Bernante P, Pagetta C, Pelizzo MR. Identification of the non-recurrent laryngeal nerve during thyroid surgery: 20-year experience. *World J Surg.* 2004;28:659-61.
9. Casal D, Pecas A, Sousa D, Rosa-Santos J. A non-recurrent inferior laryngeal nerve in a man undergoing thyroidectomy: a case report. *J Med Case Rep.* 2010;4:386.
10. Raffaelli M, Iacobone M, Henry JF. The false non-recurrent inferior laryngeal nerve. *Surgery.* 2000;128:1082-7.
11. Schneider J, Baier R, Dinges C. Retroesophageal right subclavian artery (lusoria) as origin of traumatic aortic rupture. *Eur J Cardiothorac Surg.* 2007;32:385-7.

**Cite this article as:** Kumar ES, Swapna CA, Karanam L. Nonrecurrent laryngeal nerve-an anatomical deviation. *Int J Otorhinolaryngol Head Neck Surg* 2021;7:1562-4.