

Case Series

Experiences with management of foreign body airway presenting as dire emergency

Aishwarya Ullal^{1*}, Arun P. Ajith²

¹Department of ENT, St. Marys Hospital, Thoduphuza, Kerala, India

²Department of Radiodiagnosis, Kottayam Medical College, Kerala, India

Received: 04 June 2021

Accepted: 16 July 2021

*Correspondence:

Aishwarya Ullal,

E-mail: casiopia1789@gmail.com

Copyright: © the author(s), publisher and licensee Medip Academy. This is an open-access article distributed under the terms of the Creative Commons Attribution Non-Commercial License, which permits unrestricted non-commercial use, distribution, and reproduction in any medium, provided the original work is properly cited.

ABSTRACT

Aspiration of foreign bodies by children is a common problem around the world. Foreign body aspiration is a common cause of morbidity and mortality in children, especially between ages 18 months to 3 years. Laryngeal foreign bodies pose as a dire emergency lead to choking and accidental deaths. This is a case series of five cases of laryngeal foreign bodies presenting as a dire emergency to our casualty. Detailed history and examination was done. Radiological investigations were done. Rigid bronchoscopy was performed and the foreign body was extracted restoring the airway, preventing the accidental death of the patient. Foreign bodies of the airway are the most common causes of preventable deaths among children. Quick detailed history, examination and radiological investigations are required to come to the diagnosis and prompt management. This case series throws light on how to manage laryngeal foreign bodies.

Keywords: Emergency, Foreign body, Aspiration

INTRODUCTION

Sudden onset of respiratory distress due to Foreign body aspiration in the larynx is one of the leading causes of accidental deaths in 1-3 years of age. 70 percent of choking deaths- by organic food particles.¹ Infants and children decompensate more quickly compared to adults. Unaided child with a fully obstructed airway will die in 4-6 minutes. Failure to manage airway is leading cause of deaths. This case series we try to throw light on management of difficult cases of laryngeal foreign bodies, hence try to prevent accidental deaths due to choking.

METHODS

This was a case series of five unusual cases of laryngeal foreign bodies, that presented to emergency department with acute respiratory distress and dysphonia. After taking detailed history and clinical examination, these patients were subjected to radiological studies such as chest X-rays, X-ray soft tissue lateral view and virtual

bronchoscopy and CT chest. Initial management of severe respiratory distress was done, patient was admitted in paediatric ICU, oxygen inhalation and high dose steroids were given to the patient, after taking informed consent rigid bronchoscopy was performed and foreign body extracted.

CASE SERIES

Case 1

1-year male child presented to the emergency department in the odd morning hours with aphonia and severe respiratory distress, oxygen saturation was 80%, intercostal in drawing and inspiratory stridor with reduced air entry bilaterally, X-ray chest- normal. Urgent therapeutic and diagnostic bronchoscopy after induction of general anesthesia was done succinyl choline was given for muscle relaxation. Foreign body pericarp of ground nut was extracted from the sub-glottis. Post-op laryngeal edema dealt by medical tracheostomy. In this high dose

steroids dexamethasone was given every fifteen minutes for the first hour, every half an hour for the next two hours, and every hour for the next four hours.

Case 2

A 2 months/female presented with sudden onset respiratory distress and excessive crying and whistling sound, while crying for last 5 h. Retrograde history revealed that her elder brother had pushed FB plastic whistle into his throat. Examination showed severe respiratory distress, inspiratory stridor, intercostal space in drawing, flaring of nasal ala and tachypnoea. Saturation without oxygen was 84%. On auscultation added sounds were present with reduced air entry in both lung fields. An urgent X-ray soft tissue neck lateral view showed irregular radio-opaque shadows at the level of sub-glottis. Patient was oxygenated and urgent bronchoscopy (Karl Storz chevalier Jackson rigid and ventilating bronchoscope) was done under general anaesthesia (ketamine, propofol and scoline each in dose of 1 mg/kg) which revealed a plastic whistle in the sub-glottis. FB was removed with crocodile action serrated bronchoscopy forceps. Check bronchoscopy was done to remove secretions from airway. Post-operatively nebulisation salbutamol, asthalin and adrenalin, steroid and antibiotics given.

Case 3

This is another interesting case of a FB Gokhru seed (commonly known as babool seed) in the larynx. A 6 years old child presented with progressively increasing stridor, cough and respiratory distress for last 6 days, there was definite history of FB aspiration of gokhru seed while playing. Examination revealed, hoarseness of voice, inspiratory stridor. Oxygen saturation was 92%. X-ray soft tissue neck, showed soft tissue shadow at the level of the glottis. This case was rare in that it is the foreign body was thorny in nature and had lodged vertically, preventing absolute dyspnoea and respiratory arrest. Placing the bronchoscope in larynx and using crocodile action grasping forceps, thorny part of the seed was disengaged from the mucosa of the vocal cord and then removed, vocal cords were oedematous and congested. Post-operative high dose of intravenous and inhalational steroids were given to prevent laryngospasm. Gokhru is readily available in jungle which sticks to field worker's clothes; thus, reaches household and within reach of children.

Case 4

A 6 years male had a history of accidental aspiration of foreign body fish bone one week back, presented with noisy breathing, hoarseness. Examination showed severe respiratory distress, inspiratory stridor, intercostal space indrawing, flaring of nasal ala and tachypnoea. Patient was referred from a primary health care centre. Saturation without oxygen was 84%. On auscultation added sounds were present with reduced air entry in both lung fields. An urgent X-ray soft tissue neck lateral view showed irregular

radio-opaque shadows at the level of the glottis leading to the dilatation of the larynx. Virtual bronchoscopy (VB) showed a long hyperdense FB narrowing the glottis. Patient was oxygenated and urgent bronchoscopy (Karl Storz 3.5 mm chevalier Jackson rigid and ventilating bronchoscope) was done under general anaesthesia (ketamine, propofol and scoline each in dose of 1 mg/kg) which revealed a metallic FB between vocal cords. FB (fish bone) was removed with crocodile action serrated bronchoscopy forceps. Post-operative period was uneventful

Case 5

A 4 years male child presented with non-resolving cough and breathlessness since, two months. No history of foreign body aspiration was present. Patient developed a sudden bout of cough and developed cyanosis, respiratory distress. Urgent emergency tracheostomy was done to secure the airway. Rigid bronchoscopy showed a large irregular betel nut impacted in the sub-glottis, which had jumped from the bronchus, due to irregular shape and size causing sudden respiratory arrest. In this case tracheostomy was used as a method of securing the airway and then rigid bronchoscopy was done to remove the impacted foreign body. If there is a suspicion of betel nut as the aspirated foreign body it has to be removed as soon as possible

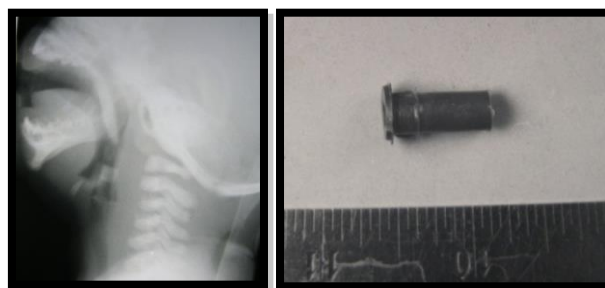


Figure 1: X-ray soft tissue neck lateral view showing radio-opaque shadow at the level of sub-glottis. Rigid bronchoscopy done and foreign body plastic whistle extracted.

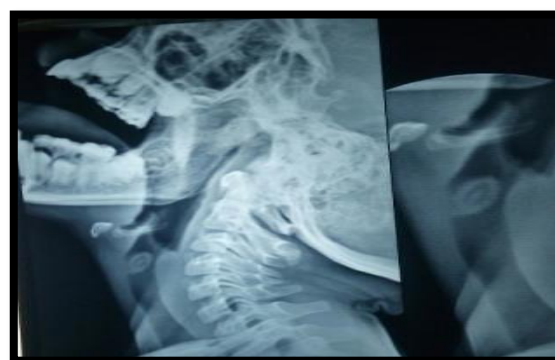

Figure 2: X-ray soft tissue neck lateral view showing radio-opaque shadow at the level of glottis.

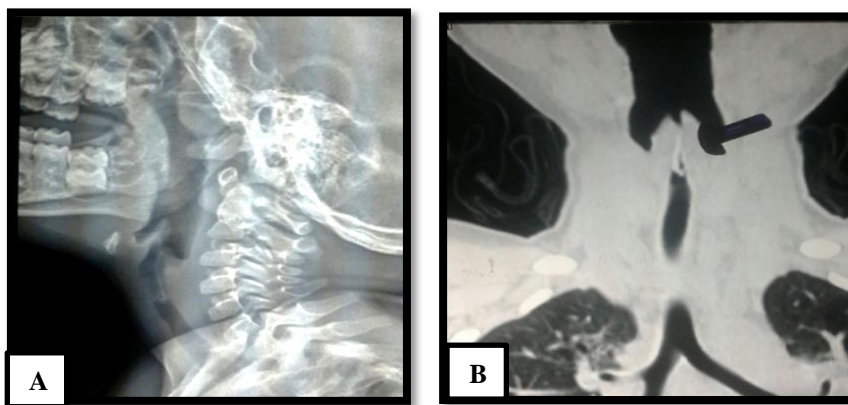


Figure 3: (A) X-ray soft tissue neck showing radiopaque shadow at the level of the glottis; (B) virtual bronchoscopy showing hyper dense foreign body at the level of glottis.

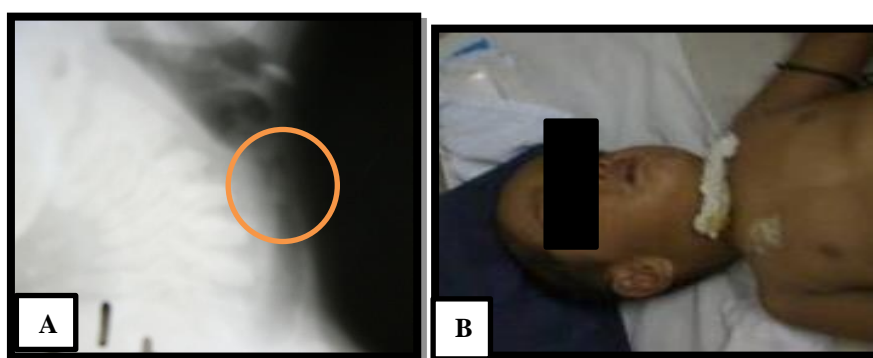


Figure 4: (A) X-ray soft tissue neck showing dilatation of the larynx suggestive of a foreign body; and (B) Patient was tracheostomized.

DISCUSSION

Laryngeal foreign bodies require urgent attention as in children sub-glottis, which is the narrowest part is prone for obstruction. According to Hagen-Poiseuille's law, the change in air flow resulting from a reduction in airway diameter is directly proportional to the airway radius elevated to the fourth power i.e.; if the radius of the lumen reduces by half airway resistance increases four fold times leading to acute respiratory arrest.³ A detailed history, knowledge of the signs of choking is a must to prevent accidental deaths of infants. An acute choking episode can have various outcomes depending on the degree of obstruction. either it can be expectorated out or swallowed, partial obstruction, can have persisting symptoms such as recurrent pneumonia and also symptom free periods.⁴ Complete obstruction leads to laryngospasm, respiratory arrest and death. Signs of choking are aphonia, stridor, respiratory distress and cyanosis.⁴ Patient must be subjected to X-ray soft tissue neck, as in our case series we found that all the five patients had dilatation of larynx as a radiological finding, aiding in the diagnosis of foreign body larynx. If patient is in a stable condition a CT chest with Virtual bronchoscopy can also be performed as it is highly sensitivity, helps to determine the site, size and

shape of FB and bronchoscopy can be avoided in case of negative VB.⁵

First aid can be given by Heimlich Maneuverer, but it can prove to be dangerous conversion of partial to complete obstruction.⁶ Definitive management is emergency bronchoscopy for diagnosis and extraction, and in case of impaction of the foreign body a tracheostomy is performed to secure the airway.

Adequate pre-oxygenation is required. Relaxant anesthesia is better than spontaneous or inhalation agents, as it prevents dislodgement at the glottis, provides better exposure of the glottis.⁷ Technique of bronchoscopic removal is visualization of larynx with Macintosh laryngoscope, inspection, extraction and check bronchoscopy. While extracting the foreign body from the glottis precaution must be taken as it is the commonest site for dislodgement.⁸ A useful maneuverer to prevent dislodgement is to Lift proximal bronchoscope upward so that forceps with FB at its tip passes through posterior part of glottis which is wider and spacious post-operative period monitoring of the patient is crucial as post-operative laryngospasm can lead to sudden respiratory arrest. Medical tracheostomy is a useful treatment, which is giving high dose steroids to reduce the laryngeal edema.⁹

As it is said prevention is always better than cure, parents care givers must be educated about the hazards of choking, the signs, symptoms and first aid so that prompt management can lead to prevention of accidental deaths due to aspiration.

CONCLUSION

Foreign bodies of the airway are the most common causes of preventable deaths among children. Quick detailed history, examination and radiological investigations are required to come to the diagnosis and prompt management. This case series throws light on how to manage laryngeal foreign bodies.

Funding: No funding sources

Conflict of interest: None declared

Ethical approval: Not required

REFERENCES

1. Fidkowski CW, Zheng H, Firth PG. The anesthetic considerations of tracheobronchial foreign bodies in children: a literature review of 12,979 cases. *Anesth Analg.* 2010;111(4):1016-25.
2. Mundra RK, Agrawal R, Sinha R. Unusual Foreign Body Aspiration in Infants Below 6 months of Age. *Indian J Otolaryngol Head Neck Surg.* 2014;66(2):145-8.
3. University of Rochester Medical Center. Anatomy of the Respiratory System, 2021. Available at:

<https://www.urmc.rochester.edu/encyclopedia/content.aspx?contenttypeid=85&contentid>. Accessed on 23 May 2021.

4. Wheeler DS, Spaeth JP, Mehta R, Suriyanarayana P, Cox PN. Assessment and Management of the Pediatric Airway. *Resuscitation and Stabilization of the Critically Ill Child.* Springer: London; 2008.
5. Behera G, Tripathy N, Maru YK, Mundra RK, Gupta Y, Lodha M. Role of virtual bronchoscopy in children with a vegetable foreign body in the tracheobronchial tree. *J Laryngol Otol.* 2014;128(12):1078-83.
6. Hayes NM, Chidekel A. Pediatric choking. *Del Med J.* 2004;76(9):335-40.
7. Boussuges S, Maitrerobert P, Bost M. Use of the Heimlich Maneuver on children in the Rhône-Alpes area. *Arch Fr Pediatr.* 1985;42(8):733-6.
8. Kendigelen P. The anaesthetic consideration of tracheobronchial foreign body aspiration in children. *J Thorac Dis.* 2016;8(12):3803-7.
9. Jackson C, Jackson CL. Foreign bodies in air & food passages. *Bronchoesophagology.* Philadelphia: Saunders; 1945: 738-48.

Cite this article as: Ullal IA, Ajith AP. Experiences with management of foreign body airway presenting as dire emergency. *Int J Otorhinolaryngol Head Neck Surg* 2021;7:1509-12.