

Case Report

A rare lesion of the wanderer's nerve with an unusual postoperative complication: vagal nerve schwannoma

Jagnnatha B., Pandu Dasappa, Suhasini Hanumaiah, Arunima Sheeja*

Kempegowda Institute of Medical Sciences Hospital and Research Centre, Bengaluru, Karnataka, India

Received: 31 May 2021

Accepted: 15 July 2021

*Correspondence:

Dr. Arunima Sheeja,

E-mail: drarunima2793@gmail.com

Copyright: © the author(s), publisher and licensee Medip Academy. This is an open-access article distributed under the terms of the Creative Commons Attribution Non-Commercial License, which permits unrestricted non-commercial use, distribution, and reproduction in any medium, provided the original work is properly cited.

ABSTRACT

Vagal nerve schwannomas are rare parapharyngeal tumours which was first described by Figi in 1933. Hoarseness is the most common symptom. Occasionally, a paroxysmal cough may be produced on palpating the mass. This is a clinical sign, unique to vagal schwannoma. Presence of this sign, along with a mass located on the medial border of the sternocleidomastoid muscle, should make clinicians suspicious of vagal nerve sheath tumours. However, in our case, the patient presented to us with a swelling in the neck and no other symptoms. MRI in the pre-operative work-up is helpful in defining diagnosis and in evaluating the extent and the relationship. A careful intracapsular enucleation with nerve-sparing technique remains the treatment of choice in order to avoid nerve injury which can lead to vocal cord paralysis. Horner's syndrome following cervical surgeries is a rare phenomenon. Its occurrence following excision of a vagal schwannoma can occur due to direct injury to cervical sympathetic chain during excision or indirect injury due to traction on the sympathetic chain. Here is a case report of a patient diagnosed with left vagal schwannoma who developed horner's syndrome post operatively.

Keywords: Vagal nerve schwannoma, Cervical sympathetic chain, Horner's syndrome

INTRODUCTION

In the year 1935, Stout introduced the term schwannoma, which identifies a benign tumour with sporadic malignant degeneration arising from cranial, peripheral and autonomic nerve sheath cells.¹ It may arise from any nerve which is lined with schwann cell sheath, which includes the cranial nerves (except for optic and olfactory), the spinal nerves, and autonomic nervous system.² Schwannomas constitute 25–45% of tumors of the head and neck. About 4% of head and neck schwannomas present as a sinonasal schwannoma.³⁻⁵ Cervical vagal schwannomas constitute about 2–5% of neurogenic tumors.¹ According to other reports these tumors affect mainly adults between the third and sixth decades of life, with no gender preponderance.^{6,7} Usually benign, Schwannomas are asymptomatic tumors with minimal risk

of malignant transformation, slow growth with an increase ratio of 2.5 to 3 mm per year, tending to be diagnosed late as large, encapsulated and with poorly mobile solid masses. Despite radiological characteristics well described, the diagnosis can only be made affirmatively only after complete resection of the tumour and its histopathological evaluation.⁴ Postoperative complications are few and among them Horner's syndrome seldom occurs. Here is a case report of a patient diagnosed with left vagal schwannoma who developed horner's syndrome post operatively.⁷

CASE REPORT

A 15 year old male presented to the ENT OPD with a swelling in upper cervical region on the right side, which was present since last 6 months gradually increasing in the

size. Patient did not complaint of hoarseness of voice or difficulty in swallowing. On examination a solitary, firm ovoid swelling in the left carotid triangle of size 3×3 cm was found which was mobile only in the vertical plane. (Figure 1)



Figure 1: Solitary swelling in the left upper aspect of the neck.

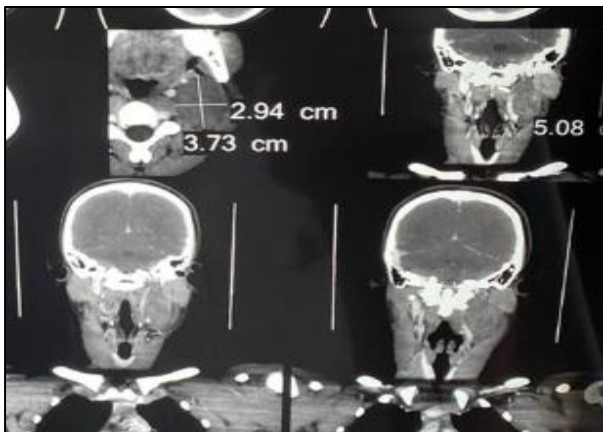


Figure 2: MDCT showing a solid soft tissue density mass with patchy post contrast enhancement measuring 5×4×3 cm in left upper cervical region, displacing the internal jugular vein anterolaterally.

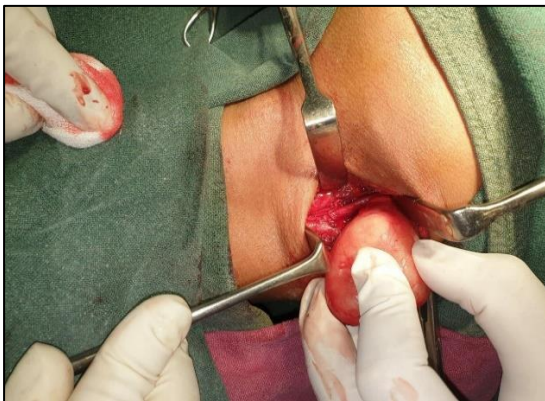


Figure 3: Well encapsulated tumour dissected out from left vagal nerve sheath.

USG of the swelling showed a 2.8×4.3×3.0 cm oval shaped hypoechoic lesion in the left upper jugular lesion indicating a possibility of vagal schwannoma.

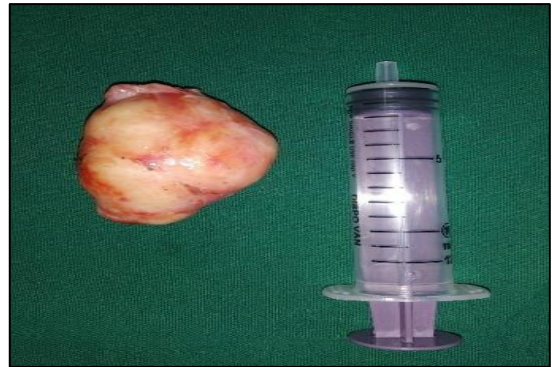

Figure 4: 4×3 cm ovoid shaped mass excised in toto with intact capsule.

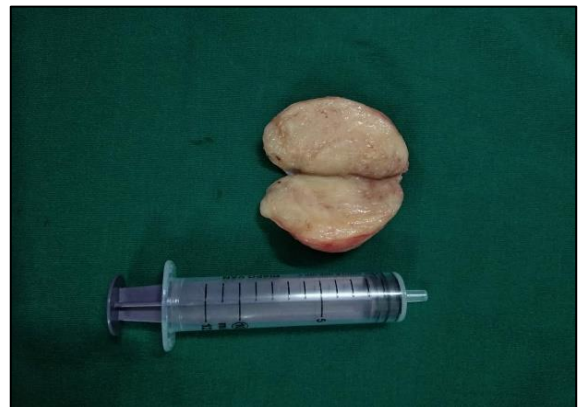

Figure 5: Cut section of the mass showing typical whorled pattern.

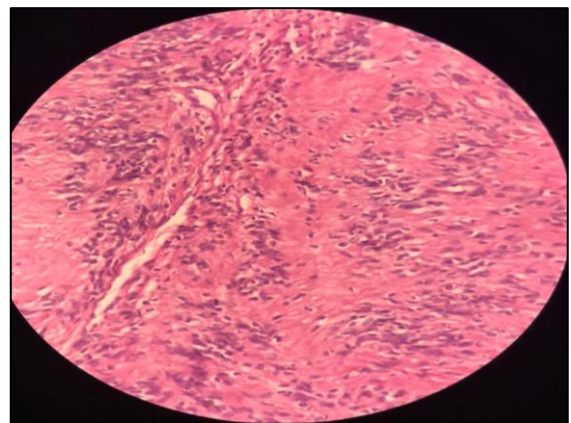


Figure 6: Histopathology showing a well encapsulated benign neoplasm with spindle shaped cells in fascicles arranged in palisading pattern forming verocay bodies suggestive of vagal nerve schwannoma.

Further FNAC demonstrated myxoid stromal substance with spindle cells having wavy nucleus with a palisading pattern. MDCT demonstrated a solid soft tissue density

mass showing patchy post contrast enhancement measuring 5×4×3 cm in left upper cervical region, displacing the internal jugular vein anterolaterally (Figure 2). It was thus most likely a vagal nerve schwannoma.

Patient was posted for excision of the mass. A vertical incision was placed over the mass and dissection was carried out in layers. A well encapsulated tumour on the vagus nerve was found which was displacing the internal jugular vein laterally. The tumour was delivered in toto from the neural sheath, without causing any damage to the nerve underneath and sent for HPE (Figure 3-5).

Histopathology revealed a well encapsulated benign neoplasm with spindle shaped cells in fascicles arranged in palisading pattern forming Verocay bodies suggestive of vagal nerve schwannoma. Post operatively patient developed Horner's syndrome which resolved subsequently (Figure 6).

DISCUSSION

Vagal nerve schwannomas are rare parapharyngeal tumours which was first described by Figi in 1933.^{9,10} Making a diagnosis of schwannoma pre operatively is difficult, given the several differential diagnoses for tumour of the neck that may be considered, including paraganglioma, branchial cleft cyst, malignant lymphoma, cervical lymphadenopathy also most vagal schwannomas seldom present with neurological deficits.¹¹

Hoarseness is the most common symptom. Occasionally, a paroxysmal cough may be produced on palpating the mass.⁷ This is a clinical sign, unique to vagal schwannoma. Presence of this sign, along with a mass located on the medial border of the sternocleidomastoid muscle, should make clinicians suspicious of vagal nerve sheath tumours. However, in our case, as mentioned the patient presented to us with a swelling in the neck and no other symptoms.

FNAC is routinely not recommended. On the other hand MRI in the pre-operative work-up is helpful in defining diagnosis and in evaluating the extent and the relationship of the tumour with the jugular vein and the carotid artery. A cervical vagal neurinoma frequently appears as a well-circumscribed mass lying between the internal jugular vein and the carotid artery.¹² Furukawa et al reported that MRI findings are useful in providing a pre-operative estimation of the nerve of origin of the schwannomas. Pre-operatively schwannoma of the vagus nerve can be differentiated from the schwannoma of the cervical sympathetic chain based on the observation that vagal schwannomas displace the internal jugular vein laterally and the carotid artery medially, whereas schwannomas from the cervical sympathetic chain displace both the carotid artery and jugular vein without separating them.¹³ In our case, the criteria of Furukawa et al. were present.

A careful intracapsular enucleation with nerve-sparing technique remains the treatment of choice in order to avoid nerve injury which can lead to vocal cord paralysis.¹⁴

Horner's syndrome following cervical surgeries is a rare phenomenon. Its occurrence following excision of a vagal schwannoma can occur due to direct injury to cervical sympathetic chain during excision or indirect injury due to traction on the sympathetic chain. A possibility of carotid sheath injury can be considered which could have led to the injury of sympathetic chain. In most circumstances they recover spontaneously over time, as in our case.

CONCLUSION

A schwannoma though rare should be considered as a differential diagnosis of a unilateral slow growing mass in the head and neck region particularly in an adult. Diagnosis relies on clinical suspicion, and confirmation is often obtained by means of surgical pathology. Thorough preoperative counselling of patients to inform them of the potential occurrence of neurological deficit is important. Long-term surveillance is not recommended. Recurrence is rare.

Funding: No funding sources

Conflict of interest: None declared

Ethical approval: Not required

REFERENCES

1. Biswas D, Marnane CN, Mal R, Baldwin D. Extracranial head and neck schwannomas - a 10-year review. *Auris Nasus Larynx.* 2007;34:353-9.
2. Chang SC, Schi YM. Neurilemmoma of the vagus nerve: A case report and brief literature review. *Laryngoscope.* 1984;94:946-9.
3. Sreevatsa MR, Srinivasarao RV. Three cases of vagal nerve schwannoma and review of literature. *Indian J Otolaryngol Head Neck Surg.* 2011;63(4):310-2.
4. Ramdass AA, Yao M, Natarajan S. A Rare Case of Vagus Nerve Schwannoma Presenting as a Neck Mass. *Am J Case Rep.* 2017;18:908-11.
5. Vijendra SS, Rao RA, Prasad V, Niprupama M. A giant vagal schwannoma with unusual extension from skull base to the mediastinum. *J Can Res Ther.* 2015;11:970-3
6. Langner E, Del Negro A, Akashi HK, Akashi HK, Costa Araújo PP, Tincani AJ, et al. Schwannomas in the head and neck: retrospective analysis of 21 patients and review of the literature. *Sao Paulo Med J.* 2007;125:220-2.
7. Lahoti BK, Kaushal M, Garge S, Aggarwal G. Extra vestibular schwannoma: a two year experience. *Indian J Otolaryngol Head Neck Surg.* 2011;63:305-9.
8. Gibber MJ, Zevallos JP, Urken ML. Enucleation of vagal nerve schwannoma using intraoperative nerve monitoring. *Laryngoscope.* 2012;122:790-2.

9. Noh SH, Zhang HY. Hoarseness after Section of a Cervical Vagus Nerve Schwannoma. *The nerve.* 2017; 3(1):18-20.
10. Figi FA. Solitary neurofibroma of the pharynx. *Arch Otolaryngol.* 1933;17:386-9.
11. Colreavy MP, Lacy PD, Hughes J, Bouchier-Hayes D, Brennan P, O'Dwyer AJ, et al. Head and neck schwannomas – a 10-year review. *J Laryngol Otol.* 2000;114:119-24.
12. Saito DM, Glastonbury CM, El-Sayed I, Eisele DW. Parapharyngeal space schwannomas. Preoperative imaging determination of the nerve of origin. *Arch Otolaryngol Head Neck Surg.* 2007;133:662-7.
13. Furukawa M, Furukawa MK, Katoh K, Tsukuda M. Differentiation between schwannoma of the vagus nerve and schwannoma of the cervical sympathetic chain by imaging diagnosis. *Laryngoscope.* 1996;106:1548-52.
14. Murley RS. A case of neurinoma of the vagus nerve in the neck. *Br J Surg.* 1948;36:101-3.
15. Gonzalez-Aguado R, Morales-Angulo C, Obeso-Aguera S, Longarela-Herrero Y, Garcia-Zornoza R, Acle Cervera L, et al. Horner's syndrome after neck surgery. *Acta Otorrinolaringol Esp.* 2012;63:299-302.

Cite this article as: Jagnnatha B, Dasappa P, Hanumaiah S, Sheeja A. A rare lesion of the wanderer's nerve with an unusual postoperative complication: vagal nerve schwannoma. *Int J Otorhinolaryngol Head Neck Surg* 2021;7:1369-72.