

## Case Report

# Rare presentation of *Aspergillus* as cystic swelling in pre-maxillary region

Ishita\*, Yadav Vishav, Sharma Kumar Dinesh, Bhagat Sanjeev

Department of Otorhinolaryngology and Head Neck Surgery, Government Medical College and Hospital, Patiala, Punjab, India

**Received:** 24 May 2021

**Revised:** 19 July 2021

**Accepted:** 20 July 2021

### \*Correspondence:

Dr. Ishita,

E-mail: [attri.isha44@gmail.com](mailto:attri.isha44@gmail.com)

**Copyright:** © the author(s), publisher and licensee Medip Academy. This is an open-access article distributed under the terms of the Creative Commons Attribution Non-Commercial License, which permits unrestricted non-commercial use, distribution, and reproduction in any medium, provided the original work is properly cited.

### ABSTRACT

Subcutaneous fungal infections are caused by penetration of the causative fungi into the subcutaneous layer and usually present as single, localised non-tender nodular swelling. The diagnostic process is a vital dynamic process that requires effective communication and efficient collaboration. *Aspergillus* hyphae invade host tissues through release of various toxins like proteases, phospholipases, hemolysins, gliotoxin, aflatoxin, phthioic acid and other toxins. Under general anesthesia and proper aseptic conditions using Moure incision surgical debulking of the pre-maxillary mass was done and post-operatively oral antifungal medication was started. Multiple cystic swelling was sent for histopathological examination and found to be non-invasive *Aspergillus* fungal infection. Subcutaneous form of aspergillosis manifest as subcutaneous fungal infection. We presented an unusual case report of 45 years old immunocompetent female with cystic presentation of aspergillosis involving premaxillary region.

**Keywords:** Cystic swelling, Pre-maxillary mass, *Aspergillus*

### INTRODUCTION

*Aspergillus* is a ubiquitous fungus and belongs to the ascomycete molds, which together with penicillium form the family of Aspergillaceae. They are commonly found in humid areas, damp soil or agricultural environment, on grain, cereal, moldy flour, and organic decaying or decomposing matter. *Aspergillus* grows by budding or branching. The branching hyphae are 2-5 µm in diameter, split dichotomously at 45° angle, and are best recognized by methanamine silver stain.<sup>1</sup>

Subcutaneous aspergillosis may be primary, usually involving the sites of skin injury over the extremities or secondary following extension from contiguous sites or through the blood stream.<sup>2</sup> The purpose of this paper was to report a rare presentation of subcutaneous aspergillus infection presenting as multiple cystic swelling in premaxillary region, its clinical presentation, radiographic

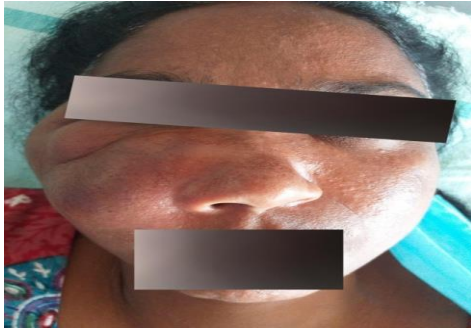
investigations, review of literature, and to emphasize the need for high index of suspicion in its histopathological diagnosis.

### CASE REPORT

A 45 years old housewife female resident of Sangrur presented to ENT OPD, Government hospital Patiala with chief complaints of pain right side of face for last one year and swelling right-side cheek for last three months. Swelling was insidious in onset, gradually progressive, started as almond size and progressed to size of lemon. No history of fever, any pus or discharge from swelling. No history of any trauma, excessive anterior or posterior nasal discharge, headache or diplopia.

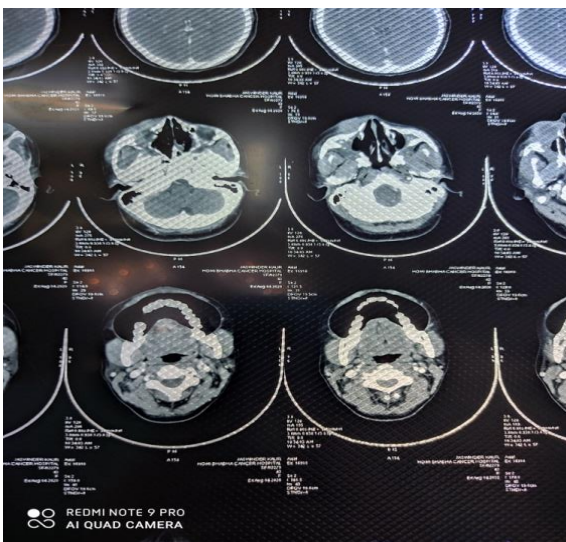
On local examination of swelling, it was found to be diffuse irregular swelling on right side of face extending superiorly at the level of lower eyelid, inferiorly at the

level of upper lip, laterally two finger breadth in front of tragus, medially upto dorsum of nose (Figure 1).



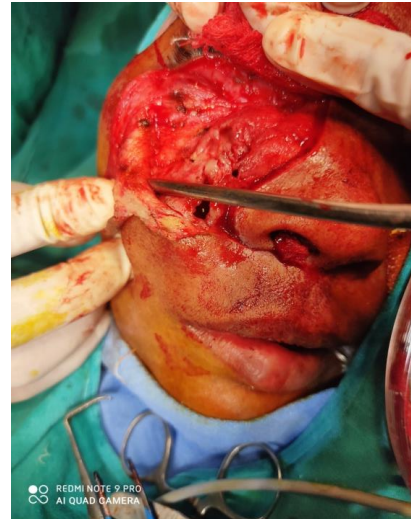**Figure 1: A diffuse irregular premaxillary region swelling.**

Swelling was firm, non-tender with smooth surface and non-fluctuant. Eye examination was normal. On diagnostic nasal endoscopy bilateral posterior choane and middle meatus was found to be clear. Fine needle aspiration of swelling was done which showed non-specific finding i.e.; either acute suppurative or inflammatory pathology. Aspiration from swelling for gram staining, Ziehl Neelsen staining and Cartridge based nucleic acid amplification test was negative. Punch biopsy showed unremarkable sinus mucosa with no evidence of malignancy. Contrast enhanced computed tomography of paranasal sinus and neck region showed heterogenous enhancing lesion seen right side of face extending superiorly from medial canthus of eye to right maxillary region, abutting right buccal mucosa without intraconal extension. Erosion of anterior and lateral wall of right maxillary sinus with intrasinus extension was seen (Figure 2). Debulking of right premaxillary mass was done under general anesthesia using Moure incision with sacrifice of cheek skin. Defect was reconstructed using median forehead flap.

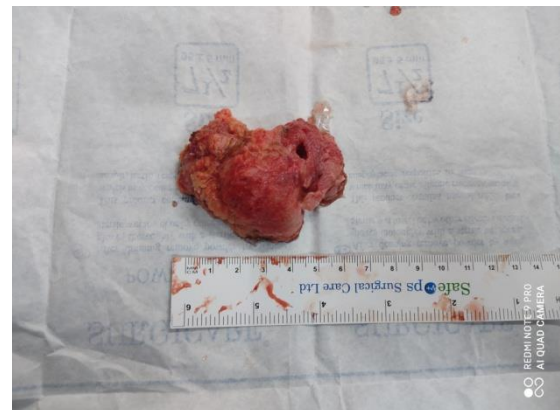

**Figure 2: Contrast enhanced computed tomography of paranasal sinus showing heterogenous enhancing lesion seen right side of face.**

Intra-operatively premaxillary mass with multiple cystic cavities extending into infratemporal region and infraorbital area was identified eroding anterior wall of maxilla (Figure 3). Tissue specimen (Figure 4) was sent for histopathological examination which showed non-invasive subcutaneous aspergillosis infection. Patient was followed up on regular basis was started on oral itraconazole 200 mg twice a day after routine blood investigations.



**Figure 3: Intra-operatively multiple cystic cavities seen involving infratemporal and infraorbital area.**



**Figure 4: Tissue specimen sent for histopathological examination.**

## DISCUSSION

Fungal infections of the nose and paranasal sinuses can be categorized into invasive and non-invasive forms. The clinical presentation and course of the disease is primarily determined by the immune status of the host and can range from harmless to life threatening complications.<sup>3</sup>

Aspergillosis is the commonest fungal infection of the nose and paranasal sinuses. Of these, *Aspergillus fumigatus* (90%) is the most common fungal pathogen followed by *Aspergillus niger* and *Aspergillus flavus*.<sup>4</sup>

Aspergillosis developing in tissues of resistance or in an antrum such as the nasal sinuses will ideally be ball-shaped (fungus ball) or necrotic material that is green-black and of a cheesy consistency or oral aspergillosis lesions, which are yellow or black in color.<sup>5,6</sup>

Subcutaneous aspergillosis is a relatively less frequent encountered than pulmonary aspergillosis and commonly present as solid soft tissue swelling. Healthy hosts can develop this infection by traumatic inoculation of fungal spores.<sup>7,8</sup>

Literature reports very few cases of cystic presentation of aspergillosis in maxillofacial region. Treatment of such infections relies on antifungal therapy (itraconazole/voriconazole) along with adequate surgical excision. Hence, the case highlights the need for thorough and careful diagnostic and microscopic examination of the swelling as these benign swellings mimic malignant lesions too. Cytological diagnosis is a well-established method for differentiation of infective from neoplastic lesions and it is a rapid, sensitive and an important tool for the diagnosis of mycotic infections. Culture studies, however, are required for identification of the causative fungi.<sup>9</sup>

## CONCLUSION

Early history, diagnosis and therapeutic intervention is the key to successful treatment of fungal infections. The diagnosis of aspergillosis depends mainly on the clinical circumstances of the infection, the anatomic site, radiological and the microscopic findings. However, from a practical standpoint treatment may need to be initiated immediately to prevent further complications. Surgical debridement of the involved tissue along with the antifungal drugs can help in achieving good prognosis.

## ACKNOWLEDGEMENTS

Authors would like to thanks Dr. Panshul Attri for valuable support during study.

*Funding: No funding sources*

*Conflict of interest: None declared*

*Ethical approval: Not required*

## REFERENCES

1. Sharma OP, Chwogule R. Many faces of pulmonary aspergillosis. *Eur Respir J.* 1998;12(3):705-15.
2. Burik JA, Colven R, Spach DH. Cutaneous aspergillosis. *J Clin Microbiol.* 1998;36(11):3115-21.
3. Higuera J, Mullins CB, Duran L, Sandoval H, Akle N, Figueroa R. Sinonasal Fungal Infections and Complications: A Pictorial Review. *J Clin Imaging Sci.* 2016;6:23.
4. Karthikeyan P, Nirmal CV. Incidence and presentation of fungal sinusitis in patient diagnosed with chronic rhinosinusitis. *Indian J Otolaryngol Head Neck Surg.* 2010;62(4):381-5.
5. Kwon J, Park KH, Park SI, Jin SY. Aspergillosis of the paranasal sinuses--diagnostic significance of the computed tomography. *Yonsei Med J.* 1989;30(3):294-7.
6. Samaranayake LP, Keung Leung W, Jin L. Oral mucosal fungal infections. *Periodontol* 2000. 2009;49:39-59.
7. Madhavan M, Aurora AL, Gupta KR, Sibal RN. Subcutaneous facial aspergillosis. *J Postgrad Med.* 1977;23(3):140-2.
8. Rabbani MZ, Amir M, Khan MY, Khan AS, Ali Z. Primary aspergillosis of the cheek. A diagnostic dilemma. *J Pak Med Assoc.* 2007;57(12):613-5.
9. Duraipandian J, Rengasamy G, Madasamy B, Kulanthavelu A, Subramanian G. Subcutaneous aspergillosis with coexisting atypical mycobacterial infection. *Indian J Pathol Microbiol.* 2010;53(2):359-60.

**Cite this article as:** Ishita, Vishav Y, Dinesh SK, Sanjeev B. Rare presentation of Aspergillus as cystic swelling in pre-maxillary region. *Int J Otorhinolaryngol Head Neck Surg* 2021;7:1548-50.