

Case Report

Neonate with congenital absence of the nose: case report

Adriana Nieto-Sanjuanero¹, Arturo García-Ramírez¹, María Martínez-Cobos¹,
Edmundo Martínez-Garza¹, Manuel de la O-Cavazos¹, Ramón Quintanilla-Loredo^{2*},
Claudia Rodríguez-Garza², Marco Méndez-Sáenz³

¹Department of Pediatrics, ²Radiology and Imaging Department, ³Department of Otorhinolaryngology, Facultad de Medicina, Universidad Autónoma de Nuevo León-Hospital Universitario, Monterrey, Nuevo León, México

Received: 21 May 2021

Accepted: 14 July 2021

***Correspondence:**

Ramón Quintanilla-Loredo,

E-mail: quintanillaloredo@yahoo.com

Copyright: © the author(s), publisher and licensee Medip Academy. This is an open-access article distributed under the terms of the Creative Commons Attribution Non-Commercial License, which permits unrestricted non-commercial use, distribution, and reproduction in any medium, provided the original work is properly cited.

ABSTRACT

The congenital absence of the nose is called arrhinia and according to the Losee et al classification, it is type I. Total arrhinia is considered if it is associated with the absence of the olfactory system (olfactory tracts and bulbs). In Mexico, there is only one reported case of arrhinia. In this case report, we presented a neonate with a congenital absence of the nose. The absence of olfactory tracts and bulbs was verified with imaging and pathological studies, classifying it as total congenital arrhinia. This case was the first of its type in our country. Since it was a rare condition, there was little bibliography on its management, therefore, coordination between the different specialties is important for proper management.

Keywords: Arrhinia, Neonate, Malformation, Intubation, Case report

INTRODUCTION

The development of the nose begins between the third and fourth week of gestation and ends between the eighth and tenth week. Of the five facial primordia, the frontonasal prominence is the structure responsible for nasal development.¹ Congenital malformations of the nose were classified in 2004 into four groups: type I hypoplasia/atrophy, type II hyperplasia/duplication, type III atypical clefts and type IV neoplasms and vascular anomalies. The congenital absence of the nose is called arrhinia and is considered type I in the Losee classification.² Total arrhinia is considered if it is associated with the absence of the olfactory system (olfactory tracts and bulbs).² It is an extremely rare congenital anomaly, with fewer than 50 cases reported worldwide to date.³ Because of this pathology's rarity, there is no consensus on the diagnostic or therapeutic approach.^{4,6} The etiology of this condition is unknown. Bosma syndrome (BAMS) (OMIM 603457) is a

pathology that associates arrhinia, microphthalmia and hypogonadotropic hypogonadism and in most cases, a mutation is observed in the SMCHD1 gene on chromosome 18p11.32.^{7,8} Other postulated associations are maternal diabetes mellitus and chromosome abnormalities.⁹⁻¹¹ Only one case of arrhinia has been reported in Mexico, our case was the second and the first isolated total arrhinia.¹²

CASE REPORT

The child was a male newborn of a 21 year old mother. He was a single neonate of 32.2 weeks of gestation (WG) by the date of last menstruation (LMP) of a second pregnancy after an abortion. The mother had a urinary tract infection in the first trimester and a vaginal infection in the third trimester. She attended five prenatal consultations, in which malformations were not found on ultrasounds.

The mother had an out of hospital vaginal delivery in an ambulance attended by paramedics. Initial steps were taken and the child started crying with an unknown Apgar score. The baby was evaluated on admission to the pediatric emergency department. He was found to be active, reactive and with mild respiratory distress at the expense of mild and inconstant moaning and subcostal retraction. Dysmorphic facies were observed on physical examination including nasal agenesis, with a respiratory rate of 59 bpm, a heart rate of 128 bpm and oxygen saturation of 93%. The newborn presented ventilatory failure and endotracheal intubation was performed with a 3.5 mm tube. He was then admitted to the neonatal intensive care unit (NICU) for assessment and management. Anthropometric measurements were a weight of 1,690 grams (percentile >10), a head circumference of 29 centimeters (percentile >10), adequate for gestational age, with a Capurro test of 33 WG.

A detailed examination revealed abundant dark hair, a low anterior hairline, a hypertrophic forehead, normotensive fontanelle, well-populated arched eyebrows with synophrys, straight palpebral fissures, an absence of nasal structures, maxillary hypoplasia, thin lips, intact palate with microretrognathia, low-set and posteriorly rotated ears with free lobes, symmetrical cylindrical neck without masses or lymph nodes, symmetrical chest with hypoplastic nipples and respiratory distress, rhythmic heart sounds, with no audible murmurs, the back with hypertrichosis, the abdomen with a clamped umbilical stump with two arteries and one vein, peristalsis was present with no masses or organomegaly, genitalia Tanner 1 male phenotype with a 1.4 centimeter micropenis and bilateral cryptorchidism, with symmetric, eutrophic extremities and no alterations, shown in Figure 1.

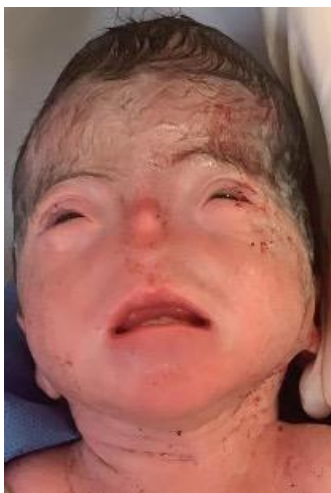

Figure 1: Neonate with congenital absence of the nose.

On admission to the NICU, the patient was treated for prematurity and respiratory distress syndrome. Pressure-limited invasive mechanical ventilation was indicated. A

venous umbilical catheter was placed with a fluid plan, without adrenergic support, fasting with a #8 orogastric tube, double antibiotic therapy regimen with ampicillin (100 mg/kg/dose) and amikacin (15 mg/kg/day), department of genetics and department of otolaryngology consultations were requested for assessment and treatment.

A karyotype was performed, which was reported as 46, XY with no numerical or structural alterations. A transfontanellar and abdominal ultrasound, echocardiography and plain CT of the paranasal sinuses were requested. On the transfontanellar ultrasound, increased periventricular echogenicity was reported as the only finding. On the abdominal ultrasound, bile sludge was reported as the only finding. The transthoracic echocardiogram did not show any structural or functional alterations. The plain CT of the paranasal sinuses showed absence of the anterior and posterior pyriform opening, absence of both nasal bones, the absence of ethmoids, both in their vertical and horizontal lamina and in the papyraceous lamina, absence of the nasal septum, observing a rudimentary nasal cavity occupied by material with soft tissue density, shown in Figure 2-4.

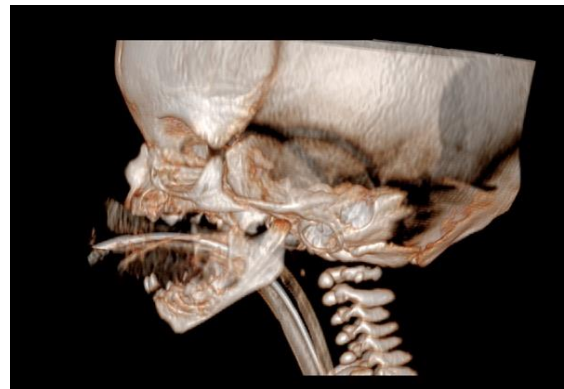

Figure 2: Lateral view in 3-D reconstruction with absence of the nasal bones.

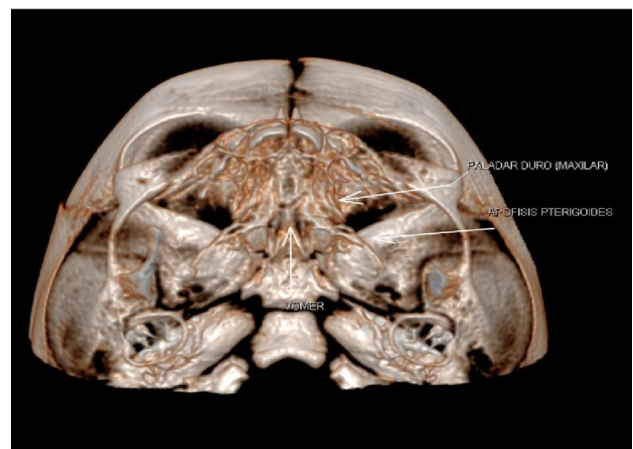

Figure 3: The hard palate is formed by the palatine process of the maxilla bilaterally, as well as rudimentary vomer bone.

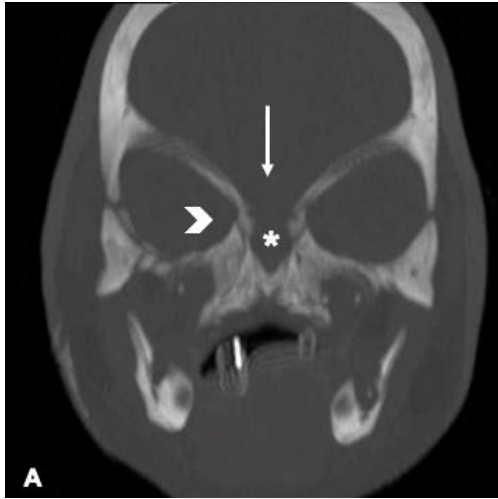


Figure 4: Axial soft tissue CT scan shows no pyriform aperture (*) and membranous choanal obstruction (^).

At 48 hours of extrauterine life, the child's clinical status deteriorated, with persistent respiratory acidosis, a reticular pattern, prolonged capillary filling and low cardiac output. He later presented spontaneous circulatory failure and advanced resuscitation maneuvers were started with no response, the child later died.

On autopsy, the final diagnosis was a male with 33.1 WG with facial abnormalities consisting of nasal agenesis and hypertelorism, neuronal hypoxia, agenesis of olfactory tracts and olfactory bulbs, the pituitary with vascular congestion, atrial septal ostium secundum defect, 12 ml pericardial effusion, mesothelial hypoplasia, type II nephrogenesis, acute tubular necrosis, necrosis of the adrenal medulla, mild bilateral barotrauma, the spleen with red pulp hemorrhage, the liver with extramedullary hematopoiesis, acute involution of the thymus, and bilateral cryptorchidism with testes with bilateral interstitial hemorrhage.

DISCUSSION

We presented a case of congenital absence of the nose not previously discovered during prenatal care. Arrhinia is the complete absence of both the nose and the olfactory apparatus. It is an extremely rare condition, in which less than 50 cases have been reported. The prenatal diagnosis of this disease can help in planning the management and postnatal treatment of the disease. However, if this pathology is not previously found, it can become a great challenge, as in our case.

It is known that neonates are nasal breathers and the absence of a nose leads to an obstacle in airway management.¹³ Initial management should ensure the airway with prompt intubation since, if not performed, the mismanagement of secretions, immaturity in breathing through the mouth and the absence of a nose can lead to death.

Once the airway has been secured with intubation, imaging studies such as skull CT or MRI can be performed to assess the patency of the upper airway and to plan surgical procedures such as tracheostomy or internal and external reconstruction of the nose. A plain skull CT scan with 3D reconstruction was performed in our patient and this study was subsequently evaluated by the otorhinolaryngology service to plan a tracheostomy to achieve a patent airway without depending on intubation. In addition, an MRI of the skull was planned to assess future patency of the internal and external nose, however, due to the patient's early death, it could not be performed.

A karyotype was performed to assess numerical alterations and it was found that our patient did not present any alteration, having a 46 XY karyotype. In most of the published cases, a normal karyotype was found, although alterations in chromosome 9 and translocations between chromosome 3 and 12 have been found.^{10,14}

BAMS has been described as a cause of arrhinia.⁷ The spectrum of the disease is highly variable, with arrhinia being the most important clinical finding occurring together with anophthalmia, microphthalmia and/or alterations in gonadal development. There are theories that state that this syndrome is associated with mutations in the SMCHD1, PAX6 gene with translocations (3;12) (q13.2; p11.2) being one of the main causes.¹⁵ A clinical characteristic in our patient was the presence of cryptorchidism and micropenis, which may be associated with the premature age of the patient and not related to hypogonadotropic hypogonadism, since the testes descend between 32 and 34 weeks of gestation.

The autopsy report confirmed the total absence of olfactory tracts, therefore, the syndrome can be classified as complete congenital arrhinia with this being the only case reported in Mexico to date.

CONCLUSION

Arrhinia is an extremely rare condition and there is no protocol to follow regarding its treatment. Primary management must ensure a patent airway and subsequently, individualized surgical management. The nose is an important part of the face, thus aesthetic and functional management is an important part in managing the patient to avoid problems of self-esteem in the future.

ACKNOWLEDGEMENTS

We would like to thank Sergio Lozano-Rodríguez for his help in translating this manuscript.

Funding: No funding sources

Conflict of interest: None declared

Ethical approval: Not required

REFERENCES

1. Funamura J, Tollefson T. Congenital anomalies of the nose. *Facial Plast Surg.* 2016;32(2):133-41.
2. Losee J, Kirschner R, Whitaker L, Bartlett S. Congenital nasal anomalies: a classification scheme. *Plast Reconstr Surg.* 2004;113(2):676-89.
3. Mondal U, Prasad R. Congenital arhinia: a rare case report and review of literature. *Indian J Otolaryngol Head Neck Surg.* 2016;68(4):537-9.
4. Cusick W, Sullivan A, Rojas B, Poole A, Poole D. Prenatal diagnosis of total arhinia. *Ultrasound Obstet Gynecol.* 2000;15(3):259-61.
5. Brusati R, Donati V, Marelli S, Ferrari M. Management of a case of arhinia. *J Plast Reconstr Aesthet Surg.* 2009;62(7):206-10.
6. Klinger M, Caviggioli F, Klinger F, Torsello F, Guidarelli P. Isolated congenital absence of the nasal bones and aesthetic surgical correction: managing and case report. *Aesthetic Plast Surg.* 2005;29(4):246-9.
7. Online Mendelian Inheritance in Man, OMIM®. McKusik-Nathans Institute of Genetic Medicine, Johns Hopkins University (Baltimore, MD), 2021. Available at: <https://omim.org/>. Accessed on 6 May 2021.
8. Shaw N, Brand H, Kupchinsky Z, Bengani H, Plummer L, Jones TI, et al. SMCHD1 mutations associated with a rare muscular dystrophy can also cause isolated arhinia and Bosma arhinia microphthalmia syndrome. *Nat Genet.* 2017;49(2):238-48.
9. Dekaban A. (1959). Arhinencephaly in an infant born to a diabetic mother. *J Neuropathol Exp Neurol.* 1959;18:620-6.
10. Cohen D, Goitein K. Arhinia. *Rhinology.* 1986;24(4):287-92.
11. Kaminker C, Dain L, Lamas M, Sánchez M. Mosaic trisomy 9 syndrome with unusual phenotype. *Am J Med Genet.* 1985;22(2):237-41.
12. Becerra L, Chacón L, Morales D, Zenteno J, Ramírez-Dueñas ML, García-Ortiz JE. Bosma arhinia microphthalmia syndrome in a mexican patient with a molecular analysis of PAX6. *Clin Dysmorphol.* 2016;25(1):12-5.
13. Bergerson P, Shaw J. Are infants really obligatory nasal breathers? *Clin Pediatr (Phila).* 2001;40(10):567-9.
14. Hou J. Congenital arhinia with de novo reciprocal translocation, t(3;12)(q13.2;p11.2). *Am J Med Genet A.* 2004;130(2):200-3.
15. Trivedi A, Bean T, Brown K, Cain C. Bosma arhinia microphthalmia and cardiac abnormalities: a case report. *Clinic Med Revs Case Rep.* 2020;7(5):1-3.

Cite this article as: Nieto-Sanjuanero A, García-Ramírez A, Martínez-Cobos M, Martínez-Garza, E, O-Cavazos MDL, Quintanilla-Loredo R, et al. Neonate with congenital absence of the nose: case report. *Int J Otorhinolaryngol Head Neck Surg* 2021;7:1384-7.