

Case Report

High-flow nasal oxygen for laryngeal tumor debulking: case report and current challenges

Francois Lemay^{1*}, Benoit Guay², Pascal Labrecque¹

¹Département d'anesthésiologie et de soins intensifs, Université Laval, Québec, Canada

²Département d'Oto-rhino-laryngologie-chirurgie cervico-faciale et d'ophtalmologie, Université Laval, Québec, Canada

Received: 18 April 2021

Revised: 17 May 2021

Accepted: 18 May 2021

***Correspondence:**

Dr. Francois Lemay,

E-mail: francois.lemay.5@ulaval.ca

Copyright: © the author(s), publisher and licensee Medip Academy. This is an open-access article distributed under the terms of the Creative Commons Attribution Non-Commercial License, which permits unrestricted non-commercial use, distribution, and reproduction in any medium, provided the original work is properly cited.

ABSTRACT

High-flow nasal oxygen (HFNO) has brought new opportunities in shared airway surgery. Contemporary challenges with its use in severely obstructive conditions such as laryngeal tumors still need to be addressed as there is discrepancy in its use and access among centres. We reported a case in which the use of HFNO allowed laryngeal tumor debulking while avoiding tracheotomy in a stridorous patient. The patient described was a 70 year old patient with stridor at rest secondary to a laryngeal tumor diagnosed five days before surgery. Tumor debulking could be safely initiated under general anaesthesia, which would not have been possible without HFNO. This report served as an example of an alternative to awake tracheotomy in the management of severely obstructive laryngeal pathology. We wish to discuss through this case management of severely obstructive laryngeal pathology in the era of HFNO, while encouraging discussion on its potential benefits and limits.

Keywords: Laryngologic surgery, Transnasal humidified rapid-insufflation ventilatory exchange, High-flow nasal oxygen, Airway management

INTRODUCTION

HFNO has been recently recommended for awake tracheal intubation and prevention of peri-induction hypoxemia under general anaesthesia.^{1,2} Using HFNO, transnasal humidified rapid-insufflation ventilatory exchange (THRIVE) had previously emerged as a promising apnoeic technique for tubeless laryngologic surgery in difficult airways.³ Recently published studies have reinforced benefits of THRIVE in patients undergoing elective laryngological procedures.^{4,5} We wish to highlight questions that merit attention when using THRIVE in the context of severe, obstructive upper airway pathologies through a case in which its use allowed to proceed with laryngeal tumor debulking while

avoiding tracheotomy in a stridorous patient. This case illustrated contemporary challenges with the use of HFNO in difficult airways. It also served as an example of an alternative to awake tracheotomy and questions the limits of HFNO in the management of severely obstructive laryngeal pathology. The patient described had consented to publication and approval was waived by the CHU de Québec-université laval research ethics committee on the 26 February 2021.

CASE REPORT

A 70 year old male, 77 kgs (BMI 26) was scheduled for microlaryngoscopy, biopsy, tumor debulking±tracheotomy. His medical history included anxiety, chronic

alcohol consumption and tobacco smoking. A transglottic tumor had been diagnosed 5 days prior to surgery (Figure 1). The patient was stridulous at rest and described choking episodes during which he struggled to clear secretions, preventing him from lying flat. His anxiety was notable and he became distressed when awake airway management, including tracheotomy was evoked. His S_pO_2 on room air was 95 % with a respiratory rate of 16 breaths per minute.

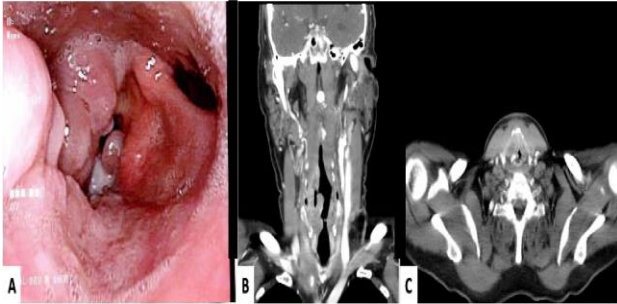


Figure 1: (A) Flexible laryngoscopy showing a bulky, right-sided transglottic laryngeal mass with airway compromise; (B and C) CT-scan images showing laryngeal mass with airway compromise and extensive laryngeal destruction.

As a tracheotomy was deemed necessary only if debulking proved to be insufficient and considering the uncertain cooperation with awake airway management, general anaesthesia with the use of HFNO to maintain oxygenation throughout the procedure was preferred. Starting in the semi-sitting position, pre-oxygenation was performed with HFNO via Optiflow (Fisher and Paykel healthcare, Auckland, New Zealand) and was titrated up to $70 \text{ L}\cdot\text{min}^{-1}$ at F_iO_2 of 1.0. S_pO_2 increased to 98%. Notably, the patient's stridor had disappeared with the use of HFNO, which allowed for 15 degrees reverse Trendelenburg. HFNO was then briefly removed to measure end-tidal O_2 with a standard facemask to evaluate the quality of pre-oxygenation, but the patient became immediately stridulous and distressed. HFNO was hence resumed and relieved the patient once again. General anaesthesia was achieved with total intravenous anaesthesia and neuromuscular blockade with 180 mg of succinylcholine. Microlaryngoscopy was performed with a Kleinsasser laryngoscope and Opmi Vario microscope (Carl Zeiss, Jena, Germany). After 5 minutes of suspension during which S_pO_2 was maintained at 98% with HFNO, debulking duration was reassessed and forecasted to take longer than initially thought. To promote ventilation in case of prolonged apnoea with limited gas exchange with HFNO, a 4.0 microlaryngoscopy tracheal tube was tightly inserted through the glottis. After 45 minutes of surgery, the glottic aperture could accommodate a 7.0 tracheal tube and the patient had an uneventful recovery. The patient felt relieved that a tracheotomy could be avoided and could be discharged home the day after surgery.

DISCUSSION

In this case, HFNO allowed for smooth induction of anaesthesia and partial tumor debulking. The risk of complete airway obstruction during awake tracheal intubation was deemed to be significant and the latter was thought to be less desirable than an awake tracheotomy. Awake tracheotomy requires both a collaborative patient and an experienced surgeon. This can be challenging in patients with impending airway obstruction. THRIVE may thus allow for a safe, non-surgical initial airway management and gives the option of performing the tracheotomy afterwards in controlled conditions. If awake intubation or awake tracheotomy would have been attempted, HFNO would also have optimized conditions through relief of stridor and better oxygenation. It reinforces that HFNO should be strongly considered in any patient who elicits symptoms of severe airway compromise, whatever which airway management plan is chosen. Tracheotomy could be avoided, which has a high impact on the patient including several days of hospitalization. In this case, the patient could safely be discharged the day after the procedure. In case of subsequent total laryngectomy, previous tracheotomy would also imply an unnecessary tracheal sacrifice often associated with tracheostoma wound healing issues.

THRIVE could be initiated as it has shown to maintain oxygenation in apnoeic patients despite severe upper airway pathologies.^{3,6} However, despite many series describing such success, no solid data is available regarding risk factors for failure in tumor debulking and there is a need for better evidence concerning factors predicting success or failure of THRIVE in obstructed airways. Careful planning is thus mandatory. In this case we presented, there were no signs of difficult exposure to suspension laryngoscopy. The patient was not obese nor carried major lung disease, which could contribute to early desaturation when using THRIVE. Back-up plans including tracheotomy were previously discussed and immediately practicable in case of microlaryngoscopy failure. HFNO could be used as no ignition sources were to be used during surgery. The need for airway protection with a tracheal cuff was not an issue as the patient was fasted and did not carry risk factors for aspiration. Worth mentioning, if tracheal intubation would have become necessary at any stage, airway anatomy may get more delineated as debulking and microlaryngoscopy progress, which may render intubation easier.

CONCLUSION

We believe this clinical case raises attention on benefits of THRIVE that goes far beyond providing a tubeless surgical field for airway surgery. HFNO should be strongly considered in any patient who elicits symptoms of severe airway compromise. Our case provides detailed information on the clinical considerations and implementation of HFNO in the management of obstructed larynx. There is still an important discrepancy worldwide

in the use and access to HFNO for shared airway surgery. While some centres have developed expertise in its use and regularly use it for shared airway cases, others still not have such straightforward access to HFNO. We thus believe there is still a need for clinicians to share their experience with THRIVE to promote better understanding of circumstances allowing for its safe use in obstructing pathologies. While this case highlights benefits that can be expected when using HFNO on symptomatic, obstructive laryngeal lesions, the availability of HFNO should not influence the decision-making process regarding the airway management outside such dedicated shared-airway procedures. Outside this context, we believe that availability of HFNO should be considered as a tool which can be implemented to increase the safety of airway management while not modifying the approach to the anticipated difficult airway.

ACKNOWLEDGMENTS

We would gratefully like to thank Dr Philippe Lachance (Anesthesiology, MD, MBA) for his input and support in the handling of this manuscript.

Funding: No funding sources

Conflict of interest: None declared

Ethical approval: Not required

REFERENCES

1. Ahmad I, El-Boghdadly K, Bhagrath R, Hodzovic I, McNarry AF, Mir F, et al. Difficult airway society guidelines for awake tracheal intubation (ATI) in adults. *Anaesthesia*. 2020;75(4):509-28.
2. Spence EA, Rajaleelan W, Wong J, Chung F, Wong DT. The effectiveness of high-flow nasal oxygen during the intraoperative period: a systematic review and meta-analysis. *Anesthes Analges*. 2020;131(4):1102-10.
3. Patel A, Nouraei SAR. Transnasal humidified rapid-insufflation ventilatory exchange (THRIVE): a physiological method of increasing apnoea time in patients with difficult airways. *Anaesthesia*. 2015;70(3):323-9.
4. Nekhendzy V, Saxena A, Mittal B, Sun E, Sung K, Dewan K, et al. The safety and efficacy of transnasal humidified rapid-insufflation ventilatory exchange for laryngologic surgery. *Laryngoscope*. 2020;130(12):874-81.
5. Benninger MS, Zhang ES, Chen B, Tierney WS, Abdelmalak B, Bryson PC. Utility of transnasal humidified rapid insufflation ventilatory exchange for microlaryngeal surgery. *Laryngoscope*. 2020;131(3):587-91.
6. Lyons C, Callaghan M. Apnoeic oxygenation with high-flow nasal oxygen for laryngeal surgery: a case series. *Anaesthesia*. 2017;72(11):1379-87.

Cite this article as: Lemay F, Guay B, Labrecque P. High-flow nasal oxygen for laryngeal tumor debulking: case report and current challenges. *Int J Otorhinolaryngol Head Neck Surg* 2021;7:1045-7.