

## Case Report

# Laryngeal lipoma: case series- successful microlaryngeal surgery

M. Babu Manohar, Soorya A. Rao\*

Department of Otorhinolaryngology and Head and Neck Surgery, Apollo Hospitals, Chennai, India

**Received:** 15 April 2021

**Revised:** 22 May 2021

**Accepted:** 24 May 2021

**\*Correspondence:**

Dr. Soorya A. Rao,

E-mail: sooryarao14@gmail.com

**Copyright:** © the author(s), publisher and licensee Medip Academy. This is an open-access article distributed under the terms of the Creative Commons Attribution Non-Commercial License, which permits unrestricted non-commercial use, distribution, and reproduction in any medium, provided the original work is properly cited.

### ABSTRACT

Lipoma of the larynx is a very rare entity. In this study, we report two cases of lipoma of the larynx. The first case presented to us with hoarseness of voice and choking sensation and was diagnosed using a flexible fiberoptic video laryngoscopy and a computerised tomography (CT) of the neck. The lesion was excised surgically using microlaryngoscopic method. The diagnosis was confirmed histopathologically. Follow-up after 2 years showed no residual or recurrent lesions. The second case was a middle aged man with change in voice, burning sensation and foreign body sensation in throat. Flexible fiberoptic videolaryngoscopy showed a small ventricular swelling on the right side in the anterior part. We considered the provisional diagnosis of a benign tumor and proceeded with microlaryngoscopic excision without any radiological investigation. Diagnosis of Lipoma was revealed after the histopathologic examination. We are reporting this case to highlight the rare location of the lesions and the successful use of microlaryngoscopic surgery.

**Keywords:** Lipoma larynx, Flexible fiberoptic endoscopy, Microlaryngeal surgery

### INTRODUCTION

Lipomas are benign mesenchymal tumours which are usually found in areas where fat is in abundance. Around 115 cases are reported in head and neck region.<sup>1</sup> Common presentation of laryngeal lipoma is dysphagia, change in voice or breathing difficulty. It is important to conduct proper videolaryngoscopic examination in such patients and proper recognition of the benign or malignant nature of the mass.

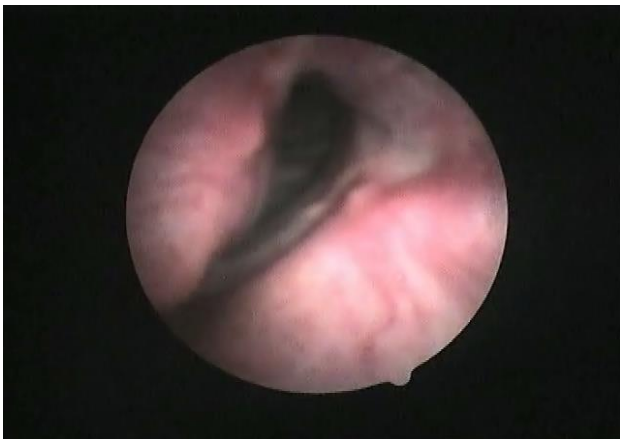Further radiological studies help in the confirmation of diagnosis. Owing to the site of the lesion, microlaryngeal surgery is required for accurate and safe excision of the lesion and histopathologic confirmation of the diagnosis which is also therapeutic.

### CASE REPORT

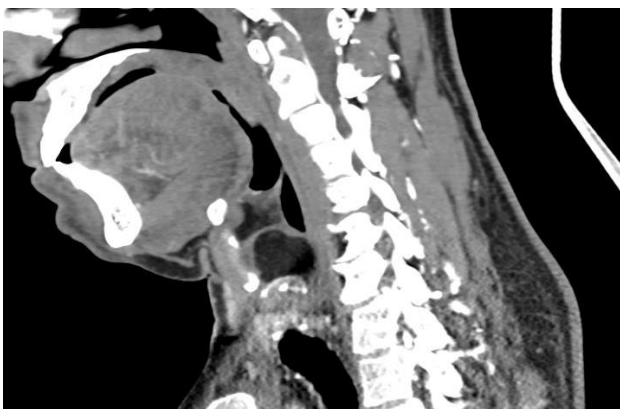
#### Case 1

A 53-year-old man came to our department with hoarseness of voice and choking sensation for 6 months. He had other symptoms of nasal obstruction and right side ear block. There was a history of tobacco abuse and on examination, submucous fibrosis was seen in the oral cavity. On indirect laryngeal examination, ventricular fullness was seen. Flexible fiberoptic videolaryngoscopy (Figure 1) showed a mucosa intact swelling in the right supraglottis, right ventricle, and right aryepiglottic fold. Right vocal cord medialisation was noticed. The mobility of both vocal cords was normal. There was no airway compromise. The patient was subjected to computerised tomography (CT) of the neck (Figure 2) which showed a

well-defined fat attenuating lesion measuring 2.1×2.7×1.5 cm in the right paraglottic region causing bulging of the true cord. The lesion extended from the supraglottis to the glottis. Laterally it was limited by the thyroid lamina. Anterior commissure was free. Posteriorly it reached just upto the level of anterior margin of the cricoid cartilage. The right cricoarytenoid joint was involved and distorted. Few sub centrimetric lymph nodes were noticed. A diagnosis of paraglottic lipoma was considered. A preoperative histological diagnosis was not considered as a pre-requisite, firstly because of the location of the tumor, and secondly, a good diagnosis can be made with a densitometry-assisted CT scan. Microlaryngoscopic excision was planned using an operating microscope. The patient was taken to the operation theatre and a wide laryngoscope was used. After visually fixing the site of the incision (summit of the bulge), local infiltration was given with 2% lignocaine with 1: 2 lakh adrenaline. Then, the mucosa was cauterized to reduce the bleeding. 1.5 cm linear incision was made. By blunt dissection, using microlaryngeal instruments, the tumor was removed in toto. The histopathological analysis confirmed our provisional diagnosis of lipoma.



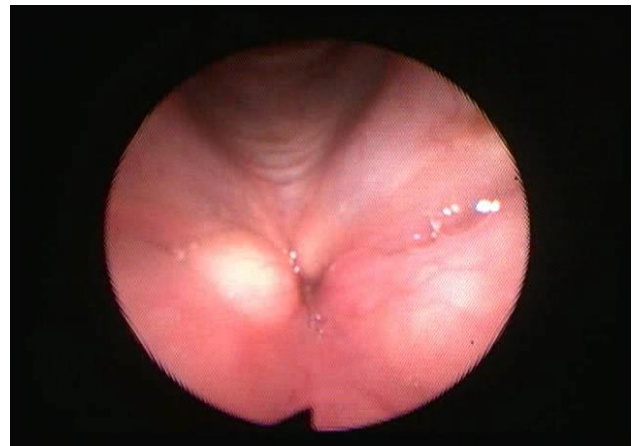**Figure 1: Flexible fiberoptic videolaryngoscopy showing ventricular fullness in right side.**



**Figure 2: A well-defined fat attenuating lesion measuring 2.1×2.7×1.5 cm in the right paraglottic region causing bulging of the cord.**

## Case 2

A middle-aged man presented with a change in voice, pain, burning sensation, and foreign body sensation in the throat for 6 months. He had other symptoms of nasal block and snoring. Examination of the nose revealed deviation of the nasal septum to left. The indirect laryngoscopic examination was not possible due to excessive gag reflex. Flexible fiberoptic videolaryngoscopy was done which showed a small ventricular swelling on the right side in the anterior part of the larynx. The rest of the larynx and vocal cords were normal (Figure 3). A provisional diagnosis of a benign laryngeal tumor was considered. Considering the small size of the tumor and the benign appearance with intact mucosa, we directly proceeded with microlaryngoscopic excision of the tumor without a radiological confirmation. Suspension laryngoscopy was done under general anaesthesia. The small ventricular swelling was visualized and under microscopic visualization, it was excised precisely using microcup forceps and scissors. Histopathological examination of the specimen showed features of lipoma.



**Figure 3: Small ventricular swelling in the right side on the anterior part.**

## DISCUSSION

A lipoma is a benign tumor of mesenchymal origin. Around 100 cases of lipoma have been reported in the upper aerodigestive tract. They represent 4-5% of all benign tumors of the body and 0.6% of all benign tumors of the larynx.<sup>1</sup> New and Erich in their study of 722 cases of benign laryngeal neoplasms, found only 1 case of lipoma (0.1%). They are usually seen in the elderly when fat gets a tendency to accumulate in the soft tissues.<sup>2</sup> Most commonly they are seen in supraglottis.<sup>3,4</sup> Laryngeal lipomas can be either intrinsic or extrinsic. Extrinsic lipomas are superficial and localized in the laryngeal ventricle. Intrinsic lipomas are deep and form part of subepithelial structures. Zarkowski stated that out of 70 cases tested by him, 16 were true intrinsic. To date, no case of lipoma has been reported within the histological structure of vocal cords.<sup>3,5</sup> Lipoma in the larynx and paraglottic space mostly presents as dysphagia, airway

compromise, and change in voice in males of the older age group.<sup>6</sup> Smoking and tobacco usage have no considerable impact on the incidence of the disease. One percent of patients may have airway compromise leading to tracheostomy.

The etiology of laryngeal lipoma is postulated as an unknown mechanism in which a multipotent fibroblast differentiates into a fat cell. Grossly they are of variable size. They can be smooth or lobulated, often well differentiated or encapsulated with a yellowish color. Clinically lipomas should be differentiated from other benign lesions such as retention cysts and laryngoceles by endoscopic appearance that can range from a submucosal mass to pedunculated intraluminal projection. Microscopically they are composed of mature adipocytes with large central vacuole, which often displace the nucleus peripherally. Differentiation of benign and malignant lipomatous tumors is difficult because myxoid degeneration and the presence of lipoblast cells can mimic malignancy.

Malignant transformation of the lipoma to liposarcoma has been reported.<sup>7,8</sup> Whether this is a true transformation or merely a low-grade malignant primary tumor inadequately excised or underdiagnosed is controversial. Immunohistochemical markers such as S-100, vimentin, mivine double minute -2(MDM-2), and cyclin dependant kinase 4 are the recent advances in the diagnosis of liposarcoma. The recent classification of benign lipomatous tumors includes the following categories: classic lipoma; lipoma variants, such as angiolipoma, chondroid lipoma, myolipoma, and spindle cell/pleomorphic lipoma, all with specific clinical and histological features.<sup>9,10</sup>

Treatment is surgical removal. The size of the tumor defines the surgical approach. Endoscopic removal of lipoma larynx is often insufficient leading to residual disease and thus recurrence. In our case, microlaryngoscopic removal has been done in toto, and follow-up fiberoptic laryngoscopy after 2 years showed no signs of recurrence.

External approach through transcervical route, lateral pharyngotomy, laryngofissure, sub-hyoid pharyngotomy are suitable for large lipomas.<sup>11</sup>

Microlaryngoscopic approaches have been reported in the literature as suitable for pedunculated and small lipomas. The microlaryngoscopic approach gives lesser post-operative morbidity and lesser hospital stay. Also, the need for a tracheostomy is minimal. Relapse is common after surgery and requires systematic follow-up for an extended period. Further investigations for sarcoma are required for relapse cases.<sup>7</sup>

We are reporting these cases to highlight the occurrence of the condition in such a rare site and the successful treatment with microlaryngoscopic surgery.

## CONCLUSION

The lipoma of the larynx is rare. Fiberoptic videolaryngoscopy is a reliable investigation to determine the gross appearance and extent of the lesion. A radiological confirmation is useful in doubtful lesions but not essential. Microlaryngoscopic excision of the lesion is advised when the swelling is small and one is well equipped to do it.

*Funding: No funding sources*

*Conflict of interest: None declared*

*Ethical approval: Not required*

## REFERENCES

1. Ashtiani MT, Yazdani N, Saeedi M, Amali A. Large lipoma of the larynx: a case report. *Acta Medica Iranica*. 2010;353-6.
2. Murphey MD, Kransdorf MJ. *Soft Tissue Tumors*. Berlin. Mosby. 1995.
3. Oguz G, Barutcu O, Derekoy FS. The Case of Laryngeal Lipoma. *J Otol Rhinol*. 2016;2013.
4. Wenig BM. Lipomas of the larynx and hypopharynx: a review of the literature with the addition of three new cases. *J Laryngol Otol*. 1995;109(4):353-7.
5. Bildirici K, Keçik C, Peker B, İlğici D. Larenks Lipomu: Bir Olgu Sunumu. *Cerrahpaşa Tıp Dergisi*.;32(2).
6. Özmen CA, Nazaroğlu H, Yildirim M, Akay H, Bayrak A. A rare cause of dysphonia:laryngeal lipoma: Differential diagnosis. *Türkiye Klinikleri J Med Sci*. 2009;29(6):1789.
7. Yoskovitch A, Cambrono E, Said S, Whiteman M, Goodwin WJ. Giant lipoma of the larynx: a case report and literature review. *Ear, nose throat J*. 1999;78(2):122-5.
8. Gaskin CM, Helms CA. Lipomas, lipoma variants, and well-differentiated liposarcomas (atypical lipomas): results of MRI evaluations of 126 consecutive fatty masses. *Am J Roentgenol*. 2004;182(3):733-9.
9. Furlong MA, Fanburg-Smith JC, Childers EL. Lipoma of the oral and maxillofacial region: Site and subclassification of 125 cases. *Oral Surg Oral Med Oral Pathol Oral Radiol Endodontology*. 2004;98(4):441-50.
10. Bridge JA, Hogendoorn P, DM C, Bridge JA, CW P, Fletcher CD. WHO classification of tumours of soft tissue and bone. International Agency for Research on Cancer. 2013.
11. De Vincentiis M, Greco A, Mascelli A, Soldo P, Zambetti G. Lipoma of the larynx: a case report. *Acta Otorhinolaryngologica Italica*. 2010;30(1):58.

**Cite this article as:** Manohar MB, Rao SA. Laryngeal lipoma: case series- successful microlaryngeal surgery. *Int J Otorhinolaryngol Head Neck Surg* 2021;7:1202-4.