

Case Report

Contralateral sensorineural deafness in the absence of temporal bone fractures: an ignored entity in traumatic brain injury

Marie Christy Sharafine Stephen*, Anju Venugopalan, Nagaraj Bangalore Thimmasettaiah

Department of ENT, MVJ Medical College and Research Hospital, Hoskote, Karnataka, India

Received: 13 April 2021

Accepted: 17 May 2021

*Correspondence:

Dr. Marie Christy Sharafine Stephen,
E-mail: sharafine@gmail.com

Copyright: © the author(s), publisher and licensee Medip Academy. This is an open-access article distributed under the terms of the Creative Commons Attribution Non-Commercial License, which permits unrestricted non-commercial use, distribution, and reproduction in any medium, provided the original work is properly cited.

ABSTRACT

Traumatic brain injury (TBI) associated with temporal bone fractures causing ipsilateral hearing loss is not uncommon. But contralateral sensorineural hearing loss (SNHL) in the absence of temporal bone fractures is not frequently encountered or looked for in TBI patients. A simple bed side tuning fork test followed by a formal audiogram underscore the importance of pre-emptive assessment to prevent a permanent handicap. We report a case of a young man with no prior ear disease or comorbidities, who sustained traumatic brain injury with right parieto-temporal hemorrhagic contusion and cervical myelopathy following a two-wheeler fall. Although, there was no evidence of temporal bone fractures, he developed sudden profound deafness on the contralateral side of the brain injury. Evaluation and treatment for the same were initially delayed as the management solely focused on his neurological complaints and as the hearing loss was contralateral it was perceived to be unrelated to his brain injury. We want to highlight the importance of thorough evaluation and screening for bilateral hearing loss in patients with TBI irrespective of the presence or absence of temporal bone fractures to initiate appropriate management. We also want to add our patient to the very few such cases reported in the literature. We analyzed these cases and reviewed the possible pathophysiological mechanisms behind this entity.

Keywords: Traumatic brain injury, Contralateral sensorineural hearing loss, Temporal bone fractures, Labyrinthine concussion

INTRODUCTION

The prevalence of ipsilateral SNHL with associated temporal bone fractures in TBI ranges from 14% to 67%.¹ Direct anatomic disruption of the auditory nerve, the inner ear sensory neuro-epithelium, injury to the brainstem (at inferior colliculi) or brain parenchyma (temporal lobe contusions) are reasons postulated.^{1,2} Contralateral SNHL is often overlooked, reported only a handful and the causes remain elusive. A high index of suspicion is needed for timely diagnosis which if delayed hometown. Following recovery from this brief period of unconsciousness, he noticed right limb paresthesia,

or ignored may deny a patient of the possible recovery only to suffer a permanent handicap.

CASE REPORT

A 31 years old male presented to our outpatient department with complaints of left sided deafness. 3 weeks before presenting to our hospital, he had had a road traffic accident with a two-wheeler fall. He had sustained right sided head injury with loss of consciousness and was admitted at a hospital, close to his disequilibrium and also perceived left sided decrease in hearing. Initial brain imaging at the treating hospital had

revealed cervical myelopathy C5-C6, hemorrhagic contusion of right temporo-parietal region with no temporal bone fractures. He had received appropriate conservative management for his neurological deficits. However, the hearing loss on the contralateral side of the brain injury was not further investigated into and was presumed to be unrelated to the traumatic brain injury. After a week of hospital stay, he was discharged home on neck collar with improved neurological status.

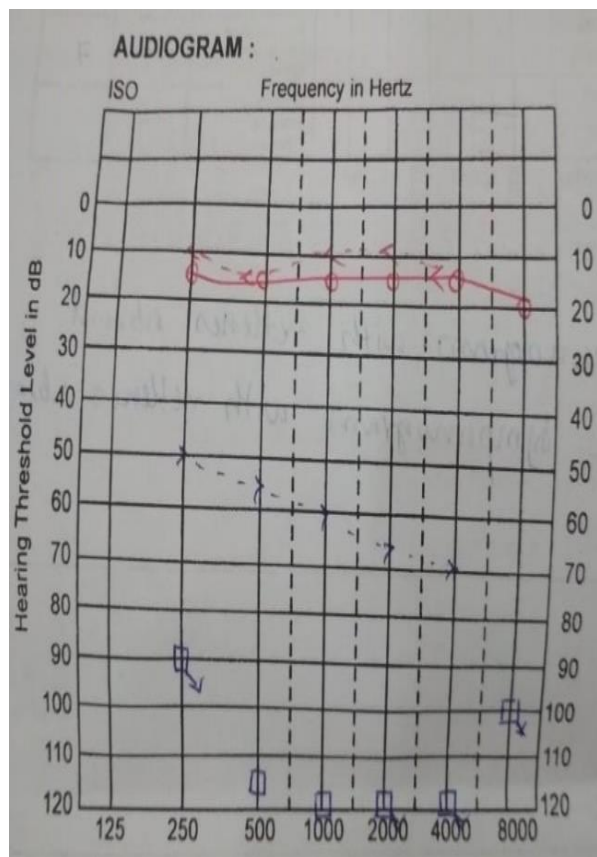


Figure 1: Pure tone audiogram: right normal hearing and left profound sensorineural hearing loss.

3 weeks from the time of head injury, he presented to our hospital, to consult for his left ear deafness and tinnitus, as by now, his motor deficits were significantly improving. There were no other positive contributory history and examinations were normal. Pure tone audiogram revealed right normal hearing and left profound SNHL with absent reflexes (Figure 1). Repeat MRI brain showed resolving right temporal superficial cortical hemorrhagic contusions (Figure 2). There were no abnormal changes noticed in his auditory apparatus. A possible labyrinthine concussion was suspected from the initial traumatic head injury causing contralateral sensorineural deafness. He was offered a trial of oral corticosteroids in tapering dose, besides hearing preservation strategies and bi-annual audiogram screening for the other ear, but his SNHL persisted when reviewed further at 3 weeks.

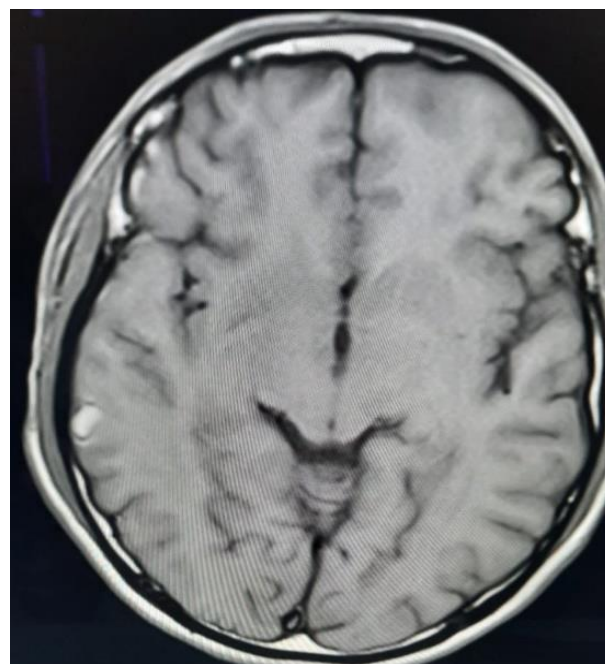


Figure 2: MRI brain, axial section; resolving superficial cortical hemorrhagic contusion in the right temporo-parietal region.

DISCUSSION

Contralateral SNHL in the absence of temporal bone fractures in traumatic brain injury, like seen in our patient is not common. Only a handful of cases have been reported in the literature (Table 1).³⁻⁹ It is attributed to labyrinthine concussion due to direct transmission of high pressure waves to the cochlea by bone conduction or by elevated intracranial pressure through internal auditory canal, cochlear aqueduct and endolymphatic sac, thus disrupting the organ of corti.^{3,4} Still, definite patho-anatomical studies is needed to understand the exact pathogenesis.

Our patient had sustained parieto-temporal hemorrhagic contusion, associated with tinnitus and disequilibrium, like reported by others.^{3,4,6,9} In addition, he suffered cervical myelopathy which improved significantly. Apart from the specific neurosurgical intervention aimed at his neurological deficits secondary to traumatic brain injury, expectant management was offered for SNHL in most studies.^{4,6,8} Our patient presented to us at 3 weeks post trauma and a trial of corticosteroids did not improve his SNHL, like shown by two other authors at 2 months and 1 year post trauma.^{4,6} Probably some benefit in his hearing could have been expected with earlier initiation of steroids like reported by Villarreal et al who showed a 15 dB gain in all frequencies at 1 week of corticosteroids. A simple bedside tuning fork test may help screen for SNHL, followed by a formal audiometric assessment. Cochlear implantation was offered to a patient with bilateral SNHL at 25 months post trauma and the hearing had improved to telephonic communications.⁵

Table 1: Analysis of reported cases in literature-contralateral hearing loss in head injury with or without temporal bone fractures.³⁻⁹

Articles	Number of cases reported	Mode of injury	Side and type of head injury	Side of SNHL	Associated otological symptoms	(±TBF) temporal bone fractures	Mechanism postulated	Treatment	Follow-up
Ulug et al	3	Not mentioned. (only abstract seen)	Right longitudinal TBF+labyrinthine concussion	Left SNHL (notch of 60 dB at 4 KHz)	Ipsilateral facial paralysis	+	Labyrinthine concussion	Facial palsy surgically managed; labyrinthine concussion expectant management	At 1 year hearing loss persisted
			Right mixed type TBF+labyrinthine concussion	Left SNHL (peak of 50 dB at 40 KHz).		+	Labyrinthine concussion		
			Left mixed type TBF+right labyrinthine concussion	Right SNHL of 60 dB at 4 KHz		+	Labyrinthine concussion		
Hunchaisri et al	1	Not mentioned. (only abstract seen)	Unilateral TBF	Bilateral SNHL	Nil	+	Occlusion of internal auditory artery	Not mentioned. (only abstract seen)	Not known. (only abstract seen)
Khairi et al	2	Industrial injury-a piece of metal sheet fell off a crane and hit the roof of the vehicle that the patient was in	Left parieto-occipital bone fracture, subgaleal hematoma+left posterior fossa EDH	Right SNHL	Haemotympanum right ear	-	Labyrinthine concussion	Craniotomy and evacuation of EDH	Not known. (only abstract seen)
		Motor vehicle accident-hit by a motorcyclist	Right occipital EDH, occipital subgaleal hematoma	Left profound SNHL, right high frequency HL	Nil	-	Labyrinthine concussion	Expectant management	Not known. (only abstract seen)
Toh et al	1	Assault and punched repeatedly on left side of face	No e/o fistula/fracture	Right profound SNHL	Disequilibrium, vertigo, Tullio phenomenon	-	Contra-coup labyrinthine concussion, non- radiologically apparent traumatic perilymph fistula in the contralateral ear considered as differential.	Conservative management	At 2 months, vertigo and SNHL persisted
Villarreal et al	1	Blunt trauma left head-hit with a hammer during an altercation	Nil	Right profound SNHL	Right tinnitus	-	Labyrinthine concussion	Oral cortico-steroids (deflazacort at 1 mg/kg/day beginning with 70 mg and slowly tapering the dose) was given	1 week, 15 dB gain in all frequencies
Fujimoto et al (2007)	1	Fell downstairs	Traumatic SAH with bilateral frontal lobes and left middle temporal gyrus brain contusions	Bilateral progressive profound SNHL	Nil	-	Not mentioned	Cochlear implantation at 25 months post trauma	Improved to telephonic communication
Chiaromonte et al	1	Not mentioned	Right intralabyrinthine hemorrhage on MRI	Bilateral severe SNHL	Postural imbalance	-	Labyrinthine concussion	Not mentioned	Not mentioned
Our patient in this report	1	Fall from two-wheeler while avoiding a pedestrian	Right parieto-temporal hemorrhagic contusion with cervical myelopathy	Left profound SNHL	Left tinnitus, disequilibrium	-	Possible labyrinthine concussion	Trial of steroids at patient presentation (after 3 weeks of TBI)	Profound SNHL persisted at 6 weeks of head injury

CONCLUSION

Labyrinthine concussion on the contralateral side of head injury causing profound SNHL is an infrequent entity and should be borne in mind in the initial trauma assessment of traumatic brain injury patients even in the absence of temporal bone fractures. Screening for bilateral hearing loss should be done and the diagnosis is easily established on audiometry. Our case highlights the rarity of the problem and signifies the importance of hearing screening in trauma patients for earlier initiation of treatment to prevent any devastating permanent hearing handicap.

Funding: No funding sources

Conflict of interest: None declared

Ethical approval: Not required

REFERENCES

1. Ishai R, Knoll RM, Chen JX, Wong K, Reinshagen KL, Nadol JB, et al. Otopathologic Changes in the Cochlea following Head Injury without Temporal Bone Fracture. *Otolaryngol Head Neck Surg.* 2018;159(3):526-34.
2. Chen JX, Lindeborg M, Herman SD, Ishai R, Knoll RM, Remenschneider A, et al. Systematic review of hearing loss after traumatic brain injury without associated temporal bone fracture. *Am J Otolaryngol.* 2018;39(3):338-44.
3. Villarreal IM, Méndez D, Silva JMD, Álamo POD. Contralateral cochlear labyrinthine concussion without temporal bone fracture: unusual posttraumatic consequence. *Case Rep Otolaryngol.* 2016;2016:2123182.
4. Toh A, Ho EC, Turner N. Contralateral deafness post head injury without temporal bone fractures. *Am J Otolaryngol.* 2010;31(1):54-6.
5. Fujimoto C, Ito K, Takano S, Karino S, Iwasaki S. Successful cochlear implantation in a patient with bilateral progressive sensorineural hearing loss after traumatic subarachnoid hemorrhage and brain contusion. *Ann Otol Rhinol Laryngol.* 2007;116(12):897-901.
6. Ulug T, Ulubil SA. Contralateral labyrinthine concussion in temporal bone fractures. *J Otolaryngol.* 2006;35(6):380-3.
7. Hunchaisri N. Bilateral sudden sensorineural hearing loss following unilateral temporal bone fracture. *J Med Assoc Thail.* 2009;92(3):76-9.
8. Khairi MDM, Irfan M, Rosdan S. Traumatic head injury with contralateral sensorineural hearing loss. *Ann Acad Med Singapore.* 2009;38(11):1017-8.
9. Chiamonte R, Bonfiglio M, D'Amore A, Viglianesi A, Cavallaro T, Chiamonte I. Traumatic Labyrinthine Concussion in a Patient with Sensorineural Hearing Loss. *Neuroradiol J.* 2013;26(1):52-5.

Cite this article as: Stephen MCS, Venugopalan A, Thimmasettaiah NB. Contralateral sensorineural deafness in the absence of temporal bone fractures: an ignored entity in traumatic brain injury. *Int J Otorhinolaryngol Head Neck Surg* 2021;7:1055-8.