

Original Research Article

Aplasia and agenesis of the frontal sinus in individual of southern region in Saudi Arabia

Radeif Shamakhi^{1*}, Musleh Mubarak², Ramzi Dighriri³, Azza Almarir⁴, Alaa Alyahya⁴

¹Department of Otorhinolaryngology Head and Neck Surgery, Prince Mohammed Hospital, Jizan, KSA

²Department of Otorhinolaryngology Head and Neck Surgery, Aseer central Hospital, Aseer, KSA

³Department of Otorhinolaryngology Head and Neck Surgery, Military Hospital of southern region, Jizan, KSA

⁴King Khalid University, Aseer, KSA

Received: 05 April 2021

Accepted: 21 April 2021

***Correspondence:**

Dr. Radeif Shamakhi,

E-mail: Radeif@outlook.com

Copyright: © the author(s), publisher and licensee Medip Academy. This is an open-access article distributed under the terms of the Creative Commons Attribution Non-Commercial License, which permits unrestricted non-commercial use, distribution, and reproduction in any medium, provided the original work is properly cited.

ABSTRACT

Background: The aim of this study was to demonstrate the prevalence of anatomic variations of frontal sinus in people of southern region in Saudi Arabia.

Methods: This study used a retrospective radiological design to analyze computed tomography scans of 117 patients aged between 18 and 80 years of southern region in Saudi Arabia were used in this study. Patients with altered anatomy (iatrogenic or pathological) were excluded, CT scans were analyzed to demonstrate the incidence of anatomic variations of frontal sinus in people of southern region in Saudi Arabia.

Results: The study included 117 patients, 75 of whom were males (64%) and 42 of whom were females (36%) with ages ranging from 18 to 80 years. The prevalence of bilateral frontal sinus aplasia is 5.9 % and 3.4% is in the unilateral frontal sinus.

Conclusions: These figures on frontal sinus aplasia are critical in convincing surgeons to perform a preoperative CT scan of the paranasal sinuses and concentrate on the appearance of frontal sinuses on CT images to avoid unwanted complications during sinus surgeries.

Keywords: Frontal sinus aplasia, Computed tomography, Unilateral aplasia, Bilateral aplasia

INTRODUCTION

The paranasal sinuses play a significant role in helping to protect the vital structures in the case of facial trauma, humidifying and warming inhaled air, lowering the relative weight of the skull and developing the voice resonance.^{1,2} These paired paranasal sinuses are the frontal, maxillary, ethmoid, and the sphenoid sinus differs from each other by their development process and their final shape.³ The ethmoid sinus and the maxillary sinus are developed around the third month of gestation and both sinuses are present at birth. Alternatively, The pneumatization of both the sphenoid sinus and the frontal sinus occur after birth.^{4,5} By 5 years of age, the sphenoid is

pneumatized, while the frontal sinus is Not formed fully before late adolescence.⁶

The frontal sinus is one of the major paranasal sinuses that located behind the superciliary arch within the frontal bone.⁷ A bone septum, which is rarely situated in the midline, completely separates the two irregularly shaped frontal sinuses.^{8,9} The precise drainage system of the frontal sinus is based on its embryological development.¹⁰ The Frontal sinus opens through the frontonasal recess into the middle meatus and will drain medial to uncinata (88%) and lateral to uncinata (12%) processes depending on the connection of the uncinata method.¹¹ Among the paranasal sinuses, Frontal sinuses is the most challenging sinus is

because of its complex anatomy and close proximity to adjacent critical Structures.¹²

The surgeons, should be aware of the normal anatomy of frontal sinus and its variations to understand the disease, its spread, and for the safe surgical outcomes.

The aim of this study was to demonstrate the prevalence of anatomic variations of frontal sinus in people of southern region in Saudi Arabia.

METHODS

This retrospective study consists of 117 patients including both sexes with ages ranged from 18 to 80 years who were referred for paranasal sinuses CT scan from the department of otorhinolaryngology at Aseer central hospital. The data was collected during the period between January 2018 and January 2020. The images were obtained in coronal and axial sections with a 3 mm thickness. Using both the soft part window and the bony density window, anatomical variations of frontal sinuses were investigated. The absence of frontal bone pneumatization along a line drawn tangential to the supraorbital margin was aplasia of the frontal sinus.

Inclusion criteria

The patients with nasal obstruction, DNS and nasal polyposis.

Exclusion criteria

Pregnant women and younger than 18 years were excluded from the study. Patients with a history of skull base trauma that impair visualization of the frontal sinus. CT scans with fibro-osseous lesions that impaired the visualization of the frontal sinus.

Sampling technique and statistical analysis

All CT scan of patients recorded regarding their DNS and CB. All statistical analyses were performed using SPSS for Windows software (ver. 18.0; SPSS, Inc., Chicago, IL, USA). The significance of associations was tested using chi-square or Fischer exact tests. P values<0.05 were considered to indicate statistical significance.

RESULT

The study included 117 patients, 75 of whom were males (64%) and 42 of whom were females (36%) with ages ranging from 18 to 80 years. The prevalence of bilateral frontal sinus aplasia is 5.9% among Saudi individuals and 3.4% is the prevalence of unilateral frontal sinus. The bilateral frontal sinus aplasia is more common in males as we can notice in the tables where the prevalence of bilateral frontal sinus aplasia is 4.2% in males and 1.7% in females while same prevalence in unilateral sinus aplasia, 1.7% in males and 1.7% in

females. Moreover, the prevalence of left side frontal aplasia is 25% while the prevalence of right-side frontal aplasia is 75% in Unilateral frontal aplasia.

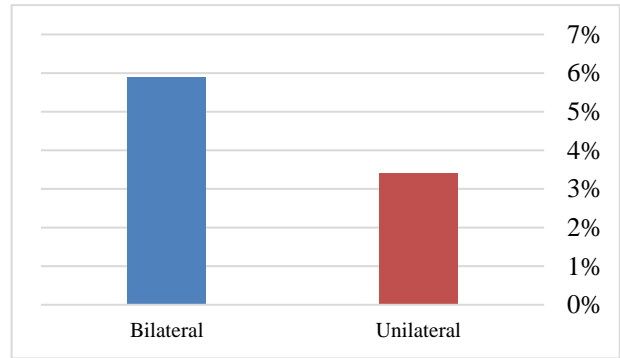


Figure 1: Distribution of frontal sinus aplasia.

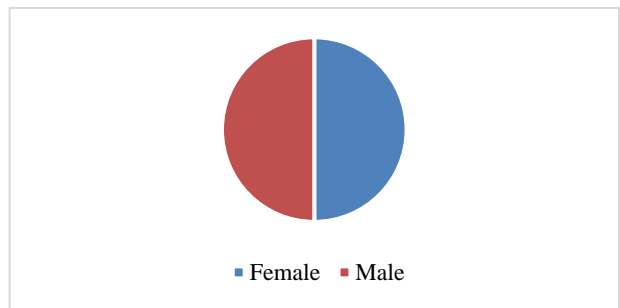


Figure 2: Distribution of unilateral frontal sinus aplasia.

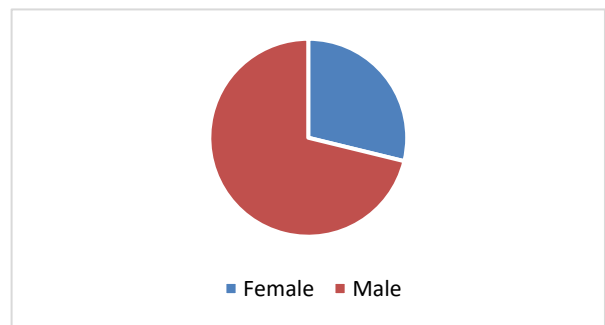


Figure 3: Distribution of bilateral frontal sinus aplasia.

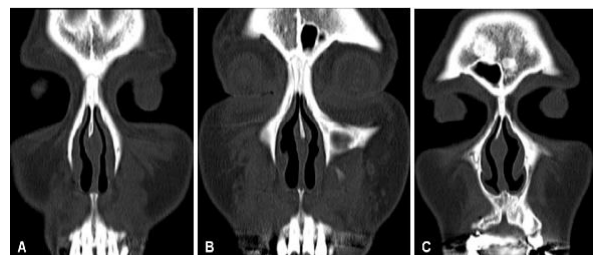


Figure 4: Coronal computed tomography image of the paranasal sinuses. The image shows bilateral frontal (A) sinus aplasia, (B) right frontal sinus aplasia, and (C) left frontal sinus aplasia.

DISCUSSION

In the 20th century, Schuller was the first to propose that this variation be developed with the aim of using it to identify unknown deceased people.¹³ Frontal sinuses, like fingerprints, may be distinguished from one another even in monozygotic twins.¹⁴

The incidence of bilateral frontal sinus aplasia varies by population and ranges from 3% to 10%.¹⁵ However, in a few populations as Alaskan Eskimos and Canadian Eskimos, the frequencies are higher than usual, where it reaches 25% and 43%, respectively among Alaskan Eskimos male and Canadian Eskimos male. While it reaches 36% among Alaskan Eskimos female and 40% among Canadian Eskimos female.^{16,17}

In our research, right frontal unilateral aplasia was more prevalent than left frontal unilateral aplasia, with 75 percent in the right and 25 percent in the left. Preoperatively, precise identification of the frontal sinus among multiplanar CT scans is essential in order to reduce the risk of complications during endoscopic sinus surgery. So, it is one of the disaster steps in endoscopic sinus surgery is to open no existing frontal sinus. That is why in this study we focused on the prevalence of frontal sinus aplasia to give the surgeon numbers that cannot be ignored to keep them alert preoperatively to depend on the radiological evaluation to assess the existence of frontal sinus. Moreover, frontal sinuses may act as a shock absorber against traumatic brain injury.

Accordingly, patients with frontal sinus aplasia are at increased risk of traumatic brain injury. A study by Pajic et al reported that the impact-induced stress distribution and fracture pattern in the frontal region highly depend on the volume of the frontal sinus cavities. Frontal sinuses that are well-developed can help with survival by acting as 'shock absorber' that protect surrounding vital structures and intracranial contents.¹⁸

According to Yu et al, the volume of the frontal sinuses was 33% lower in patients with a brain contusion compared to patients without a brain contusion, indicating that the frontal sinuses have a protective advantage against frontal brain contusion.¹⁹

CONCLUSION

The prevalence of frontal sinus aplasia among individual of southern region in Saudi Arabia is almost near the same values among different populations. These figures on frontal sinus aplasia are critical in convincing surgeons to perform a preoperative CT scan of the paranasal sinuses and concentrate on the appearance of frontal sinuses on CT images to avoid unwanted complications during sinus surgeries.

ACKNOWLEDGEMENTS

Authors would like to thank all doctors and technicians in radiology department in Aseer central hospital.

Funding: No funding sources

Conflict of interest: None declared

Ethical approval: The study was approved by the Institutional Ethics Committee

REFERENCES

1. Blanton PL, Biggs NL. Eighteen hundred years of controversy: the paranasal sinuses. *Am J Anat.* 1969;124(2):135-47.
2. Danesh SSA, Bavandi R, Esmaili M. Frontal sinus agenesis using computed tomography. *J Craniofac Surg.* 2011;22(6):48-510.
3. Christensen AM, Hatch GM. Advances in the use of frontal sinuses for human identification. In: Latham K, Bartelink E, Finnegan M, eds. *New Perspectives in Forensic Human Skeletal Identification.* 1st ed. Elsevier; 2017: 227-240.
4. Spaeth J, Krügelstein U, Schlöndorff G. The paranasal sinuses in CT-imaging: development from birth to age 25. *Int J Pediatr Otorhinolaryngol.* 1997;39(1):25-40.
5. Balas AHI, Nuseir A, Alzoubi F, Alomari A, Bani AM, Almehzaa S, et al. Prevalence of Frontal Sinus Aplasia in Jordanian Individuals. *J Craniofac Surg.* 2020;31(7):2040-2.
6. Scuderi AJ, Harnsberger HR, Boyer RS. Pneumatization of the paranasal sinuses: normal features of importance to the accurate interpretation of CT scans and MR images. *AJR Am J Roentgenol.* 1993;160(5):1101-4.
7. Reichs KJ. Quantified comparison of frontal sinus patterns by means of computed tomography. *Forensic Sci Int.* 1993;61(2-3):141-68.
8. Manolidis S, Hollier LH. Management of frontal sinus fractures. *Plast Reconstr Surg.* 2007;120(7):32-48.
9. Clemente MP. Surgical anatomy of the paranasal sinus. *Sinus Surg Endosc Microsc approaches.* 2005;27-58.
10. Ledderose GJ, Betz CS, Stelter K, Leunig A. Surgical management of osteomas of the frontal recess and sinus: extending the limits of the endoscopic approach. *Eur Arch Otorhinolaryngol.* 2011;268(4):525-32.
11. Landsberg R, Friedman M. A computer-assisted anatomical study of the nasofrontal region. *Laryngoscope.* 2001;111(12):2125-30.
12. Huang BY, Lloyd KM, DelGaudio JM, Jablonowski E, Hudgins PA. Failed endoscopic sinus surgery: spectrum of CT findings in the frontal recess. *Radiographics.* 2009;29(1):177-95.
13. Briscoe DR, Schuler RS. *International Human Resource Management: Policy and Practice for the Global Enterprise.* Psychology Press; 2004.

14. Patil N, Karjodkar FR, Sontakke S, Sansare K, Salvi R. Uniqueness of radiographic patterns of the frontal sinus for personal identification. *Imaging Sci Dent*. 2012;42(4):213-7.
15. Aydinlioglu A, Kavakli A, Erdem S. Absence of frontal sinus in Turkish individuals. *Yonsei Med J*. 2003;44(2):215-8.
16. Hanson CL, Owsley DW. Frontal sinus size in Eskimo populations. *Am J Phys Anthropol*. 1980;53(2):251-5.
17. Koertvelyessy T. Relationships between the frontal sinus and climatic conditions: a skeletal approach to cold adaptation. *Am J Phys Anthropol*. 1972;37(2):161-72.
18. Pajic SS, Antic S, Vukicevic AM, Djordjevic N, Jovicic G, Savic Z, et al. Trauma of the Frontal Region Is Influenced by the Volume of Frontal Sinuses. A Finite Element Study. *Front Physiol*. 2017;8:493.
19. Yu JL, Branstetter BF 4th, Snyderman CH. Frontal sinus volume predicts incidence of brain contusion in patients with head trauma. *J Trauma Acute Care Surg*. 2014;76(2):488-92.

Cite this article as: Shamakhi R, Mubarak M, Dighriri R, Almarir A, Alyahya A. Aplasia and agenesis of the frontal sinus in individual of southern region in Saudi Arabia. *Int J Otorhinolaryngol Head Neck Surg* 2021;7:821-4.