

Original Research Article

Role of pre-operative air-bone gap in outcome in tinnitus after undergoing type-1 tympanoplasty in patients with chronic suppurative otitis media

Manit M. Mandal*, Ajay K. Panchal, Rakesh Kumar, Parth B. Kapadia

Department of Otorhinolaryngology, SMIMER, Surat, Gujarat, India

Received: 07 April 2021

Revised: 07 May 2021

Accepted: 11 May 2021

***Correspondence:**

Dr. Mani M. Mandal,

E-mail: drmanit28@gmail.com

Copyright: © the author(s), publisher and licensee Medip Academy. This is an open-access article distributed under the terms of the Creative Commons Attribution Non-Commercial License, which permits unrestricted non-commercial use, distribution, and reproduction in any medium, provided the original work is properly cited.

ABSTRACT

Background: Researches suggest middle ear surgery might improve tinnitus after tympanoplasty. Purpose of this study was to investigate association between pre-operative air-bone gap (ABG) and tinnitus-outcome after tympanoplasty type I.

Methods: 100 patients with tinnitus having more than 6 months of symptoms of chronic suppurative otitis media (CSOM) that were refractory to medical treatment were included in study. All patients were evaluated through otoendoscopy, pure-tone audiometry, questionnaire-based survey using the visual analogue scale (VAS) and tinnitus handicap inventory (THI) for tinnitus symptoms before and 4 months after tympanoplasty. Influence of preoperative bone conduction (BC), preoperative air-bone-gap and postoperative air-bone-gap on tinnitus outcome post-operatively was calculated.

Results: Patients were divided into two groups based on preoperative BC of <25 dB or >25 dB. Postoperative improvement of tinnitus in both groups showed statistical significance. Patients whose preoperative air-bone-gap was <15 dB showed no improvement in postoperative tinnitus using VAS ($p=0.887$) and THI ($p=0.801$). Patients whose preoperative air-bone-gap was >15 dB showed significant improvement in postoperative tinnitus using VAS ($p<0.01$) and THI ($p=0.015$). Postoperative change in tinnitus showed significance compared with preoperative tinnitus using VAS ($p=0.006$). Correlation between reduction in VAS score and air-bone-gap ($p=0.201$) or between reduction in THI score and air-bone-gap ($p=0.270$) was not significant.

Conclusions: Preoperative ABG can be a predictor of tinnitus outcome after tympanoplasty in CSOM with tinnitus.

Keywords: Tinnitus, CSOM, Tympanoplasty, Interlay technique

INTRODUCTION

Tinnitus is the perception of sound in the ears which often is perceived in many forms such as ringing, roaring, buzzing, hissing, and others. Literature mentions various theories but despite thorough and extensive research, the cause of tinnitus is yet to be determined. The prevalence of tinnitus is significantly higher among hearing-impaired persons than in the normal-hearing population.¹ Surveys

have revealed that while 10-15% of the adult population as a whole suffers from tinnitus, as many as 70%-85% of the hearing-impaired population report tinnitus.^{1,2}

A temporary or permanent decrease in auditory stimuli (sensory deficit) increases the sensitivity of subcortical neurons, which results in the plastic reorganization of the auditory cortex, with subsequent sustained awareness of tinnitus.³ Studies on plasticity have also suggested that an increase in the auditory stimulus provided by external

sound amplification through the masking effect can induce secondary plasticity, helping to decrease the discomfort associated with tinnitus.⁴ There is a significant correlation between tinnitus and hearing loss in 85-96%.⁵ Therefore, attenuation of tinnitus may be achieved by restoration of hearing by surgery or amplification by hearing aid.

Tinnitus is a common often-associated problem in patients with CSOM.^{6,7} Since the time, the effect of tympanoplasty on tinnitus had been suggested by Helm for the first time, there have been few studies to date investigating tinnitus outcomes after middle ear surgery for chronic simple otitis media with tinnitus.⁶⁻⁹ Previous reports indicated that middle ear surgery might partially improve tinnitus after surgery. However, until now, no influencing factor has been determined for tinnitus outcome after middle ear surgery. The purpose of this study was to investigate the association between preoperative ABG and tinnitus outcome after tympanoplasty type I.

METHODS

This retrospective study was conducted in patients with CSOM (tubotympanic) with subjective tinnitus on the ipsilateral side who underwent tympanoplasty type I under general anaesthesia with the same technique (Interlay) using temporalis fascia in the department of otorhinolaryngology (ENT), Surat municipal institute of medical education and research (SMIMER), Surat, during the period October 2018 to October 2020. This study was approved by the institutional review board. Cases were selected by simple random sampling. In total, 100 patients with tinnitus who had more than 6 months of symptoms of CSOM on the ipsilateral side that were refractory to medical treatment are willing for surgery were included in the study. They were followed up for at least 4 months post-operatively. An intact epithelized neotympanic membrane without retraction or lateralization was considered a success. All patients were evaluated through otoendoscopy, pure tone/speech audiometer, questionnaire-based survey using VAS and THI for tinnitus symptoms before and 4 months after tympanoplasty.

For VAS, we asked patients to assign a 0-10 score to their tinnitus, with the help of a standard scale commonly used for indicating pain level. The assessment focused on two major aspects - the intensity and disturbance. VAS is easily applicable and understood by most patients. THI strengthens the evaluation of the functional, emotional, and catastrophic reactions to tinnitus. Audiological

evaluation by pure tone audiometry was conducted prior to tympanoplasty and 4 months after surgery. The pure tone average (PTA) and ABG at 0.5, 1, 2, and 4 kHz were evaluated. Subjective attenuation of tinnitus in 100 patients was investigated before and after type I tympanoplasty. Influence of pre-operative BC, preoperative ABG, and postoperative air-bone-gap on tinnitus outcome after the operation was investigated. Statistical analyses were performed by paired t test and Pearson correlation test using SPSS software.

RESULTS

Most patients enrolled for the study belonged to the age group 21-30 years, with sex distribution of 41 women and 59 men. CSOM with tinnitus was either right sided (56 cases) or left sided (44 cases) (Table 1). The mean duration of tinnitus was 25.55 months. The relationship between preoperative BC level and improvement of tinnitus was evaluated by VAS. The patients were divided into two groups-based VAS on preoperative BC of less than 25 dB (n=50) or more than 25 dB (n=50). The postoperative improvement of tinnitus in both groups showed statistical significance (Table 2). The relationship between preoperative ABG and improvement of tinnitus showed different results depending on the degree of preoperative ABG (less or more than 15 dB). The subjective improvement was examined by VAS and THI. Patients whose preoperative ABG was less than 15 dB showed no improvement in postoperative tinnitus using VAS (p=0.887) and THI (p=0.801). However, patients whose preoperative ABG was more than 15 dB showed statistically significant improvement in postoperative tinnitus using VAS (p<0.01), and THI (p=0.015) (Table 3). The post-operative air conduction (AC) and BC thresholds were significantly improved (Table 4). Table 5 shows significant postoperative changes in ABG and tinnitus compared to preoperative status. In preoperative ABG of more than 15 dB group, 100 patients were evaluated for postoperative PTA. The mean preoperative ABG was 17.8 dB and mean postoperative ABG was 13.9 dB. The audiological outcome significantly improved (p<0.01). In addition, postoperative tinnitus showed significant improvement than preoperative tinnitus using VAS (p=0.006). However, the correlation between the reduction in VAS score and ABG or between reduction in THI score and ABG was not significant.

Table 1: Demography of patients.

Sex		Lesion site	
Female	Male	Right	Left
41	59	56	44

Table 2: Relationship between postoperative changes in tinnitus and preoperative BC status.

VAS	BC less than 25 dB, (n=50)			BC more than 25 dB, (n=50)		
	Pre-op mean±SD	Post-op mean±SD	P	Pre-op mean±SD	Post-op mean±SD	P
	2.7 (±1.4)	1.7 (±2.0)	0.008	3.7 (±2.3)	2.8 (±2.8)	0.015

Paired Student's t test. BC-bone conduction; VAS-visual analogue scale.

Table 3: Relationship between postoperative change in tinnitus and preoperative ABG status.

Variables	Group A, (n=31)			Group B, (n=69)		
	Pre-op mean±SD	Post-op mean±SD	P	Pre-op mean±SD	Post-op mean±SD	P
VAS	2.6 (±2.2)	2.9 (±3.4)	0.887	2.3 (±1.2)	1.9 (±2.0)	<0.01
THI	17.8 (±23.2)	21.0 (±29.9)	0.801	18.4 (±22.5)	9.8 (±16.9)	0.015

Group A, pre-operative ABG less than 15 dB; Group B, pre-operative ABG more than 15 dB. ABG-Air-bone gap; VAS-Visual analogue scale; THI-Tinnitus handicap inventory. Paired student's t test.

Table 4: Pre-operative and post-operative change of AC, BC, (n=100).

Variables	Pre-op (dB)	Post-op (dB)	P value
AC	39.2	32.6	<0.01
BC	21.2	18.2	0.001

Paired Student's t test. AC-Air conduction; BC-Bone conduction.

Table 5: Relationship between pre-operative and post-operative ABG and change in tinnitus.

Variables	Pre-op	Post-op	P value
ABG	17.8	13.9	<0.01
VAS	3.0	2.1	0.006

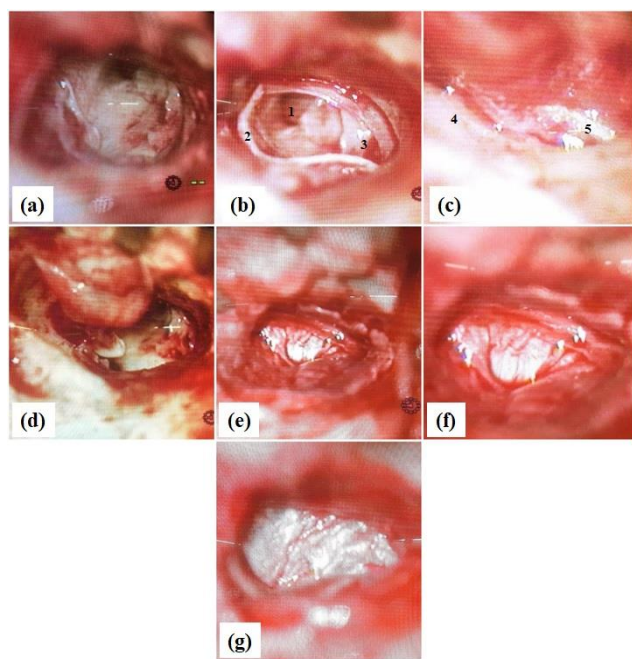


Figure 1: Intra-operative images (type 11 tympanoplasty with interlay technique), (A) Large central perforation after tympanomeatal flap elevation circumferentially, (B) Post flap elevation-1) Eustachian tube 2) Annulus, 3) Mucosal layer of tympanic membrane, (C) Post flap elevation-4) Annulus, 5) Mucosal layer of tympanic membrane, (D) Superiorly based tympanomeatal flap on circumferential elevation, (E) Annulus positioned during interlay technique, (F) Graft kept medial to handle of malleus by interlay technique and then tympanomeatal flap repositioned supporting it, (G) Graft placed by interlay technique.

DISCUSSION

Subjective tinnitus is more common than objective tinnitus. It may be caused by an abnormal condition in the cochlea, cochlear nerve, ascending auditory pathway, or auditory cortex.¹⁰

Any reversible otological factor including CSOM is strongly advocated to be treated. Since the time Helms had suggested that the subjective tinnitus symptoms might be reduced after middle ear surgery in CSOM with tinnitus, there have been few studies that have shown the subjective improvement of tinnitus after middle ear surgery.^{7,9,11-14} These results varied depending upon the type of surgery or pathological status of the middle ear. In our study, we studied the relationship between the change in subjective tinnitus and type-1 tympanoplasty. Our results showed an improvement in the complaint of tinnitus after type-1 tympanoplasty similar to other studies. Kim et al reported that the mean improvement of the AC average correlated with the improvement in tinnitus significantly, but ABG or BC average showed no significant change in tinnitus.⁹ However, our results were not similar to that of Kim et al.⁹ In our study, tinnitus improved after the surgery regardless of the preoperative BC level of more or less than 25 dB. The relationship between postoperative improvement in ABG and reduction in tinnitus showed significance. However, the preoperative ABG of less than 15 dB showed no improvement in tinnitus. When the preoperative ABG was more than 15 dB, tympanoplasty was effective in improving tinnitus. This was not similar to Lima et al report that hearing loss discomfort was greater than that caused by tinnitus in all the time points considered. In the present study, the patient whose preoperative ABG of less than 15 dB complained tinnitus mainly than hearing loss in the preoperative history taking.⁷ A previous report showed that tympanoplasty usually improved tonal threshold and led to favorable tinnitus results by restoration of middle ear mechanics.¹⁵ However, tympanoplasty is not effective for improvement of tinnitus in the preoperative milder hearing loss group (ABG less than 15 dB). Our results indicate that the possibility of improvement of tinnitus after tympanoplasty to be very low in COM with mild hearing loss (less than preoperative ABG 15 dB). Therefore, patients with COM with milder hearing loss may be recommended for tinnitus treatment using sound therapy or other methods after surgery during the preoperative interview. Also have opinion that patients with milder

hearing loss do not feel a significant subjective hearing gain after tympanoplasty. One possible reason could be that with milder hearing losses, tinnitus may create more problems in daily life compared to hearing loss.¹⁶

Del Bo et al suggested two mechanisms for how tinnitus can be improved by hearing restoration.⁴ First, an increased level of ambient noise perceived after hearing restoration induces partial or complete masking of tinnitus, and second, the changes in the auditory nervous system caused by the deprivation of stimulus can be reversed by appropriate sound stimulation. Improvement in tinnitus after tympanoplasty has been reported positively in the literature. Lima et al showed that 83% of 23 patients, and Baba et al. showed that 55% of 324 patients showed improvement in tinnitus after surgery, but the previous reports did not investigate deeply the possible relationship between tinnitus and hearing.⁷ Recently, Kim et al reported that restoration of AC threshold was one of the most important factors contributing to the improvement of tinnitus.⁸ In the present study, preoperative ABG is an important predictor of tinnitus outcome after tympanoplasty. To the best of our knowledge, we have determined the role of preoperative ABG as a predictor for tinnitus outcome after tympanoplasty for the first time. Although there is a reduction in ABG by improved AC threshold after surgery, if the preoperative ABG is less than 15 dB, the patient cannot feel the attenuation of tinnitus. In the present study, although tinnitus was improved by a postoperative hearing gain in patients whose preoperative ABG was more than 15 dB, the correlation between the reduction in VAS or THI scores after operation and hearing improvement was not statistically significant. This was similar to previous reports.^{7,9} Kim et al explained that the reason behind the insignificant correlation between the improvement in tinnitus and hearing improvement was due to multi-factorial causes of tinnitus including emotional stability after tympanoplasty.⁹ The limitation of this study is the small sample size and retrospective design.

CONCLUSION

We suggest that the preoperative ABG can be a predictor of tinnitus outcome after tympanoplasty in COM with tinnitus on the basis of our study. Hence, this can be a powerful guide that can help the ENT surgeon explain the prognosis and outcome expectations to his/her patients. It also benefits the surgeon to consider and offer alternative options other than surgery to the patients to match their expectations with the surgery.

Funding: No funding sources

Conflict of interest: None declared

Ethical approval: The study was approved by the Institutional Ethics Committee

REFERENCES

1. Seidman MD, Standring RT, Dornhoffer JL. Tinnitus: current understanding and contemporary management. *Curr Opin Otolaryngol Head Neck Surg.* 2010;18:363-8.
2. Henry JA, Dennis KC, Schechter MA. General review of tinnitus: prevalence, mechanisms, effects, and management. *J Speech Lang Hear Res.* 2005;48:1204-35.
3. Eggermont JJ, Roberts LE. The neuroscience of tinnitus. *Trends Neurosci.* 2004;27:672-82.
4. Del Bo L, Ambrosetti U. Hearing aids for the treatment of tinnitus. *Prog Brain Res.* 2007;166:341-5.
5. Jastreboff PJ. Phantom auditory perception (tinnitus): mechanisms of generation and perception. *Neurosci Res.* 1990;8:221-54.
6. Baba S, Yagi T, Fujikura T. Subjective evaluation and overall satisfaction after tympanoplasty for chronic simple suppurative otitis media. *J Nippon Med Sch.* 2004;71:17-24.
7. Ada LS, Sanchez TG, Moraes BMF, Alves BSC, Bento RF. The effect of tympanoplasty on tinnitus in patients with conductive hearing loss: a 6 month follow-up. *Braz J Otorhinolaryngol.* 2007;73:384-9.
8. Helms J. Tympanoplasty and tinnitus. *Laryngol Rhinol Otol (Stuttg).* 1981;60:99-100.
9. Kim DK, Park SN, Kim MJ, Lee SY, Park KH, Yeo SW. Tinnitus in patients with chronic otitis media before and after middle ear surgery. *Eur Arch Otorhinolaryngol.* 2011;268:1443-8.
10. Scluning AJ, Martin WH. Tinnitus. In: Bailey BJ, Calhoun KH, Healy GB, Pillsbury HC, Johnson JT, Tardy ME, Jackler RK, editors. *Head and neck surgery-otolaryngology.* 3rd ed. Philadelphia, PA: Lippincott Williams and Wilkins; 2001;1925-31.
11. Habesoglu M, Habesoglu TE, Karatas C, Tosun A, Gursel AO. Is there any predictor for tinnitus outcome in different types of otologic surgery. *Eur Arch Otorhinolaryngol.* 2013;270:2225-9.
12. Lima JC, Marone SA, Martucci O, Gonzalez F, Silva Neto Gonzalez JJ et al. Evaluation of the organic and functional results of tympanoplasties through a retro-auricular approach at a medical residency unit. *Braz J Otorhinolaryngol.* 2011;77:229-36.
13. Kent DT, Kitsko DJ, Wine T, Chi DH. Frequency-specific hearing outcomes in pediatric type I tympanoplasty. *JAMA Otolaryngol Head Neck Surg.* 2014;140:106-11.
14. Okada M, Gyo K, Takagi T, Fujiwara T, Takahashi H, Hakuba N et al. Air-bone gap in ears with a well-repaired tympanic membrane after Type III and Type IV tympanoplasty. *Auris Nasus Larynx.* 2014;41:153-9.
15. Searchfield GD, Kaur M, Martin WH. Hearing aids as an adjunct to counselling: tinnitus patients who choose amplification do better than those that don't.

Int J Audiol. 2010;49:574-9.

16. Varitiainen E. The results of chronic ear surgery in training programme. Clin Otolaryngol. 1988;23:177-80.

Cite this article as: Mandal MM, Panchal AK, Kumar R, Kapadia PB. Role of pre-operative air-bone gap in outcome in tinnitus after undergoing type-1 tympanoplasty in patients with chronic suppurative otitis media. Int J Otorhinolaryngol Head Neck Surg 2021;7:963-7.