

Case Report

Retrosternal goitre: a diagnostic quandary

Neeraj Kasliwal, Ashwath Kasliwal*, Anirudh Kasliwal

Department of Otolaryngology and Head and Neck Surgery, Dr. K.C. Kasliwal's Ear, Nose and Throat Centre, Jaipur, Rajasthan, India

Received: 17 March 2021

Accepted: 17 April 2021

*Correspondence:

Dr. Ashwath Kasliwal,

E-mail: ashwath_kasliwal@hotmail.com

Copyright: © the author(s), publisher and licensee Medip Academy. This is an open-access article distributed under the terms of the Creative Commons Attribution Non-Commercial License, which permits unrestricted non-commercial

ABSTRACT

Retrosternal goitre is usually referred to enlarged thyroid gland with more than 50% of its mass below the thoracic inlet. It has clinical importance because it may cause compression of the major vessels in the neck. In this article we are reporting a case of 51-year-old female who came to the otolaryngology clinic with slight dyspnoea on exertion for 3 years. She was an elderly female, obese, with a short broad neck with no obvious swelling in the neck. Surgical resection of the mass with either isolated neck incision or neck incision/sternotomy remains the treatment of choice.

Keywords: Goitre, Thyroidectomy, Retrosternal, Substernal

INTRODUCTION

Retrosternal goitre is defined as thyroid gland with more than 50 percent of its mass below the thoracic inlet.¹ This is a rare condition accounting for 5-20% of thyroidectomy patients. It is associated with slow progression and longer course of illness. The majority of retrosternal goitres arise from the caudal migration of cervical goitres which is attributed to multiple factors such as negative intrathoracic pressure repetitive deglutition, effect of gravity and a large potential space in the mediastinum. In this study, a 51-year-old female, euthyroid, was incidentally found to have multinodular goitre with large retrosternal extension. The mass was removed surgically with combined cervical and sternotomy approach.

CASE REPORT

A 51-year-old female came to the otolaryngology outpatient department for slight dyspnoea on exertion since, 3 years. On evaluation, the ear, nose and throat examination were. Indirect laryngoscopy was normal. On auscultation, there was reduced breath sounds on left lung. She was an elderly female, obese, with a short broad neck with no obvious swelling in the neck.

A chest X-ray was done which showed widening of the mediastinum.

On CT, there was an asymmetrical enlargement of the left thyroid lobe with a retrosternal extension of the left thyroid nodule. Retrosternal component measured approximately 10×4.5 cm. Cervical component of the left lobe measured 61×23 mm, right lobe 41×17 mm and isthmus 6.5 mm.

Small enhancing cystic lesion of size 11×11 mm seen in sub hyoid region in midline, also extending in pre epiglottic fat space, suggestive of thyroglossal duct cyst.

After proper written informed consent, she underwent total thyroidectomy with nodal dissection with sternotomy for removal of the retrosternal extension under general anaesthesia. During surgery the right lobe of thyroid measured 5x4x2 cm, pyramidal lobe – 2×0.5×0.5 cm and left lobe 8×7×5 cm and the cervical thyroid was connected with the retrosternal extension with a fibrous band (thyroid rest grade 3).

Histopathological report was suggestive of multinodular adenomatous hyperplasia with unremarkable thymic rest, and lymph node showed non-specific reactive lymphadenitis with no evidence of granuloma or malignancy.

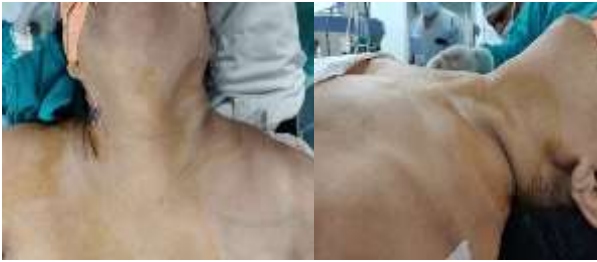

Figure 1: Preoperative pictures with no obvious neck swelling.

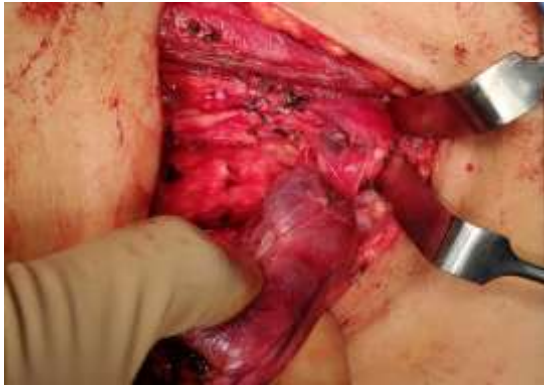

Figure 2: Cervical thyroid with fibrous band (thyro-thymic thyroid rest).

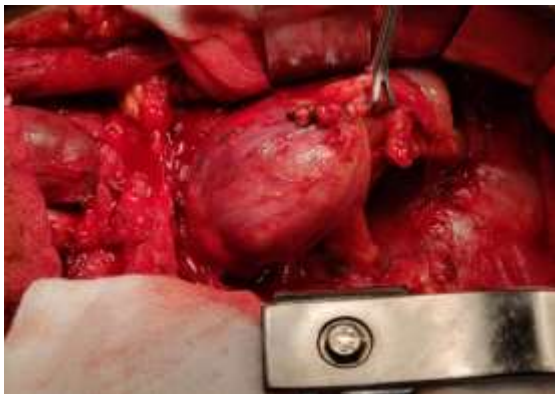


Figure 3: Mediastinal extension of the goitre.

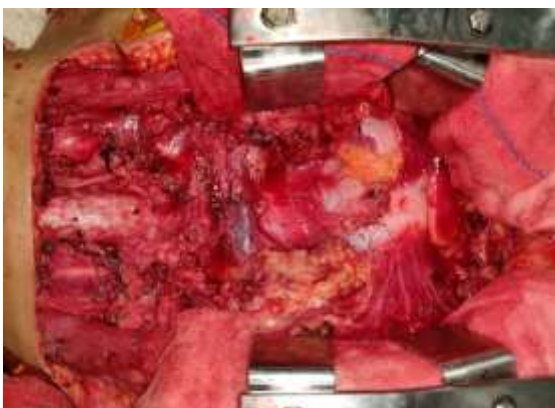

Figure 4: After complete removal of the goitre.

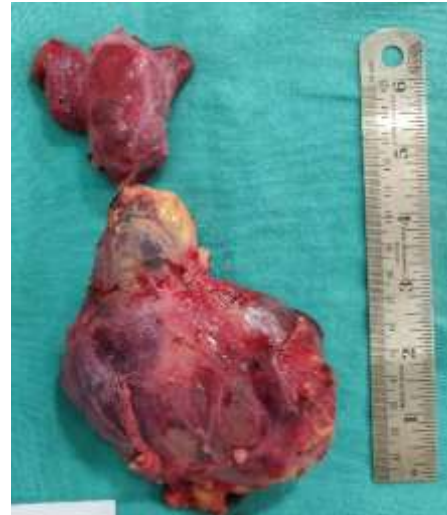

Figure 5: Specimen of the whole thyroid gland after complete resection of both neck and mediastinal parts.

DISCUSSION

The extension of the thyroid gland from its original position into the mediastinum poses a unique challenge for the surgeons. This leads to anatomical distortion; restricted surgical access of the thoracic inlet and unpredictable vascularity can make retrosternal goitre surgery challenging and technically demanding.

The word goitre arises from the Latin word ‘tumidium gutter’ meaning swollen throat and the definition of retrosternal goitre is even less clear.² Kocher defined a substernal thyroid gland as a gland in which some portion of the gland remain permanently retrosternal whereas Crile defined it as thyroid growth below the arch of aorta.³ In addition, multiple authors provided multiple classification but the most practical being from Randolph,⁴ classifying the substernal goitre according to its anatomical relationship into 3 types: (a) type 1- anterior mediastinum; (b) type 2- posterior mediastinum; (c) type 3- isolated mediastinal goitre.

The incidence of substernal goitre increases significantly with age with 60% of this condition occurring in patients older than 60 years.⁵ Most substernal goitre arise in a setting of a pre-existing cervical goitre, grow slowly and infrequently malignant. A female preponderance with female to male ratio 3:1.⁶ Most patients present with palpable neck mass, cough, hoarseness of voice, inspiratory stridor or shortness of breath.⁷ It is imperative to examine the vocal cords before surgery and a vocal cord palsy without previous surgery is suggestive of presence of invasive thyroid malignancy until proven otherwise. Patient should be asked to raise both arms above the neck to elicit the pemberton’s sign.

A CT-scan examination of the neck and the thorax is essential for not only assessment and surgical planning but also assists in anaesthesia provider’s intubation approach.

CT scan allows for safe operative management for large posterior mediastinum goitres and the potential need for sternotomy.

Though plain chest radiography provides a very limited information on the size and extent of substernal goitre, it is the most easily available modality to provide the first sign of this disease.

Surgery is the treatment of choice for retrosternal goitre and most cases can be done alone with a neck incision. The need for sternotomy or thoracotomy ranges between 0% to 13%, while others claim rate as high as 29%.^{8,9}

A total thyroidectomy should be carried out when both the lobes are involved with a sternotomy which should be performed with an experienced cardiothoracic surgery team in well-equipped centres.

CONCLUSION

The possibility of retrosternal goitre should be borne in mind in patients prior to being presented with pressure symptoms. The treating surgeon should be prepared for early diagnosis and surgical treatment of such masses to prevent pressure symptoms and morbidity to the patients.

Funding: No funding sources

Conflict of interest: None declared

Ethical approval: Not required

REFERENCES

1. Agha A, Glockzin G, Ghali N, Iesalnieks I, Schlitt HJ. Surgical treatment of substernal goiter: an analysis of 59 patients. Surg Today. 2008;38(6):505-11.
2. Huins CT, Georgalas C, Mehrzad H, Tolley NS. A new classification system for retrosternal goitre based on a systematic review of its complications and management. Int J Surg. 2008;6(1):71-6.
3. Crile GC. Intrathoracic Goiter. Cleve Clin quarterly 1939;6:313-22.
4. Randolph GW. Surgery of Cervical and Substernal goiter. In: Randolph GW, eds. Surgery of the thyroid and parathyroid. 3rd ed. Philadelphia, PA: W.B.Saunders; 2003: 70-99.
5. Reeve TS, Rubinstein C, Rundle FF. Intrathoracic goitre: its prevalence in Sydney metropolitan mass radiography surveys. Med J Aust. 1957;44(5):149-56.
6. Johnston JH, Twente GE. Surgical approach to intrathoracic (mediastinal) goiter. Ann Surg. 1956;143(5):572-9.
7. Rodriguez JM, Hernandez Q, Piñero A, Ortiz S, Soria T, Ramirez P, et al. Substernal goiter: clinical experience of 72 cases. Ann Otol Rhinol Laryngol. 1999;108(5):501-4.
8. Hall TS, Caslowitz P, Popper C, Smith GW. Substernal goiter versus intrathoracic aberrant thyroid: a critical difference. Ann Thorac Surg. 1988;46(6):684-5.
9. Singh B, Lucente FE, Shaha AR. Substernal goiter: a clinical review. Am J Otolaryngol. 1994;15(6):409-16.

Cite this article as: Kasliwal N, Kasliwal A, Kasliwal A. Retrosternal goitre: a diagnostic quandary. Int J Otorhinolaryngol Head Neck Surg 2021;7:909-11.