

## Case Series

# A case series of invasive mucormycosis in patients with COVID-19 infection

Neha Mishra<sup>1</sup>, Venkata Sai Shashank Mutya<sup>2\*</sup>, Alphonsa Thomas<sup>3</sup>,  
Girish Rai<sup>3</sup>, Bathi Reddy<sup>3</sup>, Anithakumari Alnipully Mohanan<sup>3</sup>, Shalina Ray<sup>3</sup>,  
Anand Vellore Thiruvengadem<sup>3</sup>, Vishwanath Siddini<sup>4</sup>, Raghuraj Hegde<sup>5</sup>

<sup>1</sup>Department of Infectious Disease, <sup>2</sup>Departement of General Medicine, <sup>3</sup>Department of Otorhinolaryngology,  
<sup>4</sup>Department Of Nephrology, <sup>5</sup>Department Of Ophthalmology, Manipal Hospital, Bangalore, India

**Received:** 14 March 2021

**Revised:** 18 April 2021

**Accepted:** 21 April 2021

### \*Correspondence:

Dr. Venkata Sai Shashank Mutya,  
E-mail: [sai291095@gmail.com](mailto:sai291095@gmail.com)

**Copyright:** © the author(s), publisher and licensee Medip Academy. This is an open-access article distributed under the terms of the Creative Commons Attribution Non-Commercial License, which permits unrestricted non-commercial use, distribution, and reproduction in any medium, provided the original work is properly cited.

## ABSTRACT

Rhino-orbital-cerebral mucormycosis is an invasive disease associated with high mortality ranging from 25-62%. There is an increase in the incidence of mucormycosis in post COVID-19 infection patients. We have come across 10 such patients. On retrospective analysis of the patient's records, we found that 60% patients had received steroids and majority had co-morbidities. All the patients received similar treatment with IV amphotericin B and local debridement and the mortality rate was as high as 44%. We conclude that patients with COVID 19 infection are susceptible to mucormycosis because of impairment of barrier defense, dysfunction phagocytes and lymphocytes and the use of immunosuppressive medications such as steroids and tocilizumab.

**Keywords:** COVID-19, Invasive mucomycosis, Amphotericin B, Steroids

## INTRODUCTION

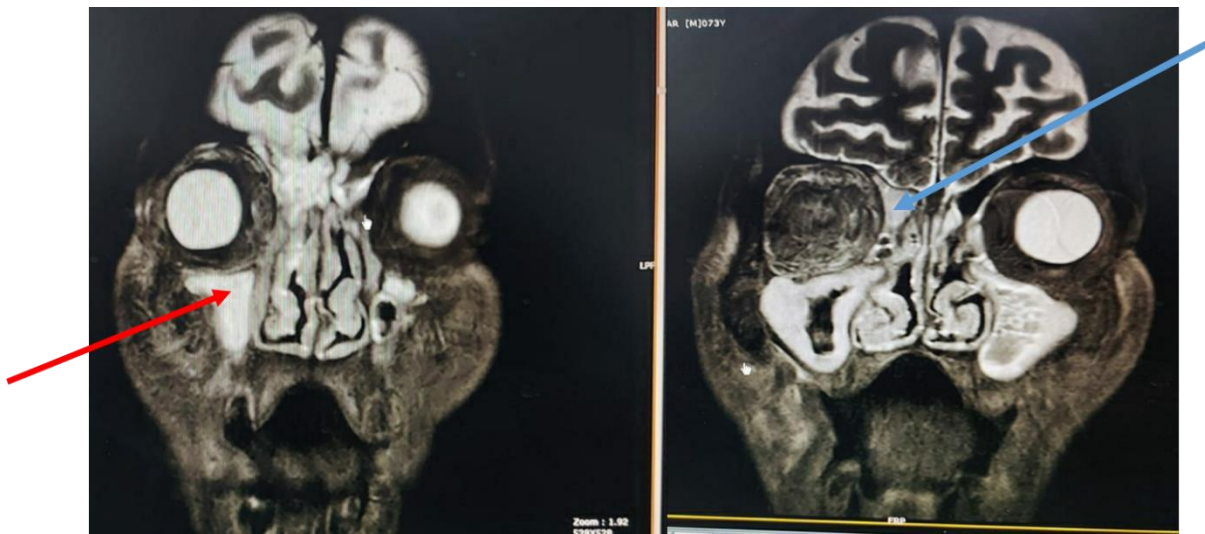
Zygomycetes comprises of mucorales and entomothorales. The former order causes life threatening fungal infections, mucormycosis mainly in immunocompromised hosts while the latter order causes superficial and mucocutaneous infections in immunocompetent hosts. Among *Mucoraceae*, *Rhizopus oryzae* is the most common cause of infection.<sup>1</sup> Phagocytes are the major host defense mechanism against mucormycosis.<sup>2,3</sup> Additionally, corticosteroid treatment affects the ability of macrophages to prevent the germination of the spores of these fungi. A hallmark of mucormycosis infection is the presence of extensive angioinvasion with resultant vessel thrombosis and tissue necrosis.<sup>4</sup>

In the current times there is a pandemic due to COVID-19. It is a nonsegmented negative sense RNA virus which causes profound lymphopenia. In later stages of infection, when viral replication accelerates, epithelial-endothelial barrier integrity is compromised and the inflammatory response and triggering an influx of monocytes and neutrophils is accentuated. Collectively, endothelial barrier disruption, dysfunctional alveolar-capillary oxygen transmission and impaired oxygen diffusion capacity are characteristic features of COVID-19.<sup>5</sup> Recently, we have noticed that there is an increase in the incidence of invasive mucormycosis infections in COVID-19 disease. We have come across 10 such cases and all the cases were found to have some similarities. Here we presented to you a case series of 10 cases.

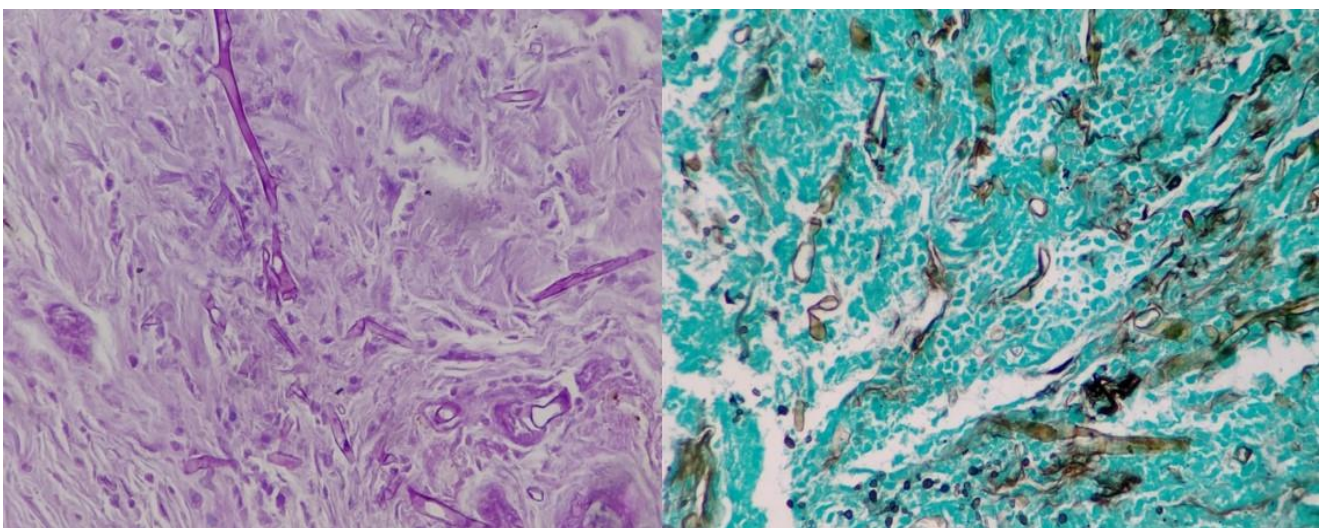
## CASE SERIES

We retrospectively reviewed patients with rhino-orbito-cerebral mucormycosis and COVID 19 infection admitted at our centre and managed by the departments of infectious diseases and otorhinolaryngology from August to December 2020. The medical records were retrieved and the demographic findings along with clinical, histopathological and radiological data were reviewed. 4 of the 10 patients were diagnosed and managed for COVID-19 at our hospital. Remaining (6 out of 10) were treated for COVID-19 at outside centers. Details of these patients are described in Table 1. Mucormycosis was diagnosed and treated for all the patients in our hospital. The mean age of our patients was 55.8 years (range 37 to 78 years), wherein 8 of the 10 patients were diabetic. Eye

pain, facial pain and nasal block were the presenting complaints. All the patients had imaging evidence in the form of CT PNS and MRI brain revealing mucosal thickening of sinuses and adjacent bony erosions (Figure 1 and 2). Orbital involvement was also seen in few cases. 6 of the 10 patients (60%) received steroids and one patient received tocilizumab for the management of COVID-19. Except one patient, others had underlying comorbidities like diabetes mellitus, hypertension and/or chronic kidney disease. Only one patient at presentation had severe COVID-19 disease, rest of the patients had mild and moderate disease. All the patients were treated similarly with adequate local debridement of the infected and necrotic tissue along with IV amphotericin B in addition to treatment of COVID-19 disease. One patient was lost to follow up and the overall mortality was 44.4% (4 of the 9).



**Figure 1: MRI picture of a patient showing involvement of the mucosal thickening and growth in the right maxillary (red arrow) and right ethmoidal sinus (blue arrow).**



**Figure 2: HPE of a patient showing aseptate hyphae with angioinvasion and Giemsa stain of the same showing black fungal elements in green background.**

**Table 1: Demographics and the clinical details of the patients with mucormycosis associated with COVID-19.**

Sr. No.	1	2	3	4	5	6	7	8	9	10
<b>Age (in years)</b>	38	73	77	51	37	43	56	78	56	49
<b>Sex</b>	Male	Male	Male	Female	Male	Male	Male	Male	Male	Male
<b>Comorbidities</b>	Diabetes	Diabetes	Diabetes, Hypertension and IHD	Diabetes, Hypothyroidism	Nil	Diabetes, CLD	CKD, diabetes, hypertension hypothyroidism	Diabetes, Hypertension	Diabetes	CKD
<b>Severity</b>	Mild	Moderate	Mild	Moderate	Severe	Moderate	Moderate	Moderate	Mild	Moderate
<b>Steroids</b>	No	No	No	Yes	Yes	Yes	Yes	Yes	No	Yes
<b>Remdesivir/tocilizumab</b>	No	Remdesivir	No	Remdesivir	Both	Remdesivir	Remdesivir	-	No	Remdesivir
<b>O<sub>2</sub> requirement</b>	No	No	No	Yes	Yes	Yes	No	-	No	Yes
<b>Presentation</b>	Right eye pain and chemosis	Chemosis with loss of vision in right eye	Epistaxis, loss of vision left eye	Left side facial pain and nose block	Pain and bleeding from gums	Dryness and crusting in nasal cavity	Right eye swelling	Holocranial headache	right eye pain and decreased vision	Impairment of right eye vision
<b>HPE and fungal smear (broad aseptate hyphae/angioinvasion)</b>	Yes	Yes	Yes	Yes	Yes	Yes	Yes	Yes	Yes	Yes
<b>Treatment</b>	Orbital exenteration and debridement of fungal sinusitis Conventional amphotericin B	Bilateral FESS, Liposomal Amphotericin B followed by Posaconazole	FESS, craniotomy, liposomal amphotericin B	FESS and local debridement, liposomal amphotericin B	FESS, liposomal Amphotericin B	FESS and local debridement, Conventional Amphotericin B	FESS and local debridement and Liposomal amphotericin B	FESS and local debridement and liposomal amphotericin B	FESS and orbital decompression	Endoscopic maxillectomy and ethmoidectomy and Liposomal Amphotericin B
<b>Radiological evidence</b>	Yes	Yes	Yes	Yes	Yes	Yes	Yes	Yes	Yes	Yes
<b>Clinical outcome</b>	Death	Improved	Death	Improved	Improved	Improved	Death	Death	Lost to follow up	Improved
CLD-chronic liver disease, FESS-functional endoscopic sinus surgery, CKD-chronic kidney disease										

## DISCUSSION

Our case series highlights the possibility of a correlation between COVID-19 and mucormycosis infections. We know from the pathogenesis of mucormycosis that mononuclear and polymorphonuclear phagocytes of normal hosts kill mucorales by generation of oxidative metabolites and defensins, hence neutropenic patients and those with dysfunctional phagocytes are susceptible to develop invasive mucormycosis.<sup>2,3</sup> In COVID-19 there is profound lymphopenia and in advanced infections viral replication accentuates the inflammatory response and neutrophil and monocyte influx in the blood stream.<sup>5</sup> This leads to an imbalance between neutrophil and lymphocyte action making the patient more susceptible to systemic fungal infections.

The hallmark recovery trail emphasized the use of steroids in reducing the need of invasive ventilation in hypoxic patients and the hospital stay and ultimately decreasing the mortality. Administration of steroids results in a neutrophilic leukocytosis and the impaired ability of leukocytes to migrate to the site of inflammation due to its inhibitory effects on cytokines and chemokines. Steroids are also known to cause lymphopenia (T more than B cells). Prolonged use of glucocorticoids is known to increase the risk of the patient to infections especially many opportunistic ones.<sup>6</sup> Recent published evidence say that COVID-19 is a pro-coagulable state and there is increased incidence of thrombotic events.<sup>5</sup> This pro-coagulable state provides a perfect ground for the angioinvasion of mucor invasion due to vessel thrombosis and leading to disseminated infections. A study published by Song G et al in they have investigated a total of 99 patients of fungal infections post COVID-19 in China have found out that about 5% of these are due to *Aspergillus* and 7% *Mucor* species. They have concluded that the impairment of T cell immunity along with presence of underlying immunocompromised state is one of the most important pathogenesis.<sup>7</sup> In a case report published by Mehta et al where they have reported a case of post COVID-19 rhino-orbital mucormycosis in which the patient received steroids according to the protocols after which he developed mucormycosis. According to their hypothesis it may be due to the alterations in the immunity especially T cells and innate immunity and the use of steroids may be the cause of invasive fungal infection post covid.<sup>8</sup> Similar observations have been reported by Amanda et al from America and by Chaudhary et al from Delhi.<sup>9,10</sup>

## CONCLUSION

We propose that, patients with COVID-19 infection are susceptible to mucormycosis because of impairment of barrier defense, dysfunction of phagocytes and

lymphocytes and the use of immunosuppressive medications such as steroids and tocilizumab. Treating clinicians need to be aware of the possibility of mucormycosis, in such patients particularly in those with underlying comorbidities. Early diagnosis and treatment of secondary fungal infections can substantially reduce morbidity and mortality.

*Funding: No funding sources*

*Conflict of interest: None declared*

*Ethical approval: Not required*

## REFERENCES

1. Ribes JC, Vanover-Sans CL. Zygomycetes in human disease. Clin Microbiol Rev. 2000;13(2):236-301.
2. Waldorf AR. Pulmonary defense mechanisms against opportunistic fungal pathogens. Immunol Ser. 1989;47:243-71.
3. Waldorf AR, Ruderman N, Diamond RD. Specific susceptibility to mucormycosis in murine diabetes and bronchoalveolar macrophage defense mechanisms against *Rhizopus*. J Clin Invest. 1984;74(1):150-60.
4. Bouchara JP, Oumeziane NA, Lissitzky JC, Larcher G, Tronchin G, Chabasse D. Attachment of spores of the human pathogenic fungus *Rhizopus oryzae* to extracellular matrix components. Eur J Cell Biol. 1996;70(1):76-83.
5. Wiersinga WJ, Rhodes A, Cheng AC, Peacock SJ, Prescott HC. Pathophysiology, transmission, diagnosis, and treatment of coronavirus disease 2019 (COVID-19): a review. JAMA. 2020;324(4):782-93.
6. Peter WH, Martin JL. Dexamethasone in hospitalised patients with COVID-19: preliminary report. N Eng J Med. 2020.
7. Song G, Liang G, Liu W. Fungal co-infections associated with global COVID-19 pandemic: a clinical and diagnostic perspective from China. Mycopathologia. 2020;185:599-26.
8. Mehta S, Pandey A. Rhino-orbital mucormycosis associated with COVID-19. Cureus. 2020;12(9):10726.
9. Werthman-Ehrenreich A. Mucormycosis with orbital compartment Syndrome in a patient with COVID-19. Am J Emerg Med. 2021;264:64-8.
10. Chowdhary A, Tarai B, Singh A, Sharma A. Multidrug-resistant *Candida auris* infections in critically ill coronavirus disease patients, India, April-July 2020. Emerg Infect Dis. 2020;26(11):2694-6.

**Cite this article as:** Mishra N, Mutya VSS, Thomas A, Rai G, Reddy B, Mohanan AA, et al. A case series of invasive mucormycosis in patients with COVID-19 infection. Int J Otorhinolaryngol Head Neck Surg 2021;7:867-70.