

Original Research Article

Extra pulmonary tuberculosis manifestation in head and neck and its diagnosis with recent tools like cartridge based nucleic acid amplification test

Richa Vatsyayan*, Kavita Sachdeva

Department of Otorhinolaryngology and Head-Neck Surgery, NSCB Medical College and Hospital, Jabalpur, Madhya Pradesh, India

Received: 24 February 2021

Accepted: 05 April 2021

*Correspondence:

Dr. Richa Vatsyayan,

E-mail: dr.richavatsyayan@gmail.com

Copyright: © the author(s), publisher and licensee Medip Academy. This is an open-access article distributed under the terms of the Creative Commons Attribution Non-Commercial License, which permits unrestricted non-commercial use, distribution, and reproduction in any medium, provided the original work is properly cited.

ABSTRACT

Background: The study aimed to assess the clinical manifestations of extra-pulmonary tuberculosis (head and neck) in diagnosed pulmonary tuberculosis (TB) patients and without pulmonary TB and to determine the sensitivity and specificity of cartridge based nucleic acid amplification test (CBNAAT) in the diagnosis of extra-pulmonary TB.

Methods: The study was conducted as an observational study at the Department of Otorhinolaryngology, tertiary care center, Jabalpur (Madhya Pradesh) for a period of 18 months i.e. from 01 March 2019 to 31 August 2020 on 30 patients presenting with lesions in ear, nose and throat (ENT), head and neck region. All necessary investigations with TB workup were done. Sputum samples were analyzed by CBNAAT on Xpert- *Mycobacterium tuberculosis* complex/resistance to rifampin (MTB/RIF). Patients were treated accordingly. Appropriate surgical intervention was done in necessary cases. Using statistical analysis, the sensitivity, specificity, positive predictive value (PPV), negative predictive value (NPV), and diagnostic accuracy was calculated for CBNAAT.

Results: Neck swelling and ear discharge were the most common features observed in 66.7% of cases. In cases with pulmonary TB, systemic features were the most predominant features whereas in cases with extra-pulmonary TB, local features were predominant. Sensitivity, specificity, PPV and NPV of CBNAAT were documented to be 85%, 50%, 89.5% and 40% respectively.

Conclusions: TB of the head and neck are commonly encountered in clinical practice. The patients usually present with variable clinical manifestations depending upon the site of involvement. The middle ear is the most common site affected by head and neck tuberculosis. CBNAAT is a sensitive tool for the diagnosis of extra-pulmonary TB with and without associated pulmonary TB.

Keywords: Extra-pulmonary TB, CBNAAT, TB symptoms, Fine needle aspiration cytology

INTRODUCTION

Tuberculosis (TB), though the oldest known infectious disease remains the leading cause of death worldwide from a single infectious agent.¹ Primarily, it is a pulmonary disease, but it can manifest as extra-pulmonary TB. According to the World Health Organization (WHO), extra-pulmonary tuberculosis is classified as an infection caused by *Mycobacterium tuberculosis* that affects tissues and organs outside the pulmonary parenchyma.^{2,3} The

burden of extra-pulmonary TB is reported to range from 15-20% and 40-50% of all TB cases in human immunodeficiency virus (HIV)-negative and HIV-positive cases respectively in India.^{4,5} Among various extra-pulmonary TB, head and neck TB contributes to approximately 10-15% of cases.⁶

Head and neck TB includes laryngeal TB, ear TB, oral TB, oropharyngeal TB, sinonasal TB, salivary gland TB, cervical lymphadenitis, etc.⁷ The diagnosis of head and

neck tuberculosis is mainly based upon cytology and conventional smear microscopy in resource-poor settings.⁸ However, conventional smear microscopy has low sensitivity due to the paucibacillary nature of lesions. Though fine needle aspiration cytology (FNAC) is an important diagnostic tool for extra-pulmonary TB as it is a simple and rapid technique, it is associated with low specificity which may be secondary to the presence of similar cytomorphological features in lesions other than those associated with TB.^{9,10} Mycobacterial culture is a gold standard method for diagnosis of extra-pulmonary tuberculosis, but it is costly, results take a longer time i.e. 4 to 8 weeks, and are usually not available in a resource-poor setting.² Thus, a more rapid and reliable method for its diagnosis is the need of an hour.

WHO endorsed a new technique i.e. cartridge based nucleic acid amplification test (CBNAAT) or Gene Xpert *Mycobacterium tuberculosis* complex/resistance to rifampin (MTB/RIF) for use in TB laboratories in 2010, and it was adopted by India under the umbrella of revised national TB control programme (RNTCP) in 2012. CBNAAT assay is based on real-time polymerase chain reaction (RT-PCR) which has a high diagnostic yield. Apart from the diagnosis of TB, it is also helpful in the identification of rifampicin resistance within 2 hours and requires minimal expertise.¹¹

This study was conducted at a tertiary care center to assess the clinical manifestations of extra-pulmonary TB (head and neck) in diagnosed pulmonary TB patients and without pulmonary TB and to determine the sensitivity and specificity of CBNAAT in the diagnosis of extra-pulmonary TB.

METHODS

The study was conducted as an observational study at the Department of Otorhinolaryngology and head-neck surgery, tertiary care center, Jabalpur (Madhya Pradesh) for a period of 18 months i.e. from 01 March 2019 to 31 August 2020. All the patients presenting with an abscess in the head and neck region; any lesion in ear, nose, throat, and neck with extra-pulmonary TB manifestation and/or pulmonary TB manifestation and cervical lymphadenopathy were included whereas patients not willing to participate in the study were excluded from the study.

After obtaining ethical clearance from the institute's ethical committee, informed written consent was taken from all the subjects fulfilling the inclusion criteria. Detailed data of socio-demographic variables such as age, sex, socio-economic status, etc. was obtained from all the study participants and entered in a pretested semi-structured questionnaire. A detailed history regarding presenting complaints, duration, onset and family history of TB, past history of TB/contact with a TB patient was also enquired. Further, all the participants were subjected to a detailed general and local examination which included

site, size, shape, mobility, and condition of overlying skin. Detailed examination of ears, nose, and throat was conducted and findings were noted. All the necessary investigations were done with tuberculosis workup including early morning sputum examination, Mantoux test, chest X-ray (CXR) and ultrasonography (USG). Fine needle aspiration cytology (FNAC) and histopathology were done when required. Sputum samples were analyzed by CBNAAT on Xpert- MTB/RIF. Patients were treated accordingly. Appropriate surgical intervention was done in necessary cases.

This data was compiled using Microsoft (MS) excel and analyzed using IBM statistical package for the social sciences (SPSS) software version 20. Categorical data were expressed and frequency and percentage whereas numerical data were expressed as mean and standard deviation. The sensitivity, specificity, positive predictive value, negative predictive value, diagnostic accuracy for CBNAAT was calculated.

Ethical approval

All procedures performed in studies involving human participants were in accordance with the ethical standards of the institutional and/or national research committee and with the 1964 Helsinki declaration and its later amendments or comparable ethical standards.

RESULTS

The study was conducted on a total of 30 patients with a mean age of 29.6 ± 10.9 years presenting with clinical manifestations suggestive of tuberculosis. The majority of patients in the present study belonged to the age range of 21 to 30 years (36.7%) and only 16.7% of patients belonged to more than 40 years of age group. Male and females constituted equal proportions of the study population and maximum i.e. 93.3% cases were Muslim. The majority of patients were students (36.7%), followed by 26.7% housewives, and maximum cases i.e. 60% and 73.3% were residents of urban areas and belonged to lower socioeconomic status respectively (Table 1).

Among various local features, neck swelling and ear discharge were the most common features observed in 66.7% of cases each followed by decreased hearing. However, among systemic features, loss of appetite (46.7%), followed by weight loss and low-grade fever was most commonly observed in 43.3% and 33.3% cases respectively. Enlarged lymph nodes, facial nerve palsy, and productive cough were noted in only 3.3% of cases (Table 2).

Duration of symptoms ranged between 2 to 6 months in maximum i.e. 33.3% patients followed by 20% patients with duration of symptoms of more than 24 months. However, symptoms were present for less than one month and 7 to 12 months in 16.7% of cases each. Past history of TB and history of contact with TB was noted in 26.7% of

cases each whereas about 6.7% of cases gave a positive history of TB in the family.

Table 1: Distribution of patients according to sociodemographic variables.

Sociodemographic variables	Frequency (n=30)	Percentage
Age group (in years)		
≤20	6	20.0
21-30	11	36.7
31-40	8	26.7
>40	5	16.7
Gender		
Male	15	50.0
Female	15	50.0
Religion		
Hindu	28	93.3
Muslim	2	6.7
Occupation		
Farmer	4	13.3
Shopkeeper	4	13.3
Liasoning officer	1	3.3
Salesman	1	3.3
Unemployed	1	3.3
Student	11	36.7
Housewife	8	26.7
Residence		
Rural	12	40.0
Urban	18	60.0
Socioeconomic status		
Low	22	73.3
Middle	8	26.7

In cases with pulmonary TB, systemic features were the most predominant features which included loss of appetite in 83.3% of cases followed by weight loss and night sweats in 66.7% cases each. Local features involving the neck and ear were observed in approximately half of the patients (Figure 1).

In cases with extra-pulmonary tuberculosis involving head and neck, local features were predominant including swelling in the neck in 66.7% of cases. Ear discharge and decreased hearing were noted in 20.8% and 12.5% cases respectively (Figure 2).

Ears either unilateral or bilateral were the most common site of tuberculosis in 33.3% of cases, followed by the submandibular region affected in 13.3% of cases and the anterior aspect of the neck and posterior triangle of the neck in 10% cases each (Table 3).

The size of the lesion ranged between 6 to 10 cm² in maximum patients (33.3%) whereas oval (30%) and irregular (23.3%) shaped lesions were commonly observed. Mobility was restricted in 20% of cases whereas consistency of lesion was hard and soft in 26.7% of cases

each. The overlying skin was affected in 43.3% of cases of TB in the present study. Pus discharge was noted in 60% of patients with head and neck TB. Of them, the yellow discharge was noted in 72.2% of cases with a thick consistency. However, pus was thin and watery in 16.7% and 11.1% cases respectively.

Table 2: Distribution according to clinical features.

Clinical features	Frequency (n=30)	Percentage
Local		
Neck (swelling)		
Total	20	66.7
Anterior aspect of the neck	2	6.7
Infra-auricular	1	3.3
Midline	1	3.3
Post auricular	3	10.0
Posterior side of the neck	3	10.0
Multiple recurrent	2	6.7
Submandibular	4	13.3
Supraclavicular	2	6.7
Ear		
Ear discharge	6	20.0
Pain in ear	2	6.7
Tinnitus	1	3.3
Decreased hearing	4	13.3
Postauricular fistula	2	6.7
Ear perforation	1	3.3
Facial nerve palsy	1	3.3
Vestibular complaints	1	3.3
Throat		
Difficulty in swallowing	2	6.7
Oral ulcer	2	6.7
Systemic		
Enlarged lymph nodes	1	3.3
Weight loss	13	43.3
Loss of appetite	14	46.7
Night sweats	3	10.0
Low-grade fever	10	33.3
Chronic cough	2	6.7
Productive cough	1	3.3

Erythrocyte sedimentation rate (ESR) was raised in 86.7% of cases with TB. However, Mantoux positivity and anemia were noted in 76.7% and 63.3% cases respectively. Pus culture revealed acid-fast bacilli in 16.7% and >10 bacilli/high power field in 3.3% cases.

Sputum for acid-fast bacillus (AFB) was positive in only 13.3% of patients. CBNAAT was suggestive of TB in 83.3% of cases out of 30 patients with tuberculosis. Among them, rifampicin resistance was noted in none of the patients.

FNAC revealed granulomatous lymphadenitis as the most common finding noted in 43.3% of cases whereas

histopathology revealed caseous tuberculous lymphadenitis in 30% of patients (Table 4).

Table 3: Distribution of patients according to the site of tuberculosis.

Site	Frequency (n=30)	%
Unilateral ear	7	23.3
Both ear	3	10.0
Anterior aspect of neck	3	10.0
Cervical lymph node	1	3.3
Left side of neck	1	3.3
Neck	2	6.7
Post auricular area	1	3.3
Posterior side of neck	1	3.3
Posterior triangle of neck	3	10.0
Right buccal mucosa	1	3.3
Submandibular region	4	13.3
Supraclavicular area	2	6.7
Throat and neck	1	3.3

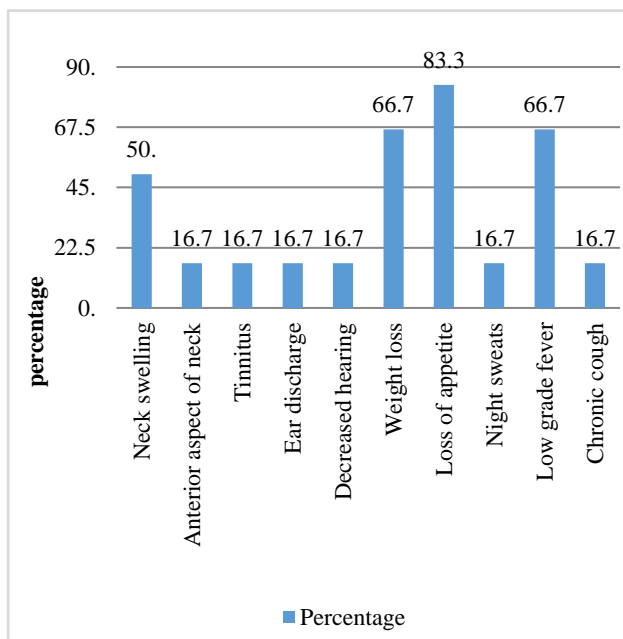


Figure 1: Distribution according to clinical features in pulmonary tuberculosis.

Table 4: Distribution according to findings of various investigations.

Investigations	Frequency (n=30)	Percentage
Anemia	19	63.3
Raised ESR	26	86.7
Montoux positive	23	76.7
Pus culture		
>10 bacilli/high power field	1	3.3
Acid-fast bacilli	5	16.7
No growth	24	80.0

Chest X-ray revealed bilateral hilar lymphadenopathy in 6.7% of cases, whereas cavity infiltrates in the upper lobe of the lung, pleural effusion, and small cavity in the middle lobe of the lung were noted in 3.3% cases each. However, a chest x-ray was normal in 80% of patients. X-ray mastoid shows clouding of air cells with thick sclerotic margins was noted in 10% patients. Cervical lymphadenopathy was the most common finding on USG in extra-pulmonary TB cases in 13.3% cases.

Computed tomography (CT)/magnetic resonance imaging (MRI) revealed osteomyelitis of the temporal bone, patchy osteolysis, sclerotic changes in the temporal bone, hypo dense opacification of the middle ear, and loculated mass in parotid in 3.3% cases each (Table 5).

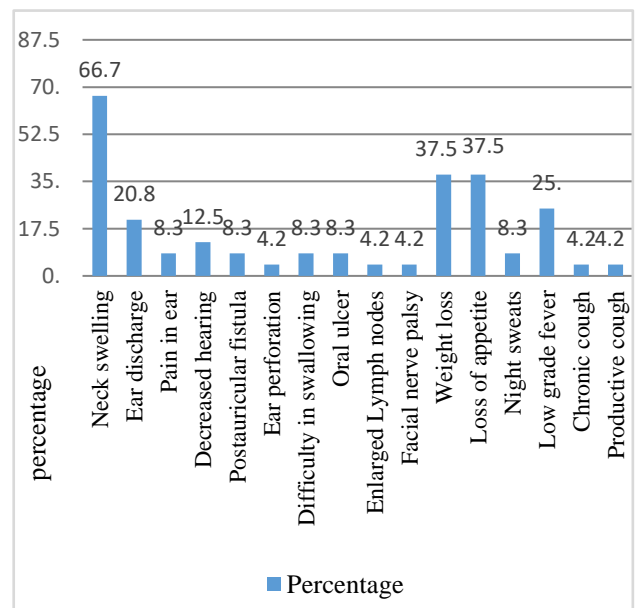


Figure 2: Distribution according to clinical features in extra pulmonary tuberculosis.

Overall, the diagnostic accuracy of CBNAAT was 83.3% and 79.2% for the diagnosis of tuberculosis irrespective of type and extra-pulmonary tuberculosis respectively. However, sensitivity, specificity, positive predictive value (PPV) and negative predictive value (NPV) of CBNAAT was documented to be 85%, 50%, 89.5% and 40% respectively (Table 6).

Continued.

Investigations	Frequency (n=30)	Percentage
Sputum for AFB		
Positive	4	13.3
Negative	26	86.7
CBNAAT		
Positive	25	83.3
Negative	5	16.7
FNAC		
Caseous tubercular lymphadenitis	4	13.3
Granulomatous caseating lymphadenitis	1	3.3
Granulomatous lesion	2	6.7
Granulomatous lymphadenitis	13	43.3
Granulomatous lymphadenopathy	1	3.3
Non-specific inflammation	1	3.3
Not done	8	26.7
Histopathology		
Non-specific lymphadenitis	1	3.3
Caseating tuberculous lymphadenitis	9	30.0
Chronic non-specific inflammation	2	6.7
Granulomatous lesion	2	6.7
Granulomatous lesion with lymphocytic infiltration	3	10.0
Granulomatous tubercular lymphadenitis	5	16.7
Tuberculous osteomyelitis	1	3.3
Not done	7	23.3

Table 5: Distribution according to findings of radiological investigations.

Investigations	Frequency (n=30)	Percentage
CXR		
Cavity infiltrate in upper lobe of lung	1	3.3
Bilateral hilar lymphadenopathy	2	6.7
Pleural effusion	1	3.3
Patchy lesion in apical lobe	1	3.3
Small cavity in middle lobe of lung	1	3.3
Normal	24	80.0
Site-specific X-ray		
Sign of heterogeneous and hypoechoic oval lesion in right submandibular and left posterolateral aspect of the neck	1	3.3
Soft tissue density focus is seen on supraclavicular	1	3.3
Thickened margins of the right mastoid cavity with the destruction of bony septal	1	3.3
Widened punched margins, sinodural angle with sclerosis of mastoid cavity	1	3.3
X-ray mastoid shows clouding of air cells with thick sclerotic margins	3	10.0
Normal	10	33.3
Not done	13	43.3
USG		
Abscess	1	3.3
Abscess over posterior triangle	1	3.3
Cervical lymphadenopathy	4	13.3
Cystic hygroma	1	3.3
Inflammatory echolitis abscess	1	3.3
Infracted sebaceous cyst	1	3.3
Lymph node with necrotic center	1	3.3
Multiple enlarged LN in post triangle	1	3.3

Continued.

Investigations	Frequency (n=30)	Percentage
Multiple heterogeneous round to oval lesions with maintained central fatty hilum	1	3.3
Retropharyngeal abscess	1	3.3
Enlarged lymph node	1	3.3
Sign of lymphadenitis	2	6.7
Submandibular lymphadenopathy	2	6.7
Supraclavicular abscess	1	3.3
Supraclavicular lymphadenopathy	1	3.3
Normal	1	3.3
Not done	9	30.0
CT/MRI		
Hypo dense opacification in epitympanum, attic, aditus and middle ear cavity, suspicious erosion of facial nerve canal, noted in the horizontal segment	1	3.3
Lobulated mass in parotid gland neoplasm adenoma, granuloma	1	3.3
Osteomyelitis of temporal bone	1	3.3
Patchy osteolysis of petrous air septae with opacification	1	3.3
Sclerotic changes in the temporal bone	1	3.3
Swelling in submental region	1	3.3
Unsafe otitis media	1	3.3
Not done	23	76.7

Table 6: Diagnostic accuracy of CBNAAT in tuberculosis.

Diagnostic accuracy	Overall	EPTB
Diagnostic accuracy	83.3	79.2
Sensitivity	88.5	85
Specificity	50	50
PPV	92	89.5
NPV	40	40

DISCUSSION

TB is still one of the major causes of morbidity as well as mortality in low-middle income countries. Though pulmonary TB is a major contributor to overall TB, however, the incidence of extra-pulmonary TB is rising rapidly worldwide. The symptoms and signs of head and neck tuberculosis depend upon the site of TB and the presence of concomitant pulmonary TB or other associated co-morbidities. Systemic features such as fever, weight loss, etc. as evident in pulmonary TB are also observed in patients with head and neck TB.¹² In the present study, overall, neck swelling and ear discharge were the most common features observed in 66.7% of cases irrespective of site and type of TB. However, in cases with pulmonary tuberculosis, systemic features were predominant such as loss of appetite observed in 83.3% of cases whereas local features involving the neck and ear were observed in approximately 50% of patients.

In cases of extra-pulmonary TB, local features were predominant including swelling in the neck in 66.7% of cases. Ear discharge and decreased hearing were noted in 20.8% and 12.5% cases respectively. Symptoms were present for 2 to 6 months in the majority i.e. 33.3% of patients whereas symptoms with a duration of less than one

month were noted in 16.7% of cases. These findings were concordant with the findings of Pandurang et al in which neck swelling (82.9%) was the predominant feature in head and neck TB followed by difficulty in swallowing and change in voice. About 33% of patients had associated pulmonary tuberculosis.¹³ Similarly, Thorawade et al also documented neck swelling as the most common complaint in patients with head and neck TB followed by cervical lymphadenopathy. Systemic features were noted in a small number of patients in the reference study which included fever (22 patients), weight loss (17 patients), and cough with expectoration (8 patients).¹⁴

Site of TB of head and neck are varied and features may mimic malignancy.¹⁵ Among various sites of head and neck tuberculosis, ears were most commonly affected in our study (33.3%), of them, unilateral ear either left or right was the site in 23.3% of cases whereas, in the remaining 10% cases, bilateral ears were affected. Apart from this, the submandibular region was the second most commonly affected site in 13.3% of cases followed by the anterior aspect of the neck and the posterior triangle of the neck in 10% of cases each. In contrast to the present study, the most common site of head and neck TB in a study by Bokare et al was cervical lymphadenopathy, followed by laryngeal TB, and middle ear.¹⁶ Thorawade et al also observed tubercular lymphadenitis to be the most common form of head and neck tuberculosis. TB involving the middle ear was observed in only 5.83% of cases which was much less as compared to the present study.¹⁴

The smear microscopy for the detection of AFB and culture are used for the diagnosis of TB. But the extra-pulmonary cases are usually pauci-bacillary in nature and thus sputum smear microscopy is usually negative. The major drawback of culture for diagnosis is the requirement

of a long duration for the growth of TB.¹⁷ In the present study, in about 76.7% of cases, Mantoux was reactive. Pus culture revealed AFB in 16.7% of cases whereas sputum was positive for AFB in 13.3% of patients. Kumari et al in their study in India observe sputum smear positivity in 24% cases out of 100 cases with cervical tuberculous lymphadenopathy.¹⁸ In another study by Kasat et al, out of 166 cases of EPTB, AFP was positive in only 7 cases depicting low utility of AFB smear in extra-pulmonary cases.¹⁹

FNAC and histopathological examination of tuberculous lesion typically reveal epithelioid cells, caseation i.e. presence of eosinophilic granular material, multinucleated giant cells, and presence of acute inflammatory exudates particularly neutrophils.²⁰ In the present study, FNAC revealed granulomatous lymphadenitis to be the most common finding in TB of head and neck whereas caseous tubercular lymphadenitis, granulomatous lesion, granulomatous caseous lymphadenitis, granulomatous lymphadenopathy, etc. were observed in few patients. Similarly, typical caseation was observed in 30% of patients on histopathology followed by granulomatous tubercular lymphadenitis and granulomatous lesion with lymphocytic infiltration in 16.7% and 10% patients respectively. Pathognomonic features of TB i.e. caseation and neutrophilic aggregates were present in 56.3 and 72.9% cases in a study by Samaila et al, FNAC showed a granulomatous lesion in 3 cases (33.3%) and histopathological examination showed 100% results in a study by Sachdeva et al.^{21,22}

Though X-ray of the chest is a basic imaging modality for pulmonary TB, the role of X ray in extra-pulmonary TB is very low. Thus, computed tomography, magnetic resonance imaging, and nuclear medicine techniques are helpful in the assessment of both pulmonary and extra-pulmonary TB. Literature suggests that CT and MR imaging are important tools for the evaluation of head and neck TB. They are advantageous as they help in accurately demonstrating the sites, pattern, and extent of the disease.²³ Radiographic findings in head and neck TB may include the destruction of the ossicles, clouding of mastoid air cells, sclerosis of the mastoid cortex, etc.²⁴

CBNAAT is a cartridge-based nucleic acid amplification test that not only detects TB bacilli but also tests for resistance to rifampicin.⁴ CBNAAT gives results rapidly within 2 hours of testing. The sensitivity of CBNAAT for diagnosis of EPTB has been documented to be low however its specificity has been reported to be as high as 100%.²² Our study documented the diagnostic accuracy of CBNAAT to be 83.3% for the diagnosis of all cases of TB whereas it was 79.2% for extra-pulmonary TB. Sensitivity, specificity, PPV, and NPV of CBNAAT for extra-pulmonary TB were documented to be 85%, 50%, 89.5% and 40% respectively. Similarly, Sharma et al also documented sensitivity of 71% and PPV ranging from 98 to 100%.⁵ Patil et al noted the sensitivity of CBNAAT to be similar to the present study, but specificity was much

higher in the reference study (80.57%) as compared to the present study (50%).²⁵ Sensitivity, specificity, positive predictive value, and negative predictive value of CBNAAT were documented to be 92.7%, 98.9%, 97.1%, and 97.2% respectively in a study by Kumar et al.²⁶

CONCLUSION

TB of the head and neck are commonly encountered in clinical practice. The patients usually present with variable clinical manifestations depending upon the site of involvement. The middle ear is the most common site affected by head and neck TB. CBNAAT is a sensitive tool for the diagnosis of extra-pulmonary TB with and without associated pulmonary TB. Early and timely diagnosis of extra-pulmonary TB followed by anti-tubercular therapy yields excellent results.

Funding: No funding sources

Conflict of interest: None declared

Ethical approval: The study was approved by the Institutional Ethics Committee

REFERENCES

1. Langer AJ, Iqbal SA, Pratt R. Tuberculosis statistics in the United States. The report, United States Department of Health and Human Services, Public Health Services, Centres for Disease Control, Atlanta, GA, 1989, 1991.
2. Komanapalli SK, Prasad U, Atla B, Vasundhara N, Yendluri D. Role of CB-NAAT in diagnosing extrapulmonary tuberculosis in correlation with FNA in a tertiary care center. *Int J Res Med Sci.* 2018;6(12):4039-45.
3. Ramirez-Lapausa M, Menendez-Saldana A, Noguerado-Asensio A. Extrapulmonary tuberculosis: an overview. *Rev Esp Sanid Penit.* 2015;17:3-11.
4. Tuberculosis. Central TB Division. Government of India. Available at: <https://tbcindia.gov.in/WriteReadData/India%20TB%20Report%202019.pdf>. Accessed on 23 October 2020.
5. Sharma SK, Mohan A. Extrapulmonary tuberculosis. *Indian J Med Res.* 2004;120:316-53.
6. Index TB guidelines. World Health Organization. India. Available at: http://www.tbonline.info/media/uploads/documents/index-tb_guidelines_-_green_colour_2594164.pdf Accessed on 23 October 2020.
7. Sumi S, Radhakrishnan VV. Evaluation of Immunohistochemistry with a panel of antibodies against recombinant mycobacterial antigens for the diagnosis of tuberculous lymphadenitis. *Int J Med Medic Sc.* 2009;1(5):215-9.
8. Tadesse M, Abebe G, Abdissa K, Aragaw D, Abdella K, Bekele A, et al. GeneXpert MTB/RIF Assay for the Diagnosis of Tuberculous Lymphadenitis on Concentrated Fine Needle Aspirates in High Tuberculosis Burden Settings. *PLoS one.* 2015;10(9):e0137471.

9. Ammari FF, Hani AHB, Ghariebeh KI. Tuberculosis of the lymph glands of the neck: a limited role for surgery. *Otolaryngol Head Neck Surg.* 2003;128:576-80.
10. Bekedam H, Boeree M, Kamenya A, Liomba G, Ngwira B, Subramanyam V, et al. Tuberculosis lymphadenitis, a diagnostic problem in areas of the high prevalence of HIV and tuberculosis. *Malawi Medical J.* 2014;11:56-9.
11. Standard Operating Procedure (SOP) for processing extrapulmonary specimens (CSF, lymph nodes, and other tissues) for Xpert MTB/RIF assay. Available at: <https://www.ncbi.nlm.nih.gov/books/NBK254320/>. Accessed on 23 October 2020.
12. Zaman K. Tuberculosis: a global health problem. *J Health Popul Nutr.* 2010;28(2):111.
13. Pandurang K, Shenoy VS, Bhojwani K, Alva A, Prasad V, Gandla S. Tuberculosis in the head and neck in India: down but not yet dead. *J Mycobac Dis.* 2014;4(148):2161-8.
14. Thorawade VP, Jaiswal SA, Gupta SR. Manifestations of Tuberculosis in Ear, Nose, Throat, Head and Neck Region—A Retrospective Study. *Bengal J Otolaryngol Head Neck Surg.* 2020;28(2):144-50.
15. Shah C, Joshi C, Prajapati B, Gupta N, Italiya K. Tuberculosis in ENT. *BJ Kines-NJBAS.* 2020;12(1):9-15.
16. Bokare B, Mehta K. Otolaryngological Manifestations of Tuberculosis: A Clinical Study. *Indian J Otolaryngol Head Neck Surg.* 2020.
17. Honore-Bouakline S, Vincensini JP, Giacuzzo V, Lagrange PH, Herrmann JL. Rapid diagnosis of extrapulmonary tuberculosis by PCR: impact of sample preparation and DNA extraction. *J Clin Microbiol.* 2003;41(6):2323-9.
18. Kumari M, Khambra P, Panwar K. Rapid diagnosis of tubercular lymphadenopathy by cartridge-based nucleic acid amplification test (CBNAAT) and its correlation with Ziehl-Neelsen staining on fine-needle aspiration cytology. *Int J Health Sci Res.* 2020;10(7):17-21.
19. Kasat S, Biradar M, Deshmukh A, Jadhav S, Deshmukh H. Effectiveness of CBNAAT in the diagnosis of extrapulmonary tuberculosis. *Int J Res Med Sci.* 2018;6:3925-8.
20. Lau SK, Wei WI, Hsu C, Engzell UC. Fine needle aspiration biopsy of tuberculous cervical lymphadenopathy. *Aust N Z J Surg.* 1988;58:947-50.
21. Samaila M, Oluwole OP. Extrapulmonary tuberculosis: Fine needle aspiration cytology diagnosis. *Niger J Clin Pract.* 2011;14:297-9.
22. Sachdeva K, Shrivastava T. CBNAAT: A Boon for Early Diagnosis of Tuberculosis-Head and Neck. *Indian J Otolaryngol Head Neck Surg.* 2018;70(4):572-7.
23. Moon WK, Han MH, Chang KH, Im JG, Kim HJ, Sung KJ, Lee HK. CT and MR imaging of head and neck tuberculosis. *Radiographics.* 1997;17(2):391-402.
24. Rho MH, Kim DW, Kim SS, Sung YS, Kwon JS, Lee SW. Tuberculous otomastoiditis on high-resolution temporal bone CT: comparison with nontuberculous otomastoiditis with and without cholesteatoma. *Am J Neuroradiol.* 2007;28(3):493-6.
25. Patil SB, Dhage SM, Umap PS, Ghorpade SV, Patharwat S. Cartridge based nucleic acid amplification test: a sensitive diagnostic tool for tuberculosis on fine-needle aspirates samples. *Int J Comm Med Public Health.* 2020;7:1511-5.
26. Kumar A, Das S, Paul DK. A study on the role of cartridge-based nucleic acid amplification test (CBNAAT) for diagnosing pediatric tuberculosis in a tertiary care hospital in Eastern India. *Acad J Ped Neonatol.* 2018;6:555745.

Cite this article as: Vatsyayan R, Sachdeva K. Extrapulmonary tuberculosis manifestation in head and neck and its diagnosis with recent tools like cartridge based nucleic acid amplification test. *Int J Otorhinolaryngol Head Neck Surg* 2021;7:829-36.