

## Original Research Article

# Actinomyces causing chronic tonsillitis: a retrospective study

Ravishankara S., Madhumitha Srinivas, Sreedevi N. T.\*

Department of Ear Nose Throat and Head and Neck Surgery, K.V.G Medical College and Hospital, Sullia, Dakshina Kannada, Karnataka, India

**Received:** 16 February 2021

**Accepted:** 18 March 2021

**\*Correspondence:**

Dr. Sreedevi N. T.,

E-mail: Sreedevint8@gmail.com

**Copyright:** © the author(s), publisher and licensee Medip Academy. This is an open-access article distributed under the terms of the Creative Commons Attribution Non-Commercial License, which permits unrestricted non-commercial use, distribution, and reproduction in any medium, provided the original work is properly cited.

### ABSTRACT

**Background:** Actinomyces is often overlooked and hence reported as rare infection of palatine tonsils. It can often lead to chronic tonsillitis and can masquerade as oropharyngeal malignancy. Objectives were to estimate the proportion of actinomyces causing chronic tonsillitis using histopathological evidence and to describe the histopathology of tonsillectomy specimens.

**Methods:** Total 33 patients had undergone tonsillectomy in the study period of June 2018 to September 2020. Tonsil biopsy specimens stained with haematoxylin-Eosin stain and gram Stain were evaluated by light microscopy examination for the presence of actinomyces.

**Results:** Total 4 Patients (8 tonsillectomy specimens) had evidence of actinomycosis on histopathological examination constituting 12.12 % of the total specimens examined, the mean age was 17 years (ranging from 5 to 42 years). One of the specimens had unilateral tonsillar cyst which revealed colonies of actinomyces.

**Conclusions:** Actinomycosis of tonsil is a common condition which is usually missed as routine histopathological examination of excised tonsils is not done. Hence, we recommend routine histopathological examination of all tonsillectomy specimens irrespective of age.

**Keywords:** Actinomyces, Tonsillar actinomycosis, Chronic tonsillitis

## INTRODUCTION

Tonsillectomy is one of the most commonly performed surgical procedures in otorhinolaryngology department. There are many indications for performing tonsillectomy. Resistant bacteria that can cause recurrent infections in tonsils have been an increasing concern over the past decade because of the widespread and prolonged use of antibiotics. Actinomycosis infection of tonsils is one such cause of tonsillitis which is often missed as many institutions do not routinely perform histopathological examination of tonsillectomy specimens.<sup>1</sup>

Actinomyces in the tonsils was first identified in 1896.<sup>2</sup> Actinomyces is a Gram-positive, non- acid fast, anaerobic, branching, filamentous bacteria. It causes chronic suppurative inflammation. It is a common

commensal in human oral cavity, colon and vagina. Colonisations of actinomyces is most common in cervicofacial region (55%), followed by thoracic region (20%) and abdomino-pelvic region (15%). About 6.7-35% of tonsillectomy specimens have been reported to have actinomyces colonies.<sup>1,3,4</sup> The disease is predominantly characterized by spread to contiguous tissues as it disrupts mucosal barriers and it can masquerade as any oropharyngeal malignancy/any oropharyngeal lesions.<sup>5</sup> Main cause of disruption is dental caries or trauma, surgery or another infection.<sup>6</sup> It has an indolent course which makes it difficult to eradicate the disease.

### Objectives

Objectives were 1) to estimate the proportion of actinomyces causing chronic tonsillitis using

histopathological evidence 2) to describe the histopathology of all routine tonsillectomy specimens in order to identify the difference in histopathology of tonsils affected with actinomycosis.

**METHODS**

This is a retrospective study conducted in the department in the department of ENT, KVG medical college Sullia. We retrospectively analysed the data of patient who underwent tonsillectomy during the period from June 2018 to September 2020. We applied the following inclusion and exclusion criteria for selection of patients.

**Inclusion criteria**

Patients of the age of 5-50 years with recurrent episodes of tonsillitis (At least 3 episodes in each of 3 years, or five episodes in each of 2 years, or 7episodes in 1 year) undergoing tonsillectomy.

**Exclusion criteria**

Exclusion criteria were 1) immunocompromised patients with tonsillar hypertrophy 2) patients presenting with peritonsillar abscess.

Total 33 patients met the above-mentioned criteria and were included in the study. All of them were included in the study. All of them had undergone bilateral tonsillectomy. Hence there were 66 tonsillectomy specimens which were subjected to histopathological examination. The tonsillar tissues were fixed in formalin, embedded in paraffin and prepared slides stained with H&E stain.

The serial sections showing actinomycosis infection in the slides were stained with Gram Stain. The presence of cryptitis, reactive lymphoid follicular hyperplasia, and tonsillar fibrosis were noted. Further analysis of the data was done to determine the statistical significance of actinomycosis in association with chronic tonsillitis.

**RESULTS**

Out of eight tonsillar specimens from 4 patients who underwent tonsillectomy had actinomycosis infection. The most common indication for tonsillectomy was chronic tonsillitis. The mean age of patients was 17 years (range 5-42 years). There were 20 males and 13 female patients in the study. Among them 2 males and 2 females had actinomycosis showing bilateral infection with actinomycosis.

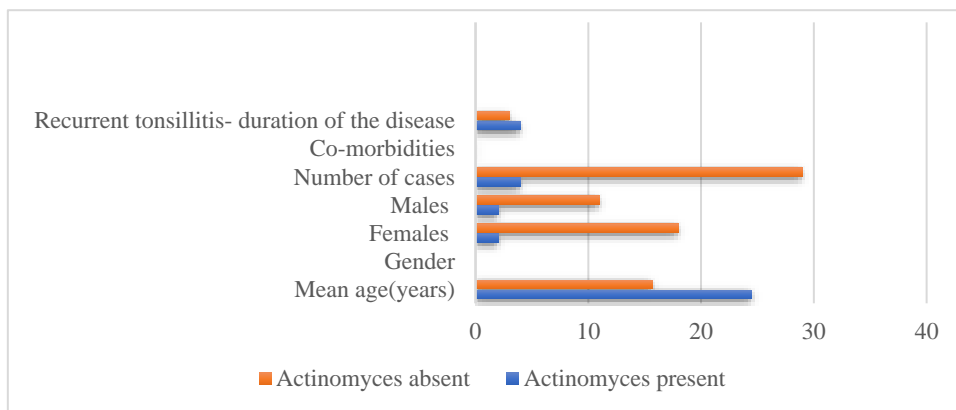
Microscopic examination of the excised bilateral tonsillar tissue showed the following observations: 1) stratified squamous epithelial lining with intraepithelial lymphocytes 2) the sub epithelial region showed severe lymphoid follicular hyperplasia with prominent germinal centre 3) actinomyces bacterial colonies were seen at the centre of the inflammatory reaction comprising of neutrophils, eosinophils, lymphocytes and plasma cells 4) in one of the specimens a cyst was lined with stratified squamous epithelium, the lumen of the cyst contained numerous actinomycotic colonies. The incidence of actinomyces in this study is 12.12%.

**Table 1: Demographic data of cases.**

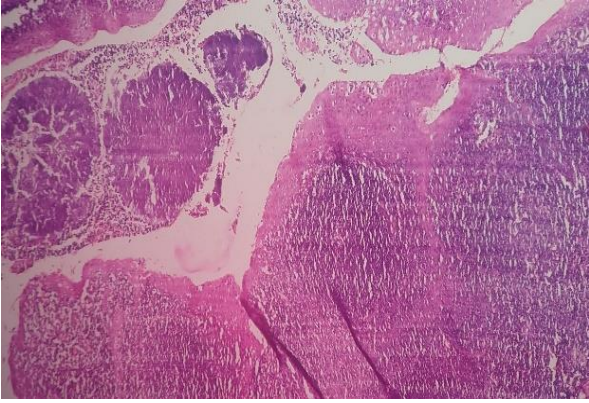
	Actinomyces present	Actinomyces absent
<b>Number of cases (%)</b>	4 (12.12)	29 (87.87)
<b>Mean age (years)</b>	24.5	15.7
<b>Gender</b>		
<b>Females</b>	2 (6.06%)	18
<b>Males</b>	2 (6.06%)	11
<b>Co-morbidities</b>	0	0
<b>Recurrent tonsillitis-Duration of disease (years)</b>	4 ± 1	3 ± 1

**Table 2: Unilateral vs. bilateral tonsillar actinomycosis.**

Actinomycosis	Number	Percentage
<b>Unilateral</b>	0	0



**Figure 1: Demographic data of the cases.**



**Figure 2: On light microscopy aggregates of filamentous basophilic microorganisms in actinomycosis.**

## DISCUSSION

Infection due to actinomycetes in tonsils and its clinical significance is controversial in the available literature. Chronic tonsillitis due to actinomycotic infection has been reported in a small percentage of people.<sup>7</sup> Most commonly actinomycosis of the head and neck region presents with abscess formation, draining sinuses, fistulae and tissue fibrosis. In our study one of the specimens consisted of tonsillar cyst containing infection of actinomycetes. But the significance of actinomycetes colonization in the tonsils is not clear, even though tonsillectomy is one of the most common operations in otolaryngology. The pathogenesis of tonsillitis and tonsillar hypertrophy due to actinomycetes is controversial. The disease in the cervical-facial region is precipitated by several factors like dental caries, periodontal disease and maxillo-facial trauma. About 6.7-35% of tonsillectomy specimens have been reported to have actinomycetes colonies.<sup>3,4</sup> The incidence of actinomycetes in our retrospective study is 12.12%. The reasons for this variation include differences in the sectioning and staining techniques employed by different laboratories; the ages of the patients studied and discrepancies in the indications for tonsillectomy.<sup>1</sup> The use of antibiotics in the treatment of patients with recurrent and chronic tonsillitis has been postulated to explain the lower incidence rate of actinomycetes colonization in these patients.<sup>7</sup> The other reason for this wide incidence rate is because not all institutions routinely do histopathology of tonsillar specimen. Hence, the actual disease burden has not been assessed in a larger scale.

Pransky et al found that accurate detection of the presence of these organisms was possible only by histopathological studies of core tissues.<sup>8</sup> Many authors found no evidence of co-relation between chronic tonsillitis and actinomycetes, Gaffney et al reviewed 42 tonsils with actinomycosis and found no correlation between the presence of actinomycetes and chronic tonsillitis. Lierop et al examined 344 tonsils and found no tissue reaction due to actinomycetes colonies.<sup>9</sup> But in our

study, we found definitive tissue reaction to actinomycetes like lymphoid hyperplasia, bacterial colony surrounded by inflammatory cells. Several authors have found similar co-relations like Aydin et al found the incidence of Actinomycosis to be 6.7% and cryptitis was the common finding.<sup>10</sup> Assimakopoulos et al studied the histopathological specimens of 238 tonsils and concluded that actinomycetes colonization has role in causing chronic tonsillitis.<sup>4</sup> Ozgursoy et al advocated that actinomycetes colonization could cause lymphoid hyperplasia in chronic tonsillitis.<sup>11</sup> As actinomycetes is a part of dental plaque biofilm, so maintaining oral hygiene is crucial in prevention of actinomycetes infection in cervical region. Most of the authors have reported male preponderance in this condition which was not the case in our study.

## CONCLUSION

Actinomycosis of tonsil is a common condition which is usually missed as routine histopathology examination of tonsillectomy specimen is not done. Hence, we recommend routine histopathology examination of all tonsillectomy specimens irrespective of age to know the burden of the disease and to establish causal relationship with chronic tonsillitis.

## ACKNOWLEDGEMENTS

The authors would like to thank department of pathology, KVG medical college and hospital.

*Funding: No funding sources*

*Conflict of interest: None declared*

*Ethical approval: The study was approved by the Institutional Ethics Committee*

## REFERENCES

1. Hari KR, Maharaj S, Motakef S, Essa R. The role of tonsillar actinomycosis in adult patients. *Austral J Otolaryngol.* 2020;3.
2. Rippon JW. *Medical Mycology.* W.B. Saunders: Philadelphia; 1974;13–28.
3. Sendra AS, Pozo FX, Maroto BC, Carreras JS, Pedragosa JC. Tonsillar actinomycosis manifested as expectorated debris. *Acta Otorrinolaringologica.* 2009;60(5):372-4.
4. Assimakopoulos D, Vafiadis M, Askitis P. The incidence of *Actinomyces israelii* colonization in tonsillar tissue. A histopathological study. *Rev Stomatol Chir Maxillofac.* 1992;93:122–6.
5. Kaipuzha RR, Bakshi SS, Gopalakrishnan S, Govindarajan A. Actinomycotic infection of the tonsils: a case report and review of the literature. *Int J Orofac Biol.* 2018;2(1):31.
6. Stewart MG, Sulek M. Pediatric actinomycosis of the head and neck. *Ear Nose Throat J* 1993;72:614–9.
7. Bhargava D, Bhusnurmath B, Sundaram KR, Raman R, Al Okbi HM, Al Abri R, Date A.

- Tonsillar actinomycosis: a clinicopathological study. *Acta tropica.* 2001;80(2):163-8.
8. Pransky SM, Feldman JI, Kearns DB, Seid AB, Billman GF. Actinomycosis in obstructive tonsillar hypertrophy and recurrent tonsillitis. *Arch Otolaryngol Head Neck Surg.* 1991;117(8):883-5.
  9. van Lierop AC, Prescott CA, Sinclair-Smith CC. An investigation of the significance of Actinomycosis in tonsil disease. *Int J Pediat Otorhinolaryngol.* 2007;71(12):1883-8.
  10. Aydin A, Erkilic S, Bayazit YA, Koçer NE, Ozer E, Kanlikama M. Relation between actinomycosis and histopathological and clinical features of the palatine tonsils: a comparative study between adult and pediatric patients. *Revue de laryngologie-otologie-rhinologie.* 2005;126(2):95-8.
  11. Ozgursoy OB, Kemal O, Saatci MR, Tulunay O. Actinomycosis in the etiology of recurrent tonsillitis and obstructive tonsillar hypertrophy: answer from a histopathologic point of view. *J Otolaryngol Head Neck Surg.* 2008;37(6).

**Cite this article as:** Ravishankara S., Srinivas M, Sreedevi NT. Actinomyces causing chronic tonsillitis: a retrospective study. *Int J Otorhinolaryngol Head Neck Surg* 2021;7:653-6.