

## Case Report

# Diagnostic dilemma in cheek lesions in the paediatric age group: thinking beyond the expected

Anagha R. Joshi, Ashwini Sankhe, Soniya H. Patankar\*, Mrinalini M. Rahatgaonkar

Department of Radiodiagnosis, Lokmanya Tilak Municipal Medical College and General Hospital, Sion, Mumbai, India

**Received:** 31 January 2021

**Accepted:** 09 March 2021

### \*Correspondence:

Dr. Soniya H. Patankar,

E-mail: [soniya6793@gmail.com](mailto:soniya6793@gmail.com)

**Copyright:** © the author(s), publisher and licensee Medip Academy. This is an open-access article distributed under the terms of the Creative Commons Attribution Non-Commercial License, which permits unrestricted non-commercial use, distribution, and reproduction in any medium, provided the original work is properly cited.

### ABSTRACT

Rhabdomyosarcoma (RMS), a tumour of skeletal muscle origin, is the most common soft tissue sarcoma encountered in childhood. The head and neck region is the most common site of occurrence of RMS. RMS is a highly malignant tumour with extensive local invasions and early haemorrhagic and lymphatic dissemination. Despite the advances in treatment modalities, with aggressive approaches incorporating surgery, combination chemotherapy, and radiation therapy, the outcome for children with extensive, recurrent or metastatic disease remains poor. RMS in the head and neck region can be misdiagnosed as an infective or inflammatory swelling, thereby delaying the treatment. Here, we report a case of oral RMS in a 10-year-old child and highlight the need to include sinister pathologies like RMS in the differential diagnosis when dealing with cheek swellings in the paediatric age group.

**Keywords:** Rhabdomyosarcoma, Cheek swelling, Oral cavity

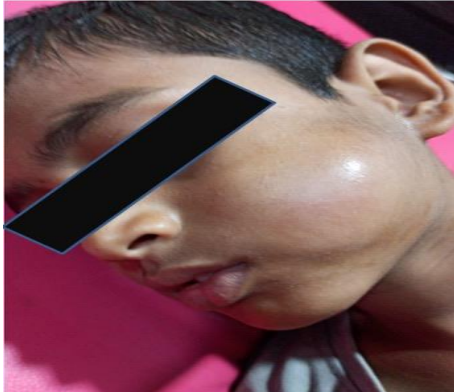## INTRODUCTION

Rhabdomyosarcoma (RMS) is the most common soft tissue sarcoma in childhood, representing around 6% of all childhood cancers.<sup>1</sup> It arises from primitive undifferentiated mesenchymal cells committed to the skeletal muscle lineage and can arise in a variety of sites. The head and neck region is the most common site of RMS in children.<sup>2</sup> Cheek swelling is often the initial complaint of children presenting with RMS of the oral cavity. These tumours can get misdiagnosed as infective or inflammatory sialadenitis and treatment can be delayed, leading to dismal prognosis. Ultrasound and computed tomographic (CT) scan are often the first imaging modalities performed in such cases. Through this case report we aim to put forth the need to think beyond the expected when dealing with cheek lesions in the paediatric age group and highlight the imaging findings of RMS of the oral cavity.

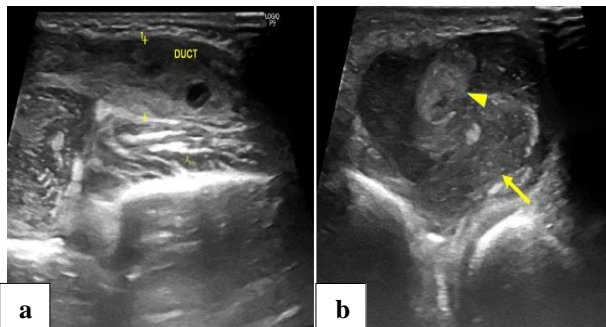
## CASE REPORT

A 10-year-old boy presented with a gradually progressive, painful pre-auricular swelling since two months. On enquiry, the parents gave a history of recurrent cheek bite by the child. The left cheek was oedematous and erythematous with stretched and shiny skin. The swelling was warm and tender (Figure 1). There was mild restriction of range of motion of the jaw. Peroral examination revealed an intraoral extension in the form of an oedematous mucosal swelling inside the left cheek. The patient did not have any history of chronic disease. There were no prior investigations performed. A local ultrasound examination (Figure 2) of the left cheek (linear high frequency transducer on GE LOGIQ 9 machine) revealed dilated left parotid duct with a mixed echogenicity soft tissue component within. The soft tissue component showed internal vascularity on colour Doppler study. A heterogeneously hypoechoic soft tissue lesion was seen adjacent to the dilated duct. The left parotid gland was,

however, unremarkable. A preliminary diagnosis of sialolithiasis with inflammatory sialadenitis was suggested and the patient was referred for a CT scan examination.



**Figure 1: Clinical photograph of a 10-year-old boy with swelling of the left cheek since two months. The overlying skin was stretched and glistening.**

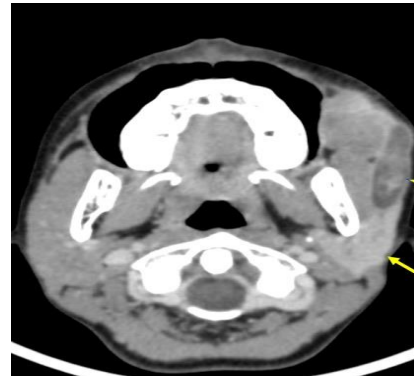

**Figure 2: Local ultrasound of the left cheek (a) longitudinal section along the course of the left parotid duct revealed dilated parotid duct with soft tissue within (b) cross sectional US view showed dilated parotid duct (arrowhead) with heterogeneously hypochoic lesion adjacent to it (arrow).**

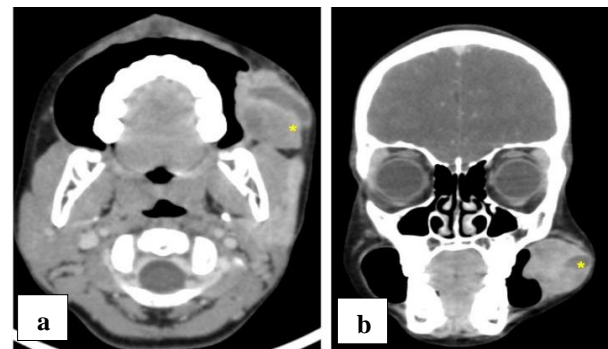
Multiplanar CT examination (performed on a 64 slice Philips Brilliance CT scanner) with the puffed cheek manoeuvre revealed a bulky left parotid gland with intense post-contrast enhancement as compared to the contralateral side. The left parotid duct was dilated in its entire course, with thickened enhancing walls (Figure 3). Additionally, the soft tissue component seen within the duct revealed enhancement. No calculi was found within the duct.

A well-defined hypodense lesion of average size 35×22×29 mm was seen in the left cheek and buccal mucosa-buccinator complex extending from the left upper first premolar up to the left upper second molar tooth, showing delayed heterogeneous enhancement (Figure 4). Laterally this lesion was seen to cause contour bulge. The dilated Stensen's duct was seen coursing through the lesion (Figure 5). Posteriorly, the lesion was seen to abut the left masseter muscle and superomedially the zygomatic

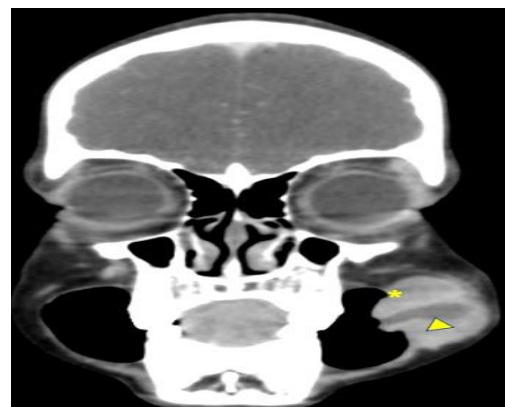
process of maxilla. There was no bony erosion. The intraoral component of the lesion around Stensen's duct opening was nodular and fungating. Few non-necrotic bilateral cervical lymph nodes were identified at levels II, III, and IV.



**Figure 3: Axial contrast enhanced CT with puffed cheek manoeuvre depicts bulky enhancing left parotid gland (arrow). The left parotid duct was dilated with thickened enhancing walls (arrowhead).**



**Figure 4: (a) Axial and (b) coronal contrast enhanced CT with puffed cheek manoeuvre shows a well-defined heterogeneously enhancing lesion (asterisk) in the left cheek and buccal mucosa-buccinator complex.**



**Figure 5: Coronal contrast enhanced CT with puffed cheek manoeuvre shows dilated parotid duct (arrowhead) coursing through the lesion (asterisk).**

The origin of parotid ductal mass was suspected to be neoplastic due to presence of nodular and fungating intra-oral component. However, a younger age also favoured an inclusion of inflammatory sialadenitis in the differential diagnoses. An intra-oral biopsy revealed RMS. The mass was positive for myogenin and desmin. The patient was referred to the paediatric oncology department and was started on combination chemotherapy consisting of vincristine sulphate, etoposide, prednisone, and doxorubicin hydrochloride. The child is being followed regularly.

## DISCUSSION

Soft tissue tumours are a heterogeneous group of neoplasms which arise from non-epithelial, extra-skeletal tissues of body like adipose tissue, skeletal muscle, tendon, cartilage, fibrous tissue, blood vessels, and lymphatic structures.<sup>3</sup> Rhabdomyoma and RMS are soft tissue tumours that arise from skeletal muscle. Rhabdomyosarcoma arises due to proliferation of embryonic mesenchymal tissue.<sup>4</sup> RMS is the most common soft tissue sarcoma in children. It has an incidence of 6% of all malignancies in patients under 15 years of age.<sup>1</sup> It is the third most common extracranial malignant tumour in children after neuroblastoma and Ewing's sarcoma.<sup>4</sup> There is a higher male preponderance with a male-to-female ratio of 1.3:1.<sup>5</sup>

RMS most commonly involves the head and neck region. RMS of the head and neck region can be anatomically divided into two categories namely parameningeal and non-parameningeal RMS. The former may affect nose, nasopharynx, paranasal sinuses, middle ear, mastoid, infratemporal fossa, and pterygopalatine fossa while the latter may involve scalp, orbit, oral cavity, oropharynx, and larynx.<sup>2</sup> RMS of the oral cavity accounts for 15% of the cases of RMS involving the head and neck region.<sup>6</sup> The genito-urinary tract, retroperitoneum and extremities can also be involved by the tumour, albeit to a lesser extent.<sup>5</sup>

Clinically, patient may present with a small cutaneous nodule to an extensive fast-growing facial swelling. The swelling may be painless or can sometimes be associated with pain. Additional presenting symptoms include trismus, paraesthesia, facial palsy, and nasal discharge.<sup>7</sup>

On histology, three subtypes of rhabdomyosarcoma are recognized. The embryonal subtype, the most common subtype which includes the botryoid variant as well. This subtype affects young children and has a relatively good prognosis. The alveolar subtype seen in older children is associated with a bad prognosis. The pleomorphic subtype of rhabdomyosarcoma is the least common. It is seen in adults and is associated with variable amounts of haemorrhage and necrosis. This subtype is associated with the worst prognosis.<sup>8</sup>

A careful histological examination is required to differentiate such lesions from other more frequent and aggressive lesions affecting the concerned site. The chief

differential diagnosis in the paediatric age group include Ewing's sarcoma and neuroblastoma. However, the reactivity for vimentin and myosin on immunohistochemistry points towards a diagnosis of RMS. In the paediatric age group, acute swelling around the jaws or orbit also warrants inclusion of Burkitt's lymphoma in the differential diagnosis. However, lymphoma frequently manifests with regional and generalized lymphadenopathy.<sup>9</sup>

In the paediatric age group, infective sialadenitis secondary to bacterial or viral aetiology is the most common swelling affecting the parotid and pre-parotid region.<sup>10</sup> In view of pain and tenderness, a differential diagnosis of inflammatory sialadenitis was also considered in our patient. However, the nodular and fungating intra-oral component with post contrast enhancement were suspicious for malignancy/aggressive pathology.

Prognosis of RMS is relatively poor compared to other oral soft tissue malignant lesions.<sup>11</sup> The prognosis depends on clinical staging and anatomic site of the tumour. An early diagnosis of RMS coupled with a multi-disciplinary approach is known to dramatically improve survival.

## CONCLUSION

Thus, in the paediatric age group, along with inflammatory or infective lesions a possibility of malignant aetiology should always be considered and a further aggressive course in the form of biopsy should be advocated as an early diagnosis can improve the outcome and survival in these cases.

*Funding: No funding sources*

*Conflict of interest: None declared*

*Ethical approval: Not required*

## REFERENCES

1. Peng KA, Grogan T, Wang MB. Head and neck sarcomas: analysis of the SEER database. *Otolaryngol Neck Surg.* 2014;151:627-33.
2. Miloglu O, Altas SS, Buyukkurt MC, Erdemci B, Altun O. Rhabdomyosarcoma of the oral cavity: a case report. *Eur J Dent.* 2011;5:340.
3. Razek AA, Huang BY. Soft tissue tumors of the head and neck: imaging-based review of the WHO classification. *Radiographics.* 2011;31:1923-54.
4. Dagher R, Helman L. Rhabdomyosarcoma: an overview. *The Oncologist.* 1999;4:34-44.
5. Otmani N, Khatib M. Advanced orofacial rhabdomyosarcoma: a retrospective study of 31 cases. *Int Arch Otorhinolaryngol.* 2016;20:207-11.
6. Al-Khateeb T, Bataineh AB. Rhabdomyosarcoma of the oral and maxillofacial region in Jordanians: a retrospective analysis. *Oral Surg Oral Med Oral Pathol Oral Radiol Endodontol.* 2002;93:580-5.

7. Shrutha SP, Vinit GB. Rhabdomyosarcoma in a pediatric patient: A rare case report. *Contemp Clin Dent.* 2015;6:113.
8. Lee JH, Lee MS, Lee BH, Choe DH, Do YS, Kim KH, et al. Rhabdomyosarcoma of the head and neck in adults: MR and CT findings. *Am J Neuroradiol.* 1996;17:1923-8.
9. Derinkuyu BE, Boyunağa Ö, Öztunalı Ç, Tekkeşin F, Damar Ç, Alımlı AG, Okur A. Imaging features of Burkitt lymphoma in pediatric patients. *Diagnostic and Interventional Radiology.* 2016;22(1):95.
10. Inarejos Clemente EJ, Navallas M, Tolend M, Suñol Capella M, Rubio-Palau J, Albert Cazalla A, Rebollo Polo M. Imaging evaluation of pediatric parotid gland abnormalities. *Radiographics.* 2018;38(5):1552-75.
11. Sutow WW, Sullivan MP, Ried HL, Taylor HG, Griffith KM. Prognosis in childhood rhabdomyosarcoma. *Cancer.* 1970;25(6):1384-90.

**Cite this article as:** Joshi AR, Sankhe A, Patankar SH, Rahatgaonkar MM. Diagnostic dilemma in cheek lesions in the paediatric age group: thinking beyond the expected. *Int J Otorhinolaryngol Head Neck Surg* 2021;7:687-90.