

Case Report

Multiple amyloid lesions in the lateral pharyngeal wall: a case report

Andrés Clarós¹, Cristina Blebea², Pedro Clarós^{1*}

¹Department of Otolaryngology, Clarós Clinic, Barcelona, Spain

²Department of Otorhinolaryngology, ENT Scholarship, Clarós Clinic, Barcelona, Spain

Received: 21 January 2021

Accepted: 03 March 2021

***Correspondence:**

Dr. Pedro Clarós,

E-mail: clinica@clinicaclaros.com

Copyright: © the author(s), publisher and licensee Medip Academy. This is an open-access article distributed under the terms of the Creative Commons Attribution Non-Commercial License, which permits unrestricted non-commercial use, distribution, and reproduction in any medium, provided the original work is properly cited.

ABSTRACT

Amyloidosis represents a diverse group of disorders that have in common the deposition of amyloid protein in various extracellular tissues. Its clinical presentation may be systemic or localised. However, regions in the head and neck are rarely affected. This report discusses the case of a 57 year old man with a history of 6 years of left ear non-pulsatile tinnitus, who at the physical examination presented a polilobulated, yellowish oropharyngeal lesion, behind the left posterior pillar of the tonsil. Biopsy of the lesion sustained the diagnostic of light chain amyloidosis and subsequent evaluation was significant for establishing the diagnosis of localised amyloidosis. While further investigations a second laryngeal lesion was encountered. We present a case report of double synchronous amyloidosis localization on head and neck and asymptomatic lesions and discuss the implications for diagnosis and treatment.

Keywords: Amyloidosis, Pharynx, Larynx, Upper aerodigestive tract

INTRODUCTION

Amyloidosis is the result of the accumulation of pathogenic amyloids, most of which are aggregates of misfolded proteins in a variety of tissues with an extracellular distribution.¹ Amyloid fibrils are protein homopolymers that adopt diverse conformations, occur naturally and perform specialized functions (e.g. pigment formation).²

In clinical practice there are 3 most frequent forms of amyloidosis, though there are many more described. The first type is primary/idiopathic, characterized by the presence of light chain immunoglobulin (abbreviated AL-amyloidosis) and can be associated to multiple myeloma. The second type amyloidosis is considered to be secondary to infections or inflammatory conditions. It is associated with high levels of C-reactive protein (CRP) and tumour necrosis factor α (TNF- α) which can occur during tuberculosis, Crohn disease, inflammatory bowel disease, rheumatoid arthritis or other connective tissue

disorder. These inflammatory response markers seem to accelerate the depositions of amyloid in the tissues. The third type is less frequent, it runs in the family with no other disease associated, therefore is considered a hereditary type of amyloidosis.³

The modern era brought a consistent development of methods to solubilize amyloid fibrils therefore amyloidosis is now classified chemically. When for example the fibril protein involved in determining the pathology is an immunoglobulin light chain, patients are now considered to have AL-amyloidosis. Names such as AL describe the protein (light chain), but not necessarily the clinical phenotype.⁴

CASE REPORT

We present a case of a 57 year old man, previously healthy, which came to our clinic with 6 years of tinnitus history in the left ear with intermittent sensation of occluded ear with no otalgia or hearing loss associated.

The otoscopy showed the tympanic membrane presented a third grade retraction with no signs of cholesteatoma. During the physical exam, on the left lateral pharyngeal wall we identified a pale yellowish lesion, firm, elongated and lobulated of approximately 2.5-3 cm×1.0 cm (Figure 1) that extended superiorly behind the soft palate, without invasion of torus tubarius or other rhinopharynx structures and inferiorly up to the level of the free margin of the epiglottis. Audiological measures revealed. He denied dysphagia, odynophagia, haemoptysis or hoarseness.

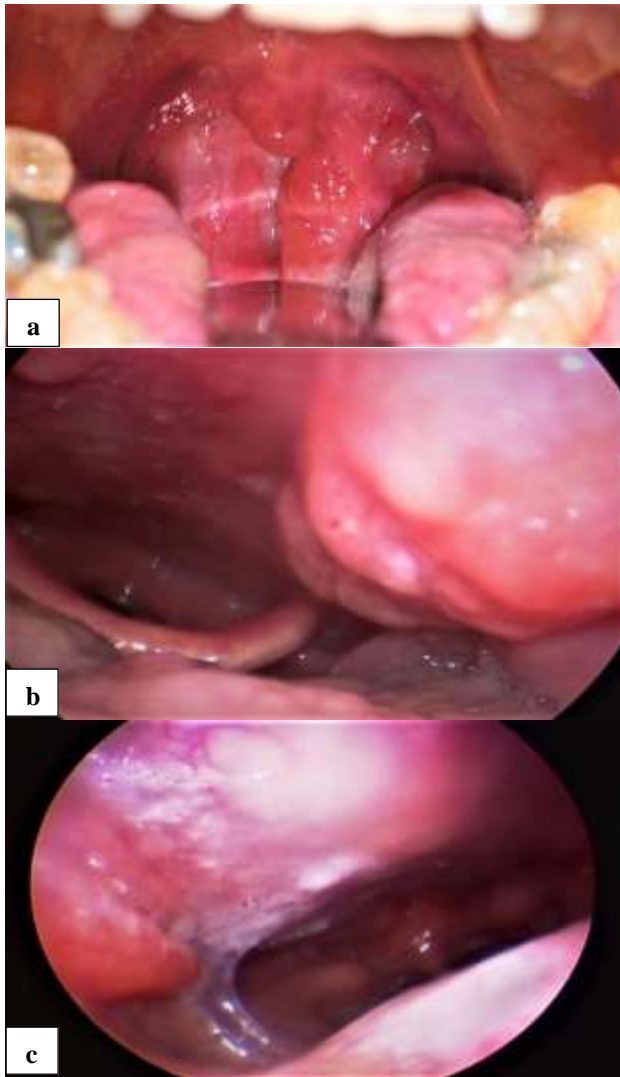


Figure 1 (a-c): The extent of the pharyngeal lesion.

Before proceeding with the biopsy of the lesion, we recommended a magnetic resonance (MRI) in order to establish the extension of it and implication of adjacent structures. Following, we performed a computer tomography (CT) and with these two complementary imaging tests, we were able to identify neither the left pharyngeal wall mass with an invasion of the The patient underwent a suspended microlaryngoscopy and CO₂ laser-assisted phonosurgical resection of the mass situated on the ventricular fold. A transoral

parapharyngeal space nor any contact with the ipsilateral carotid artery. Office-based biopsy from the friable, poorly vascularised mass lesion yielded evidence of subepithelial stromal material concerning for amyloid. Congo red stain was positive and apple-green birefringence in polarized light was present. Furthermore, kappa and lambda immunohistochemical analysis was used to ascertain intense expression of the lambda light chains and very low positivity for kappa light chain immunoglobulin, with no amyloid present. The results of the histopathological examinations were conclusive with an AL-amyloidosis type.

Once we had the histopathological result, we proceeded to discard any other related lesion in the head and neck region. We discovered a second lesion at the level of the posterior third of the right vestibular fold, with the same characteristics as the pharyngeal one. The lesion was well delimited, pale pink to yellow colour, round, with a 0.5 cm diameter (Figure 2). The patient presented no symptoms related to neither of the lesions. We did not identify any subglottic lesions and vocal cords had normal aspect and their movement and vibration was no impaired.

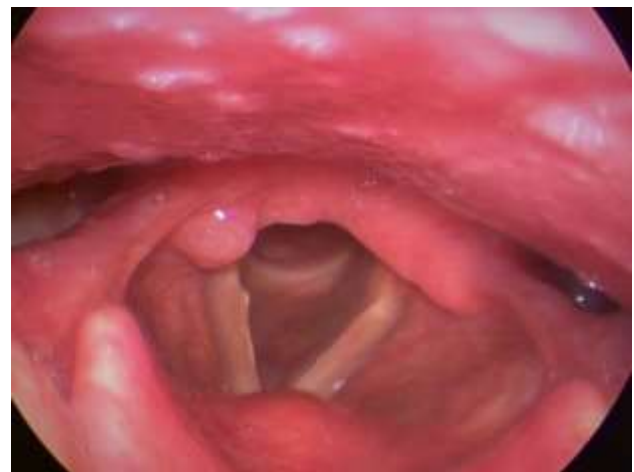

Figure 2: Laryngeal lesion on the posterior third of the right ventricular fold.

We mention that the patient is a non-smoker, but during the last month reported a 2 kg weight loss due to lack of appetite, had gastrointestinal problems for which he underwent an ultrasonography 3 month earlier with no pathologic modifications, and also a colonoscopy in the last 4 years during which colon polyps were detected but with no pathology involved.

The serum protein electrophoresis pattern was normal and a 24-hour immunofixation urine test detected no monoclonal immunoglobulin, therefore a systemic disease was excluded.

approach was used for the pharyngeal lesion and a CO₂ laser-assisted resection of the mass was achieved, with no surgical complications.

One week after surgery, the sutures were removed. Both surgical sites presented a favourable evolution, the patient presented no discomfort while swallowing, with no aspiration, no dysphonia, dysphagia or odynophagia, no haemoptysis.

DISCUSSION

From a clinical standpoint, amyloidosis may be classified as a localized or systemic disease. Amyloidosis with fibril-forming monoclonal immunoglobulin light chains (LC) sedimentation, most commonly of lambda isotype (AL amyloidosis), is the most common type of systemic amyloidosis, and has a greater incidence in developed countries.⁵

Systemic amyloidosis predominantly affects older patients and localized disease is more frequent in young patients. Although 85% of all amyloidosis is systemic, most cases involving the head and neck are localized AL type amyloidosis, as it was the case of our patient. Considering that pharyngeal AL amyloidosis is strongly associated with multiple myeloma, immediate evaluation for systemic disease was required.

Localized disease present throughout the head and neck region has as most common site of deposition the larynx, while other locations within the head and neck are limited. The incidence of the disease is limited. Therefore most of the cases located in the head and neck region are presented as case reports.

We present a case of localised amyloidosis with two head and neck synchronous sites, diagnosed in an apparent healthy male following biopsy of a pharyngeal lesion.

Sataloff in 2001 and Passerotti in 2008 each present the case of a man with laryngeal amyloidosis who also associated tracheal, pharyngeal and tongue masses consistent with amyloid deposition.^{6,7} Other cases with multiple lesions along the aerodigestive tract were described, but they were associated to a systemic form of the disease which it seems less frequent.⁸ Our patient presented multiple amyloid lesions, pharyngeal and supraglottic, with no related symptomatology at clinical presentation and did not associate any systemic manifestation of the disease.

While amyloidosis is a very heterogeneous disease, the first step in initialising the treatment is to establish if the disease is systemic or localised. Because accumulation of amyloid fibrils is destroying normal structure and function of the tissues involved, systemic amyloidosis carries a poor prognosis than the localized forms.

The mainstay of treatment for localised amyloidosis is conservative resection, either with cold instruments or

CO2 laser-assisted. Systemic therapies have not been introduced for the localised forms of the disease, therefore long-term follow up is essential because recurrence of the disease is a possibility not just in the systemic presentation but also in the localised one, and it will require further treatment.⁹

CONCLUSION

Though a rare disease, amyloidosis is not uncommon. It is important for otolaryngologists to be aware of this entity, with unspecific or non-symptomatic clinical presentation and recognize the need for punctual diagnosis and evaluation for systemic disease.

Funding: No funding sources

Conflict of interest: None declared

Ethical approval: Not required

REFERENCES

1. Chiti F, Dobson CM. Protein misfolding, functional amyloid, and human disease. *Annu Rev Biochem.* 2006;75:333-66.
2. Chuang E, Hori AM, Hesketh CD, Shorter J. Amyloid assembly and disassembly. *J Cell Sci.* 2018;131(8):86-90.
3. Pietruszewska W, Wągrowaska-Danilewicz M, Klatka J. Amyloidosis of the head and neck: a clinicopathological study of cases with long-term follow-up. *Arch Med Sci.* 2014;10(4):846-52.
4. Westermark P, Benson MD, Buxbaum JN, Cohen AS, Frangione B, Ikeda S, et al. A primer of amyloid nomenclature. *Amyloid.* 2007;14(3):179-83.
5. Desport E, Bridoux F, Sirac C, Delbas S, Bender S, Fernandez B, et al. AL amyloidosis. *Orphanet J Rare Dis.* 2012;7(1):54.
6. Sataloff RT, Abaza M, Abaza NA, Markiwicz A, Hawkshaw M. Amyloidosis of the larynx. *Ear Nose Throat J.* 2001;80(6):369-70.
7. Passerotti GH, Caniello M, Hachiya A, Santoro PP, Imamura R, Tsuji DH. Multiple-sited amyloidosis in the upper aerodigestive tract: case report and literature review. *Braz J Otorhinolaryngol.* 2008;74(3):462-6.
8. Gilad R, Milillo P, Som PM. Severe Diffuse Systemic Amyloidosis with Involvement of the Pharynx, Larynx, and Trachea: CT and MR Findings. *Am J Neuroradiol.* 2007;28(8):1557-8.
9. Pribitkin E, Friedman O, O'Hara B, Cunnane MF, Levi D, Rosen M, et al. Amyloidosis of the upper aerodigestive tract. *Laryngoscope.* 2003;113(12):2095-101.

Cite this article as: Clarós A, Blebea C, Clarós P. Multiple amyloid lesions in the lateral pharyngeal wall: a case report. *Int J Otorhinolaryngol Head Neck Surg* 2021;7:875-7.