

Original Research Article

An observational study of endoscopic versus microscopic type I tympanoplasty in tubotympanic chronic otitis media in a tertiary health care centre

Amrita Chowdhury*, Shatabdi Das

Department of Otorhinolaryngology and Head and Neck Surgery, Agartala Government Medical College, Agartala, Tripura, India

Received: 12 January 2021

Revised: 10 February 2021

Accepted: 12 February 2021

***Correspondence:**

Dr. Amrita Chowdhury,

E-mail: dramrita462@gmail.com

Copyright: © the author(s), publisher and licensee Medip Academy. This is an open-access article distributed under the terms of the Creative Commons Attribution Non-Commercial License, which permits unrestricted non-commercial use, distribution, and reproduction in any medium, provided the original work is properly cited.

ABSTRACT

Background: Chronic otitis media (COM) is a widespread disease in the developing countries. It is treated by tympanoplasty, traditionally performed with the microscope which limits the visual field in the deep recesses of the middle ear, especially in narrow external auditory canal. Using endoscope has minimised these difficulties by providing a wide field view with angled magnification, reducing the duration of surgery. The advantages and disadvantages of both techniques is evaluated in our study.

Methods: In this observational study, 60 patients of tubotympanic COM between 12-60 years of age with small to medium sized central perforation and air-bone gap of less than 45 decibel were included. They were divided into two groups (group A and group B) of 30 patients each. Group A underwent microscopic type 1 tympanoplasty and group B underwent endoscopic type 1 tympanoplasty. The duration of the surgery, the post-operative improvement in hearing and the graft uptake was analysed after 3 months of surgery. The post-operative hospital stay duration was noted.

Results: The post-operative hearing improvement and the graft uptake after 3 months of the surgery was statistically not significant between the two groups. But the mean duration of the operation and the post-operative hospital stay was significantly lower in the endoscopic group with a p value <0.05.

Conclusions: Endoscopes are better in otological procedures as it reduces the surgical duration, provides better visibility, lessens the post-operative hospital stay, reducing the economic burden of the patient.

Keywords: Chronic otitis media, Tubotympanic, Type I tympanoplasty

INTRODUCTION

Chronic otitis media (COM), previously known as chronic suppurative otitis media (CSOM) is a wide spread disease in the developing countries. It was defined by World Health Organization (WHO) foundation workshop in 1996 as “a stage of ear disease in which there is chronic infection of the middle ear cleft i.e. eustachian tube, middle ear and mastoid, and in which a non-intact tympanic membrane and discharge are present”.¹ Incidence of COM is higher in developing countries because of poor socio-economic

standards, poor nutrition and lack of health education. It affects both the sexes and all the age groups.² Tariq et al in his recent study done in 2015 reported that malnutrition, overcrowding, substandard hygiene, frequent URTI and under-resourced health care (all linked to low socio-economic status) are the risk factors for developing CSOM.³ In India, the overall prevalence rate is 46 and 16 per 1000 in rural and urban population respectively. It is also the single most important cause of hearing impairment in rural population. It follows acute otitis media and the causes of this progression to chronicity are mainly mixed

infections with both aerobic and anaerobic organisms, low resistance of patients, lack of awareness, inadequate treatment and eustachian tube dysfunction. Two groups of COM have been identified which includes tubotympanic known as the safe or benign type involving the antero-inferior part of the middle ear cleft and is associated with a central perforation. Here the patient often presents with non-foul smelling mucoid or muco-purulent profuse discharge accompanied with earache and hearing loss. Sometimes, the ear may be completely dry for long periods with only intermittent discharge. The other variant is the attico-antral type, which is the unsafe or the complicated type involving the postero-superior quadrant of the middle ear cleft.² The study done by Orji showed that social embarrassment from frequent ear discharges as well as hearing loss were identified by 88% and 71% of the respondents respectively as the major concerns of CSOM patients.⁴ Many of the cases of COM are treated by a surgical procedure called tympanoplasty. This consists of both eradication of the middle ear disease and reconstruction of hearing mechanism including the tympanic membrane and the ossicles.⁵ For a long time, it was performed with the assistance of microscope. But microscope offers a straight line view which limits the visual field in the deep recesses of the middle ear and hence creates difficulty for the surgeon especially if the external auditory canal (EAC) is narrow or protruding.⁶ Therefore, endoscopic tympanoplasty has emerged out to be an excellent alternative method since 1967 when it was first used by Mer and colleagues to describe the middle ear anatomy. As endoscopes offer a wide field angled view with magnification, so it is being increasingly preferred by surgeons to obtain an all-round vision which helps in looking behind the obstructions or overhangs and peering into the deep recesses of the middle ear with much less requirement for surgical exposure than demanded by conventional microscopic techniques.⁷ Karhuketo studied the endoscopic assisted type I tympanoplasty in 30 ears of 29 patients with different size perforation and concluded that the post-operative A-B gap was less than 10 dB in 90% of case and hence concluded that endoscopic assisted type I tympanoplasty is reliable and simple procedure with the benefit of minimal trauma to the healthy tissue.⁸ El-Guindy (Tanta, Egypt) evaluated the role of rigid endoscope in the management of 36 cases of dry central perforation and reported 91.7% graft uptake rate.⁹ Also, the operating time gets substantially reduced with endoscopic tympanoplasty. Dundar et al in his study reported that the operation duration among 26 patients who underwent endoscopic transcanal tympanoplasty was less than 51.37 minutes, and the mean duration was 69.03 minutes for the microscopic approach.¹⁰ But at the same time, endoscopes offer “fish eye view” and cannot provide the three dimensional view unlike binocular operating microscopes.⁷ In our present study we aimed to clearly evaluate and analyse the advantages and disadvantages of both the techniques to depict which of these will contribute to the maximum benefit and comfort of the patient as well as the surgeon.

METHODS

This prospective longitudinal study was carried out on patients attending the Department of Otorhinolaryngology at Agartala Government Medical College and GBP Hospital, Agartala, Tripura from October 2018 to October 2019 with tubotympanic COM with chief complaints of ear discharge and hearing loss. After taking written and informed consent, a detailed clinical examination of the ear, nose, throat was done and data was recorded in a predesigned questionnaire. Patients having central perforation were subjected to pure tone audiometry (PTA) with 500 Hz, 1 KHz, 2 KHz frequency and the air-bone gap (ABG) and the degree of hearing loss was determined by taking the average of these 3 frequencies. Tuning fork test with 256 Hz, 512 Hz and 1024 Hz was also done to know the type of hearing loss. Patients in the inactive stage of the disease with small to medium size central perforation of the tympanic membrane and an air-bone gap of less than 45 decibel were included in the study. However, patients not willing to participate in the study, or with associated cholesteatoma, active ear discharge, ossicular discontinuity or fixation, significantly narrow external auditory canal, revision surgeries, sensorineural hearing loss or eustachian tube dysfunction were excluded from the study. Diagnosis was further supplemented by X-ray mastoid (Schuller's view) and high resolution computed tomography of the temporal bone wherever necessary. X-ray of the paranasal sinus (Water's view) was also done. 60 patients in the age group of 12-60 years fulfilling the inclusion criteria were available for the study. They were divided into 2 groups. The first 30 patients were allocated to group A and the next 30 patients were allocated to group B consecutively. Group A underwent microscopic type 1 tympanoplasty while group B underwent endoscopic type 1 tympanoplasty. All surgeries were done through the transcanal route, and were performed under local anaesthesia. Temporalis fascia was used as the graft material in all cases. Carl Zeiss microscope (OPMI PICO) was used for microscopic tympanoplasty, while 0 degree and 30 degree, 4 mm wide and 18 cm long Karl Storz rod otoendoscope along with a 3 chip camera high definition video (monitor) system was used for endoscopic tympanoplasty. Endoscopic surgeries were performed under direct visualization on the monitor. All patients were given a prophylactic stat dose of injectable antibiotic and were pre-medicated with 30 mg of pentazocine (30 mg/ml) and 50 mg of promethazine hydrochloride (25 mg/ml) intravenously. After positioning the patient followed by preparation and draping of the surgical area, dryness of the middle ear was confirmed preoperatively. Temporalis fascia graft was harvested after giving local anaesthesia using 2% lignocaine mixed with 1 in 10,000 adrenaline injection. The EAC is then infiltrated using 0.5 ml of the same anaesthetic solution at 3 o'clock, 6 o'clock, 9 o'clock and 12 o'clock positions about 3 mm from the annulus. After freshening the margins of perforation, a curvilinear incision is made 6mm lateral to the annulus posteriorly from 6 o'clock to 12 o'clock position and the tympanomeatal flap is elevated. The

middle ear is inspected for any disease and the annulus is gradually lifted from its rim and the handle of malleus is exposed, the tympanomeatal flap is released and the handle of malleus is freshened. The dried temporalis fascia graft of appropriate size is then placed using the underlay technique and the tympanomeatal flap repositioned. Gel foams are placed around the edges of the flap and a wick medicated with 1% framycetin ointment is kept in the EAC followed by sterile dressing of the wound. The mean duration of the surgery was noted for both groups separately. Post operatively patients were started on third generation cephalosporins and the operative wound was checked and dressed the next day. All patients were discharged on oral antibiotics over 1 week and called for regular follow up. The duration of hospital stay for each patient after the surgery was recorded for both groups. Sutures were removed on the 7th postoperative day. Patients were called for regular follow up periodically. For the first month, they were followed weekly and then twice in a month for the next 2 months. During follow-up, all patients were examined for pain, hearing improvement, graft uptake. However, the final assessment of the graft uptake and the hearing improvement was done by PTA after 3 months, where the ABG was calculated by taking the average of the 3 frequencies 500 Hz, 1 KHz, 2 KHz. Successful results were considered if there was complete graft uptake with postoperative ABG less than or equal to 15 decibel. The patients in the two groups were assessed on the basis of mean time duration of the surgical procedure; duration of post-operative stay in the hospital; graft uptake and hearing improvement. The results of mean time duration of the surgical procedure; and hearing improvement were analysed by unpaired student's t test and duration of post-operative stay in the hospital along with the results of graft uptake were analysed by Chi square test.

RESULTS

In our study, we observed that most of the patients presenting with tubotympanic COM belonged to age group of 21-30 years (Figure 1). The patients were mainly from the rural population (67%) (Figure 2) and lower socio-economic strata (70%) (Figure 3) with chief complaints of otorrhea (48.3%), hearing impairment (35%), followed by tinnitus (16.7%) (Figure 4). On otoscopic examination, no significant abnormality was noted in the EAC. On PTA, all patients had moderate conductive hearing loss i.e. 30-45 dB of ABG at frequency of 0.5, 1 and 2 KHz. X-ray mastoid (Schuller's view) and X-ray paranasal sinus (Water's view) was done to exclude mastoiditis and sinusitis respectively.

Surgery was performed in both groups and the mean duration of surgery was recorded which was found to be 77.23 minutes in group A and 62.87 minutes in group B, with a statistically significant p value of 0.000 as analyzed by unpaired student's t-test (Table 1). It was also seen that in group B (n=30), 90% of patients did not have any postoperative morbidity and were discharged within 3

days of the surgery, while in group A (n=30), only 30% of patients did not complain of any postoperative morbidity and were discharged within 3 days of the surgery. The results were analyzed using chi square test and was found to be statistically significant with a p value of 0.000 (Table 2). After discharge, patients were kept on regular follow-up periodically and the final assessment of the graft uptake and hearing improvement was done after 3 months of the surgery. On examination, it was observed that in group A (n=30), 80% of the patients had successful graft uptake and 90% patients in group B had successful graft uptake. The results as analyzed by Chi-square test were not statistically significant (Table 3). On PTA with 0.5, 1 and 2 KHz after 3 months of surgery, it was observed that in group A (n=30), 86.7% of the patients had ABG of ≤15 dB and 13.3% patients had ABG of >15 dB. This was almost equal to group B (n=30) where 83.3% of patients showed hearing improvement with ABG of ≤15 decibel and 16.7% showed no hearing improvement. However the results between the 2 groups were not found to be statistically significant (Table 4).

Table 1: Mean operative duration.

Operative duration	Microscopic	Endoscopic	P value
Mean time in min	77.23	62.87	0.000

Table 2: Post-operative stay.

Post-operative stay (days)	Microscopic group (n=30)	Endoscopic group (n=30)	P value
<3	9	27	0.000
>3	21	3	

Table 3: Post-operative graft uptake.

Post-operative graft uptake	Microscopic group (n=30) %	Endoscopic group (n=30) %	P value
Successful	24 (80)	27 (90)	0.278
Unsuccessful	6 (20)	3 (10)	

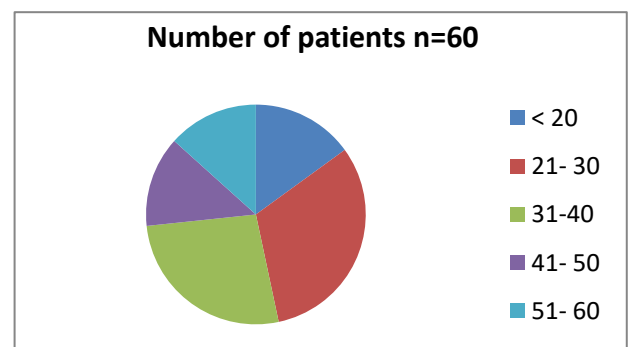


Figure 1: Distribution of patients according to age groups.

Table 4: Post-operative hearing improvement.

Postoperative A-B gap (dB)	Microscopic group (n=30) %	Endoscopic group (n=30) %	P value
≤15	26 (86.7)	25 (83.3)	0.7
>15	4 (13.3)	5 (16.7)	

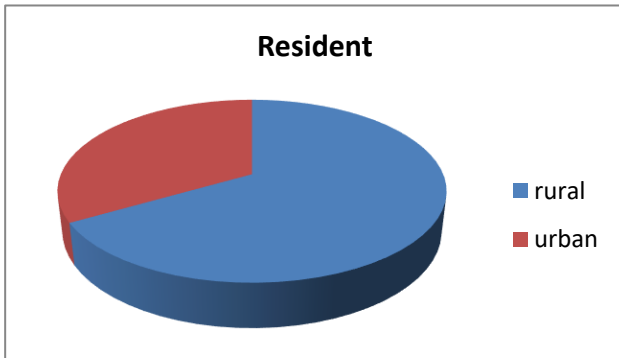


Figure 2: Residential status of the patients participating in the study.

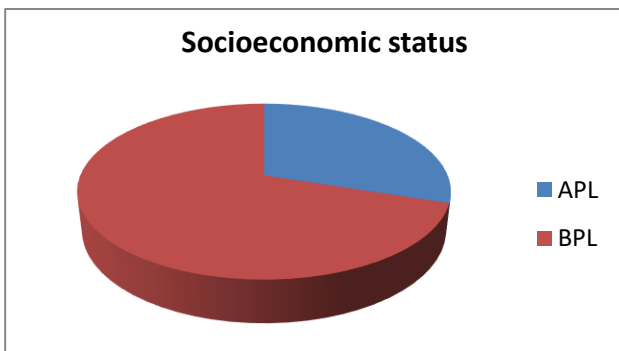


Figure 3: Socio-economic status of the patients participating in the study.

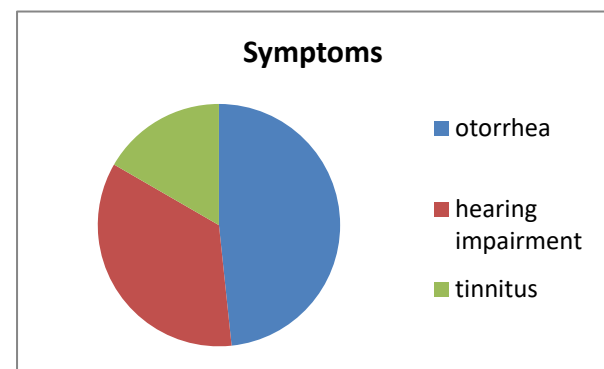


Figure 4: Clinical presentation.

DISCUSSION

In this study, it was observed that the highest incidence of tubotympanic COM was found in the age group of 21-30 years. The youngest patient was a 13 years old boy who presented with otorrhea and a medium sized central

perforation of the ear, and the oldest was a 58 years old male presenting with otorrhea along with hearing impairment and a medium sized central perforation for a prolonged duration. It was seen that the incidence has decreasing tendency with the increase in age. This is in consistence with the study reported by Rakesh et al, Raghu et al and Harvinder et al who stated that maximum patients of chronic suppurative otitis media were in the age group of 16-30 years.^{11,12} Okafor in 1984 stated that the prevalence of CSOM decreased with increasing age.^{13,14} In a study done by Kabdwal et al showed that the most commonly affected age group of CSOM was between 21-30 years. This early presentation may be due to increased awareness to health issues and difficulty in hearing affecting work efficiency, leading patients and parents to seek early medical intervention.¹⁵

We observed that the disease is more prevalent in males than females which is similar to other studies done in Singapore, Pakistan, Iran and other parts of India.¹⁶ Siraj et al in his study reported that the prevalence of CSOM was found to be slightly higher in male children than female.¹⁷ Islam in 2007, in his study revealed that the male to female ratio regarding the prevalence of the disease is much higher. This might be due to increased prevalence of chronic suppurative otitis media among the males or it might be simple reflection of overall high male attendance in hospital.¹⁸

Our study showed that COM is more common in rural population especially affecting the lower socio-economic strata, which is quite similar to a study made by Okafor et al who stated that the majority of the patients with chronic ear disease came from poor communities living in subsistence agricultural or slum areas.¹⁶ In a study conducted by Arunabha et al 60% of their patients were from low socio-economic class. Poor living conditions, poor access to medical care, inadequate medical treatment, recurrent upper respiratory tract infections, nasal diseases have been recognized as risk factors for COM.¹⁹

We found that majority of the patient presented with otorrhea (48.3%) followed by hearing impairment in 35% and tinnitus (16.7%). This is in accordance to a similar study done by Nishant et al where the commonest complaint of tubotympanic COM was observed to be otorrhea, followed by hearing impairment which is very well with the view of many authors.²⁰ Akinpelu in his study found that tubotympanic disease was more common with otorrhea as the most common symptom at presentation, followed by hearing impairment.¹³ In the present study, we found that majority of the patients (55%) presented with perforation in the right tympanic membrane, while 45% of them presented with a left tympanic membrane perforation, as because patients with bilateral perforation were not included in the study. This was contrary to study done by Leandro et al, which had 59% of patients presenting with a perforation in left tympanic membrane and 36.3% of patients with right tympanic membrane perforation.²¹

In this study, among the total 60 patients who fulfilled the inclusion criteria, 30 patients were subjected to endoscopic type I tympanoplasty and another 30 patients to microscopic type I tympanoplasty. The minimum pre-operative ABG was found to be 30 dB while 45 dB was the maximum ABG pre-operatively as seen on PTA. At 3 months of post-operative follow up, among patients who underwent endoscopic type I tympanoplasty, 83.3% had post-operative ABG of ≤ 15 dB while 16.7% had > 15 dB. In patients undergoing microscopic type I tympanoplasty, 86.7% had post-operative ABG of ≤ 15 dB and 13.3% had > 15 dB. So the post-operative ABG was almost comparable in both the groups. In a study done by Patel et al, at 3 months of follow up in endoscopic type I tympanoplasty, 45.45% of patients had post-operative ABG in the range of 0-10dB, and 50% patients had post-operative ABG in the range of 11-20 dB. While in patients of microscopic type I tympanoplasty, 45.45% of patients had post-operative ABG in the range of 0-10 dB and 36.36% in the range of 11-20 dB.¹⁰ Similarly, in another study by Jana et al, in microscope assisted type I tympanoplasty, 89% had an improvement in conductive hearing loss with average between 0 and 20dB which was equal in the endoscopic group as well.²²

In our study, the post-operative graft uptake in case of endoscopic type I tympanoplasty is 90%, whereas in microscopic group, it is 80%. Raj and Meher et al in their study on endoscopic transcanal type I tympanoplasty, compared the outcomes with that of microscopic type I tympanoplasty and showed that graft uptake is 90% in endoscopic method and 85% in microscopic method.²³ In a study done by Dundar et al, the graft success rate in the endoscopic tympanoplasty was 87.5%, while in the microscopic approach, it was 94.3%.¹⁰ Hence, we can conclude that both microscopic and endoscopic type I tympanoplasty gives almost comparable results regarding the functional outcome of the surgery.

Duration of the operation is an important parameter in terms of duration of anaesthesia, the surgeon's concentration, and the increased risk of iatrogenic complications.²⁴ In the present study, the mean duration of operation in case of endoscopic type I tympanoplasty was 62.87 minutes, which was much lesser as compared to the microscopic type I tympanoplasty (77.23 minutes). In a study conducted by Choi et al, mean duration of operation for microscopic group (88.9 \pm 28.5 minutes) was significantly longer than the endoscopic group.¹⁸ In a study done by Ambani et al, the average time taken was around 1 hour 30 minutes for the endoscopic group.²⁵ The reason for this difference in the duration of operation as stated by Osama et al may be related to the fact that no extra time is required to view the hidden areas during the endoscopic procedures.²⁴ Therefore, endoscopic type I tympanoplasty is a much less time consuming procedure with better visibility as compared to microscopic type I tympanoplasty.

Also the post-operative hospital stay is very minimal in endoscopic type I tympanoplasty than microscopic type I tympanoplasty because of less postoperative morbidities. This can be attributed to the fact that endoscope provides a wide angled view of the tympanic membrane and the middle ear structures, so there is minimal trauma to the adjacent ear structures which leads to less pain and better wound healing of the graft as well as the surrounding tissues, especially the EAC. Our finding was further supported by a similar study done by Patel et al, where he stated that while operating the patients with microscope, tortuosity of the EAC and bony overhang hamper the view of the deeper structures. Because of which, there was a need to frequently manipulate the head of the patient, and in some cases, even canalplasty becomes mandatory to view the deeper structure, leading to more tissue injury and pain. In contrast, the endoscope brings surgeon's eye to the tip of the scope. The wide angle of the scope brings the tympanic membrane in one frame, and magnifies the image. Thus, there is no need of frequently manipulating patients head and canalplasty can also be avoided.²⁶ Lade et al compared 60 patients undergoing type I tympanoplasty using either a microscopic or endoscopic procedure. Among the 30 patients who underwent the microscopic approach, canalplasty was performed to evaluate the ossicular system in 5 and EAC curettage was performed in 4 patients. However, none of the 30 patients who underwent the endoscopic procedure required such interventions, and the ossicular system could be assessed easily. They concluded that the results of endoscopic tympanoplasty are similar to those of microscopic tympanoplasty and that endoscopic tympanoplasty is more tolerable in terms of cosmetic outcome.²⁷ Thus endoscopic type I tympanoplasty is considered as the safe minimally invasive alternative to microscopic type I tympanoplasty due to better cosmetic outcome, better visibility and lesser need for any further interventions.

CONCLUSION

Endoscopic type I tympanoplasty is a fast developing concept and thus gaining popularity day by day. The primary advantage of this technique is its ability to address the middle ear disease and the tympanic membrane perforation associated with COM under improved visualization, and magnification, in less duration of operation time. Thus it yields better surgical outcome with fewer post-operative morbidities. Moreover, endoscopes also serve as an excellent teaching tool when used in conjunction with video monitors. Thus, we can conclude that endoscopic tympanoplasty has many additional advantages as compared to microscopic type I tympanoplasty, and can be very well adopted as a newer approach for tympanoplasty in this modern era.

Funding: No funding sources

Conflict of interest: None declared

Ethical approval: The study was approved by the Institutional Ethics Committee

REFERENCES

- Gadag RP, Godse A, Narasaiah MD, Shetty N, Salian PL. Comparative study of outcomes of microscopic versus endoscopic myringoplasty. *Med Inn.* 2016;5(1):3-6.
- Hussain Z. Mucosal chronic otitis media. In: Nair S (Ed). *Otorhinolaryngology.* 4th ed. Hyderabad: Paras. 2018;125-40.
- Zahid T, Ahmed Z, Aqeel Z. Microbiology of chronic suppurative otitis media (CSOM) in tertiary care setup, Civil Hospital Karachi, Pakistan. *Pak J Surg.* 2016;32(3):176-80.
- Orji F. A survey of the burden of management of chronic suppurative otitis media in a developing country. *Ann Med Health Sci Res.* 2013;3(4):598-601.
- Bansal M. *Middle Ear and Mastoid Surgeries. Essentials of Ear, Nose & Throat.* 1st ed. New Delhi: Jaypee. 2016;438-9.
- Huang TY, Ho KY, Wang LF, Chien CY, Wang HM. A comparative study of Endoscopic And Microscopic Approach Type 1 Tympanoplasty for Simple Chronic Otitis Media. *J Int Adv Otol.* 2016;12(1):28-31.
- Sismanis AA. Tympanoplasty: tympanic membrane repair. In: Gulya AJ, Minor LB, Poe DS (Eds). *Glasscock and Shambaugh Surgery of the Ear.* 6th ed. Shelton: PMPH-USA. 2010;465-86.
- Karhuketo TS, Puhakka HJ. Endoscope- guided round window fistula repair. *Otol Neurotol.* 2001;22(6):869-73.
- Guindy A. Endoscopic transcanal myringoplasty. *J Laryngol Otol.* 1992;106(6):493-5.
- Dündar R, Kulduk E, Soy FK, Aslan M, Hanci D, Muluk NB, Cingi C. Endoscopic versus microscopic approach to type 1 tympanoplasty in children. *Int J Pediatr Otorhinolaryngol.* 2014;78(7):1084-9.
- Khatoon A, Rizvi M, Sultan A, Khan F, Sharma M, Shukla I, Khan HM. Chronic suppurative otitis media: a clinico-microbiological menace. *Int J Res Med Sci.* 2015;3(8):1932-6.
- Kumar KR, Navya S, Basavarajappa KG. A study of Bacterial Profile and Antibiotic susceptibility Pattern of Chronic Suppurative Otitis Media among patients attending a Tertiary Care Centre, Davengere. *Sch J App Med Sci.* 2014;2(5B):1606-12.
- Akinpelu OV, Amusa YB, Komolafe EO, Adeolu AA, Oladele AO, Ameye SA. Challenges in management of chronic suppurative otitis media in a developing country. *J Laryngol Otol.* 2008;122(1):16-20.
- Okafor BC. Otolaryngology in South-Eastern Nigeria I. Pattern of disease of the ear. *Niger Med J.* 1983;13:11-9.
- Kabdwal N, Varshney S, Bist SS, Bhagat S, Mishra S, Agarwal V. Pre and post-operative evaluation of hearing in chronic suppurative otitis media. *Indian J Otol.* 2013;19(4):164-8.
- Darad H, Sinha M. Aetiological factor for chronic suppurative otitis media: a retrospective study. *Int J Otorhinolaryngol Head and Neck Surg.* 2017;3(2):234-8.
- Zakzouk SM, Hajjaj MF. Epidemiology of chronic suppurative otitis media among Saudi children—a comparative study of two decades. *Int J Pediatr Otorhinolaryngol.* 2002;62(3):215-8.
- Islam MS, Islam MR, Bhuiyan MA, Rashid MS, Datta PG. Pattern and degree of hearing loss in chronic suppurative otitis media. *Bangladesh J Otorhinolaryngol.* 2010;16(2):96-105.
- S H C, M M K, Handi P, Khavasi P, Doddmani SS, Riyas M. To Study the Level of Awareness About Complications of Chronic Suppurative Otitis Media (CSOM) in CSOM Patients. *J Clin Diagn Res.* 2014;8(2):59-61.
- Kumar N, Chilke D, Puttewar MP. Clinical Profile of Tubotympanic CSOM and Its Management With Special Reference to Site and Size of Tympanic Membrane Perforation, Eustachian Tube Function and Three Flap Tympanoplasty. *Indian J Otolaryngol Head Neck Surg.* 2012;64(1):5-12.
- Garcia Lde B, Moussalem GF, Andrade JS, Mangussi-Gomes J, Cruz OL, Penido Nde O, Testa JR. Transcanal endoscopic myringoplasty: a case series in a university center. *Braz J Otorhinolaryngol.* 2016;82(3):321-5.
- Jana S, Mandal S. A Comparative Study of Microscopic and Endoscopic Type I Tympanoplasty. *Int J Contemp Med Res.* 2018;5(10):11-4.
- Raj A, Meher R. Endoscopic transcanal myringoplasty-A study. *Indian J Otolaryngol Head Neck Surg.* 2001;53(1):47-9.
- Awad OG, Hamid KA. Endoscopic type 1 tympanoplasty in pediatric patients using tragal cartilage. *JAMA Otolaryngol Head Neck Surg.* 2015;141(6):532-8.
- Subramanya BT, Lohith S, Sphoorthi B. Endoscopic myringoplasty: outcome and hearing gain in inactive mucosal chronic otitis media. *Int J Otorhinolaryngol Head Neck Surg.* 2019;5(2):330-5.
- Patel J, Aiyer RG, Gajjar Y, Gupta R, Raval J, Suthar PP. Endoscopic tympanoplasty vs microscopic tympanoplasty in tubotympanic CSOM: a comparative study of 44 cases. *Int J Res Med Sci.* 2015;3(8):1953-7.
- Lade H, Choudhury SR, Vasistha A. Endoscopic versus Microscopic Myringoplasty: A different perspective. *Eur Arch Otorhinolaryngol.* 2014;271:1897-902.

Cite this article as: Chowdhury A, Das S. An observational study of endoscopic versus microscopic type I tympanoplasty in tubotympanic chronic otitis media in a tertiary health care centre. *Int J Otorhinolaryngol Head Neck Surg* 2021;7:434-9.