

## Case Report

# Hearing loss in a post COVID-19 patient

Sayan Chakraborty<sup>1</sup>, Sayan Maharatna<sup>1</sup>, Chandra Shekar Reddy<sup>2</sup>,  
Gaurav Gupta<sup>1</sup>, Upendra Baitha<sup>1</sup>, Pankaj Jorwal<sup>1</sup>, Ashutosh Biswas<sup>1\*</sup>

<sup>1</sup>Department of Medicine, <sup>2</sup>Department of ENT, All India Institute of Medical Sciences, New Delhi, India

**Received:** 06 January 2021

**Accepted:** 11 February 2021

### \*Correspondence:

Dr. Ashutosh Biswas,

E-mail: drashutoshbiswas@gmail.com

**Copyright:** © the author(s), publisher and licensee Medip Academy. This is an open-access article distributed under the terms of the Creative Commons Attribution Non-Commercial License, which permits unrestricted non-commercial use, distribution, and reproduction in any medium, provided the original work is properly cited.

## ABSTRACT

With the advent of COVID-19 pandemic, there has been a myriad of long-term complications in post-COVID patients. In these patients, one of the rare but dreaded symptoms reported is sudden onset sensorineural hearing loss (SNHL) that has been reported mostly during active infection. We followed up with these patients in our outpatient department and came across one patient of SNHL. We conducted a literature search in PubMed and Google Scholar but couldn't come across any such care report from India. We are hereby reporting the first case of SNHL in a post-hospitalised COVID-19 from India presenting after 3 months of hospital discharge, with no history prior otologic illness, intake of ototoxic drugs or any head injury. Post-COVID patients can present with weird symptoms including hearing loss apart from other commonly reported post COVID 19 sequelae.

**Keywords:** Coronavirus, COVID-19, SARS-CoV-2, Hearing loss, Sensorineural deafness

## INTRODUCTION

The World Health Organisation (WHO) declared the Coronavirus disease 2019 (COVID-19) caused by severe acute respiratory syndrome coronavirus-2 (SARS-CoV-2) as a global pandemic on March 11<sup>th</sup>, 2020.<sup>1</sup> As on 27<sup>th</sup> December, 2020, there have been more than 80.7 million cases with close to 1.7 million deaths globally. India has witnessed more than 10.1 million cases with around 147,600 deaths.<sup>2</sup>

Since the beginning of the pandemic since December, 2019 in Wuhan, China, there has been a myriad of clinical presentations of the COVID-19. There has been certain number of case reports and reviews published on otorhinolaryngological presentations of COVID-19. Other than the frequently reported symptoms like anosmia, sore throat, ageusia, nasal congestion etc, there has been reports of otalgia, tinnitus and Bell's palsy. One of the rare but dreaded symptoms reported is sudden sensorineural hearing loss (SNHL). This has been reported mostly as index presentation.<sup>3</sup>

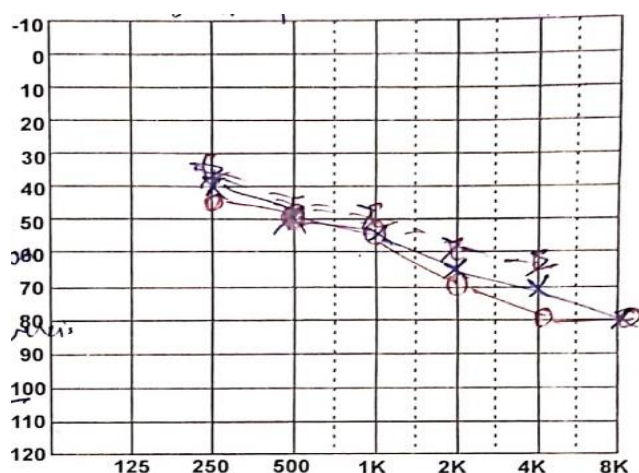
In the post-COVID patients, dreaded complication of sudden onset sensorineural hearing loss (SNHL) has been reported mostly during active infection. We followed up with these patients in our outpatient department and came across one patient of SNHL. We conducted a literature search in PubMed and Google Scholar but couldn't come across any such care report from India. We are hereby reporting the one of the earliest cases of SNHL in a post-hospitalised COVID-19 from India.

## CASE REPORT

A written informed consent was obtained from the study participant. He is a 49 years old diabetic since last 14 years, working as a sanitation assistant in our hospital, presented with body ache, malaise and shortness of breath on exertion in the last week of May 2020. 2 days later he developed loss of smell and taste sensation. His nasal and throat swab for SARS-CoV-2 RT PCR came positive. He was admitted for isolation and monitoring. On day 1 of admission, he had fever spikes of 102°F. Day 3 onwards he was afebrile. But he developed loose motions which persisted for 3 days with 4-5 episodes per

day. He also developed a dry cough which persisted for more than a week. His chest X ray and routine blood investigations revealed no abnormality. He was discharged on day 13 of admission with residual symptoms of fatigue and cough. His sense of smell and taste came back to normal at the time of discharge and later became totally asymptomatic. Two months later, he complained of easy fatigability and shortness of breath on exertion with subsided gradually. Another month later, he noticed hearing difficulty when called from a distance. There was no history of decreased hearing, fullness in ears, pain or any discharge from ears, no history of associated vertigo or tinnitus. There was no history of recent or recurrent upper respiratory tract infections, trauma or prolonged exposure to occupational noise.

On otoscopic examination, external auditory canal and tympanic membrane revealed no abnormality. Weber's test was normal, not lateralizing to any ear. Rinne's test was positive in both the ears i.e., air conduction was more than bone conduction. Pure tone audiometry revealed moderate to severe SNHL in both the ears (Figure 1).



**Figure 1: Pure Audiometry of the patient.**

MRI brain was performed which revealed no abnormality. No space occupying lesions found close to the auditory pathway, middle ear cavity and the ear ossicles were within normal limit. Recent haematological parameters and routine biochemistry reports were within normal limit. However, his HbA<sub>1c</sub> was 10 suggesting a poor glycaemic control. Such rapid deterioration in a narrow window of time (1 month) cannot be attributed to diabetes only as seen in this patient. Normal MRI reports excludes other organic causes of the same. So COVID-19 probably had some role in triggering hearing loss in this patient.

## DISCUSSION

In this case, there were only mild symptoms without any other evidence of end organ damage by cytokine storm during the illness. There was no specific significant abnormality in laboratory tests and imaging. Although

having poorly controlled diabetes, the patient had no prior history of hearing loss or any other complaint in the ears. Neither was he taking any ototoxic medication that can explain his hearing loss.

Studies have shown that around 4-5% of patients having poorly controlled diabetes of a mean duration of 3 years developed moderate to severe sensory neural hearing loss. But studies have also shown that removing age and other comorbidities as concomitant risk factors, diabetes cannot be attributed alone to hearing loss.<sup>4-6</sup> Some case reports have been published where SNHL was attributed to the use of HCQ. But the onset of SNHL was after months to years of use of HCQ.<sup>7</sup> Here in this case, the patient was given HCQ for only 5 days in standard dosage.

SNHL is an urgent otorhinolaryngology disorder that needs quick attention. Most of the case reports or systematic reviews show the presence of SNHL during active COVID-19 illness. This is a challenging scenario for the otorhinolaryngologists as they do not have specific guideline for treatment of this aspect of COVID-19. It is equally challenging to manage this entity in the post-hospitalisation COVID-19 phase as in this case.

Mustafa MWM conducted a study to compare the amplitude of transient evoked otoacoustic emissions (TEOAEs) and pure-tone audiometry thresholds between asymptomatic COVID-19 cases and normal non-infected participants. The high frequency pure-tone thresholds as well as the TEOAE amplitudes were significantly worse in the infected group. This could be due to deleterious effects of COVID-19 on cochlear hair cell functions despite being asymptomatic.<sup>8</sup>

Karimi-Galougahi et al observed acute onset hearing loss in young patients of COVID-19 without any prior history of illness of ear with no history of use of ototoxic drugs. Pure tone audiometry of these patients suggested unilateral SNHL. Similar findings were not noted during SARS and Middle East Respiratory Syndrome (MERS) outbreaks. This points towards neurotropism of SARS-CoV-2 considering other case reports of meningitis, encephalitis, Guillain-Barre syndrome, anosmia and ageusia.<sup>9</sup>

Most of the case reports, case series and letter to editors also suggest development of SNHL in the patients with either active COVID-19 infection or in early convalescence.<sup>10-13</sup> Frazier et al conducted post mortem bilateral cortical mastoidectomy. The mastoid specimens later came positive for SARS-CoV-2 by RTPCR implying the presence of the virus in the middle ear and mastoid.<sup>14</sup>

Munro et al conducted a follow up study on post-hospitalisation COVID-19 patients at around 8 weeks after discharge. Out of 138 patients, sixteen patients (13.2%) self-reported to be having change in hearing

and/or tinnitus. Median age of the patients was 64 years (IQR: 44-82 years). Four patients admitted to be having a pre-existing hearing loss but presented with a further deterioration.

This patient is one of the earliest cases of post-COVID-19 SNHL from India. The clinical and audiological findings match with the cases reported from elsewhere. However, most of the reported were reported during the active infection instead of being reported 3 months later as in this case. Exact cause of this is not known. Further studies are needed to find out the exact cause of delayed damage of cochlear cells or the afferent pathway.

## CONCLUSION

Patients presenting with sudden onset SNHL should be worked up for COVID-19 in the present pandemic scenario. Post-hospitalisation COVID-19 patients can also present with hearing loss as a part of post sequelae which will need further evaluation so that the patient does not develop a permanent damage to hearing.

*Funding: No funding sources*

*Conflict of interest: None declared*

*Ethical approval: Not required*

## REFERENCES

1. Rhman AS, Wahid AA. COVID-19 and sudden sensorineural hearing loss, a case report. Otolaryngol Case Reports [Internet]. 2020 Sep 1 [cited 2020 Sep 28]; 16:100198. Available at: <https://www.ncbi.nlm.nih.gov/pmc/articles/PMC7342036>.
2. Coronavirus resource centre, John Hopkins University of Medicine. Available at: <https://coronavirus.jhu.edu/map.html>; Accessed on 28 September 2020.
3. Elibol E. Otolaryngological symptoms in COVID-19. Eur Arch Oto-Rhino-Laryngology [Internet]. 2020;(0123456789):1-4. Available at: <https://doi.org/10.1007/s00405-020-06319-7>.
4. Chavadaki JA, Malli MNA. Prevalence of sensorineural hearing loss in type 2 diabetes mellitus. Int J Otorhinolaryngol Head Neck Surg. 2019;5(5):1227.
5. Kakarlapudi V, Sawyer R, Staecker H. The Effect of Diabetes on Sensorineural Hearing Loss. Otolaryngol Neurotol. 2003;24(3):382-6.
6. Samelli A, Santos I, Moreira R, Rabelo C, Rolim L, Bensenor I, et al. Diabetes mellitus and sensorineural hearing loss: is there an association? Baseline of the Brazilian Longitudinal Study of Adult Health (ELSA-Brasil). Clinics. 2017;72(1):5-10.
7. Prayuenyong P, Kasbekar AV, Baguley DM. Clinical Implications of Chloroquine and Hydroxychloroquine Ototoxicity for COVID-19 Treatment: A Mini-Review. Front Public Heal. 2020;8.
8. Mustafa MWM. Am J Otolaryngol, 2020. Available at: <https://doi.org/10.1016/j.amjoto.2020.102483>.
9. Karimi-Galougahi M, Naeini AS, Raad N, Mikaniki N, Ghorbani J. Vertigo and hearing loss during the COVID-19 pandemic - is there an association? La vertigine ed l'ipoacusia durante la pandemia COVID-19 - esiste un nesso? Acta Otorhinolaryngol Ital. 2020;1-3.
10. Almufarrij I, Uus K, Munro KJ. Does coronavirus affect the audio-vestibular system? A rapid systematic review. Int J Audiol [Internet]. 2020;59(7):487-91. Available at: <https://doi.org/10.1080/14992027.2020.1776406>.
11. Degen C, Lenarz T, Willenborg K. Acute Profound Sensorineural Hearing Loss After COVID-19 Pneumonia. Mayo Clin Proc. 2020;95(8):1801-3.
12. Kilic O, Kalciglu MT, Cag Y, Tuysuz O, Pektas E, Caskurlu H, et al. Could sudden sensorineural hearing loss be the sole manifestation of COVID-19? An investigation into SARS-CoV-2 in the etiology of sudden sensorineural hearing loss. Int J Infect Dis. 2020;97:208-11.
13. Saniasiaya J. Hearing Loss in SARS-CoV-2: What Do We Know? Ear Nose Throat J. 2020;1-3.
14. Frazier KM, Hooper JE, Mostafa HH, Stewart CM. SARS-CoV-2 Virus Isolated from the Mastoid and Middle Ear: Implications for COVID-19 Precautions During Ear Surgery. JAMA Otolaryngol Head Neck Surg. Published online July 23, 2020. Available at: [doi:10.1001/jamaoto.2020.1](https://doi.org/10.1001/jamaoto.2020.1).

**Cite this article as:** Chakraborty S, Maharatna S, Reddy CS, Gupta G, Baitha U, Jorwal P, et al. Hearing loss in a post COVID-19 patient. Int J Otorhinolaryngol Head Neck Surg 2021;7:548-50.