

Case Report

Dilemma in diagnosing a post-auricular mass-angiolympoid hyperplasia with eosinophilia versus Kimura's disease, an infrequent encounter

Sandeep Shetty, Shilpa Chandrashekar, Nivetha Devi Ganesan, Debayan Dey*, Ramya Sathanur Bhaskarachar

Department of ENT and Head and Neck Surgery, JSS Medical College and Hospital, JSS Academy of Higher Education and Research (JSSAHER), Mahathma Gandhi Road, Mysuru, Karnataka, India

Received: 31 December 2020

Accepted: 04 February 2021

*Correspondence:

Dr. Debayan Dey,
E-mail: debayan98@gmail.com

Copyright: © the author(s), publisher and licensee Medip Academy. This is an open-access article distributed under the terms of the Creative Commons Attribution Non-Commercial License, which permits unrestricted non-commercial use, distribution, and reproduction in any medium, provided the original work is properly cited.

ABSTRACT

Angiolympoid hyperplasia with eosinophilia (ALHE) and Kimura's disease are uncommon chronic benign lesions of the skin mainly involving the head and neck regions where ALHE involves vascular and lymphocytic proliferation and Kimura's is of inflammatory type. Dermal involvement is more in ALHE but in Kimura's disease the lymph nodes and subcutaneous tissues are involved more. ALHE is a rare vascular tumor and Kimura's disease is a chronic inflammatory disease. Both not only have uncertainty in etiology and pathogenesis, but also there is therapeutic dilemma in management. In this article, we describe a case of ALHE which presented to our ENT outpatient department with swelling in the left postauricular region which appeared 1.5 years back and posed a riddle in coming to correct diagnosis. On examination, a single smooth spherical swelling in upper part of post-auricular region of size 3×3 cm with well-defined edges and normal skin. Blood investigations revealed elevated absolute eosinophil count. HRCT temporal bone showed a well-defined rounded hypo-dense lesion measuring 28×23 mm with no effect of adjacent bony erosion / calcifications/ cystic changes suggestive of benign etiology. FNAC showed scanty cellular and occasionally scattered fibroblasts, pinkish stromal collagen fragments with inflammatory cells in background of haemorrhage suggestive of soft tissue neoplasm.

Keywords: Angiolympoid hyperplasia with eosinophilia, ALHE, Kimura's disease, Post auricular swelling, AEC

INTRODUCTION

Angiolympoid hyperplasia with eosinophilia (ALHE) is a rare vascular tumor and Kimura's disease is a chronic inflammatory disease. Both not only have uncertainty in etiology and pathogenesis, but also there is therapeutic dilemma in management. Fewer than 1000 cases of ALHE and 300 cases of Kimura's disease has been reported so far.^{1,2} In the olden days, both were thought to be two different presentations of the same disease. Although they share overlapping features, with distinctive clinical, epidemiological and histopathological features which

were declared currently, both are considered as separate entities. In this article, we describe a typical clinical case of ALHE which posed a riddle in coming to correct diagnosis from its main differential diagnosis, Kimura's disease.

CASE REPORT

An otherwise normal 39 year old male person presented to our ENT Outpatient department with swelling in the left post-auricular region which appeared 1 and half year before and gradually progressed to its present size. He also

had pain over the swelling for past 2 months. There was no history of fever, sore throat, cough, ear discharge, weight loss or trauma. There is no relevant family history.

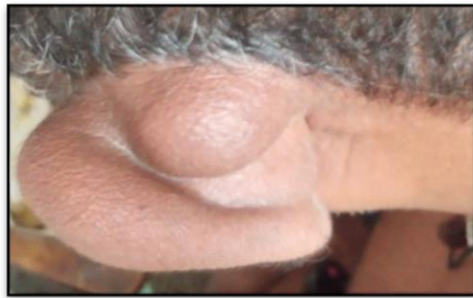

Figure 1: Presurgical photo- superior view of the post-auricular mass.

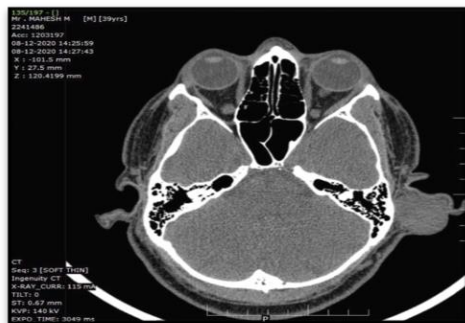


Figure 2: Axial view of HRCT temporal bone showing a well-defined rounded hypo-dense lesion.

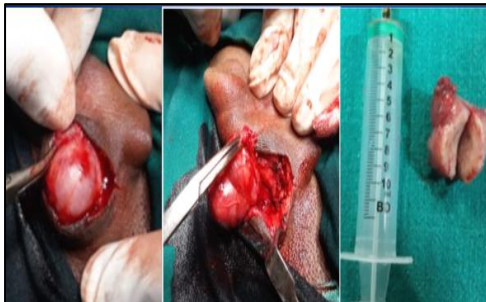

Figure 3: Intraoperative photograph showing well circumscribed smooth swelling with well-defined borders.

On examination, a single smooth spherical swelling of size 3×3 cm with well-defined edges and normal skin was noted in upper part of post-auricular region (Figure 1). On palpation, it was firm, mobile, non-tender, non-pulsatile, non-fluctuant with no trans-illumination.

Routine blood investigations were done which revealed rise in absolute eosinophil count (550 cells/cu.mm). Serology for HIV, HBsAg and HCV were non-reactive. We further subjected the patient for FNAC followed by HRCT. FNAC had scanty cellular and occasionally

scattered fibroblasts, pinkish stromal collagen fragments with inflammatory cells in background of hemorrhage suggestive of soft tissue neoplasm. HRCT temporal bone showed a well-defined rounded hypo-dense lesion measuring 28×23 cm with plain CT value of 37 HU noted in the post-auricular region of left pinna causing anterior displacement of pinna with no effect of adjacent bony erosion / calcifications/ cystic changes suggestive of benign etiology (Figure 2).

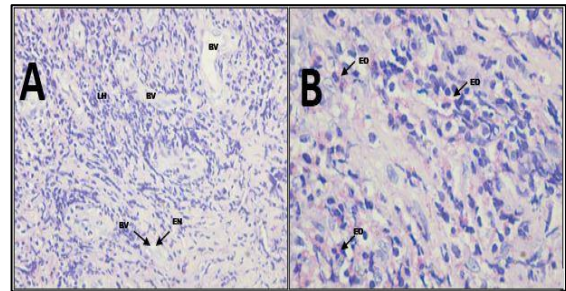


Figure 4: Excision biopsy HPE, A) Proliferation of blood vessels (BV) lined by plump endothelial cells (EN) with lymphoid diffuse lymphohistiocytic infiltrate (LH) with numerous eosinophils in a fibrous stroma (hematoxylin and eosin, ×4) B) Vascular proliferation with intense eosinophilic infiltrate (EO) (hematoxylin and eosin, ×10).

Suspecting it to be schwannoma or dermoid cyst, an excision biopsy was planned. On dissection, a firm smooth, bi-lobed well encapsulated swelling was noted and excised along with post-auricular lymphnode. (Figure 3)

Histopathology showed florid proliferation of blood vessels lined by plump endothelial cells having vesicular nucleus. The blood vessels were surrounded by fibrous tissue with dense infiltration by lymphocytes and eosinophils with scattered lymphoid aggregates (Figure 4a, 4b). These features are suggestive of angiolymphoid hyperplasia with eosinophilia.

In consideration of eosinophilia, a special investigation of serum IgE levels was sent to rule out Kimura's disease which was found to be within normal limits. Currently, the patient is doing well with no recurrence observed during his 6 months follow up.

DISCUSSION

Both ALHE and Kimura's are uncommon chronic benign lesions of the skin mainly involving the head and neck regions. ALHE involves vascular and lymphocytic proliferation whereas Kimura's is of inflammatory type disorder. Dermal involvement is more in ALHE but in Kimura's disease the lymphnodes and subcutaneous tissues are more commonly involved.

In 1969, Wells and Whimster, first derived the term, Angiolymphoid hyperplasia with eosinophilia who described it as distinguished neoplasm.³ Later, In 1982, Weiss and Enzinger evidently distinguished the lesion from malignant vascular tumour, epithelioid hemangioendothelioma, and put forth the term epithelioid hemangioma (EH).⁴ In 1937, Kimura's disease was first described and later popularized in 1947 by Kimura and his associates.⁵

ALHE commonly seen in young and middle aged men and women of Asian origin followed by Caucasians.^{6,7} It typically involves the peri-auricular region, face and scalp, rarely trunk, extremities, hands, penis, oral mucosa, colon are affected.⁸ On the other hand, Kimuras is more prevalent in young Asian lineage, mostly in their third decade of life.^{9,10} Kimura's disease occurs mostly in infra-auricular and retro-auricular region and rarely, orbit, eyelid, palate, pharynx were also involved.^{9,11,12} There is no sex predominance in ALHE where as in Kimura's disease, male predominance is seen.^{8,13}

The etiopathogenesis of both diseases are currently unknown. Several theories have been proposed for ALH, including a reactive process, neoplastic process and a infective mechanism with possible association with HIV.¹⁴ The association of monoclonal T-cell process is under debate.¹⁵ Peripheral T-cell lymphoma case has also been reported in a case of ALHE. Associated T-cell receptor (TCR gene) rearrangement and monoclonality has been detected.¹⁴ While in Kimura's disease, it has been put forward that a common trigger factor such as viral, parasitic infection or toxin could cause alteration of T-cell immunoregulation or induce an IgE mediated hypersensitivity resulting in release of eosinophilatrophic cytokines. The role of cytokines, such as interleukin (IL) 4, IL-5, IL-13 has been documented, which may precipitate high IgE levels and marked eosinophilia in this disease.⁹

Clinically, ALHE presents as solitary or multiple red or brown papules or nodules, measuring upto 3 cms, producing symptoms such as pruritis, bleeding and pain. Regional lymphadenopathy is rarely reported. Prolonged duration of lesion tend to produce more symptoms. Systemic manifestations are uncommon.¹⁶ On the flip side, Kimura's disease is predominantly unilateral and presents as subcutaneous nodules with occasional pruritis, eczema and rashes. It is associated with regional lymphadenopathy and may or may not involve salivary glands.¹⁷ It is characterized by triad of painless subcutaneous mass, blood and tissue eosinophilia and elevated serum IgE levels. Almost 60% of persons have renal involvement, usually manifesting as membranous glomerulonephritis and nephritic syndrome.^{12,18} Our case presented as solitary smooth spherical mass measuring 2.8x2.3 cm with pain over the swelling and elevated eosinophilia which cause dilemma in reaching the diagnosis.

The lesions can also be investigated additionally with USG, CT scan and MRI. But radiological features are not pathognomonic. The diagnosis is made only by histopathological examination of excision biopsy specimen.

Histopathology of ALHE demonstrates abnormal vascular proliferation of varying sizes and types is present, and the vessels are lined by plump histiocytoid or epithelioid endothelial cells. There are perivascular and interstitial inflammatory infiltrates with numerous eosinophils (5-15% of the infiltrate), lymphocytes with occasional lymphoid follicle formation.¹⁹ In Kimura's disease, there is florid lymphoid follicles with germinal center formation, eosinophilic infiltrates, micro-abscesses and folliculolysis. In contrast to Kimura's disease, the histiocytoid or epithelioid cells are characteristic feature of the ALHA.¹⁴

Both diseases follow a benign clinical course with no metastases reported so far. But there is high chance of recurrence. Spontaneous remission has also been reported. There is no consensus in the treatment modality of both diseases. Various methods of management have been tried with variable success rate such as intralesional and topical corticosteroids, pulse-dye laser, radiotherapy, cryotherapy, systemic and topical antibiotics, oral isotretinoin, oral pentoxifylline. The treatment of choice in both cases is surgical excision of the lesion. But there is high chance of local recurrence with recurrence rate of 40% in ALHE and 33-50% in Kimura's disease.^{20,21}

CONCLUSION

Though the diagnosis is difficult, it is important to distinguish the lesion from malignant neoplasms like epithelioid hemangioendothelioma, kaposi sarcoma. It helps us avoiding unnecessary radical surgery being done. As the disease is of rare phenomenon and of inconclusive etiopathogenesis, there is therapeutic inconsensus in management. Hence, more studies have to be done and a standardized treatment protocol has to be established.

Funding: No funding sources

Conflict of interest: None declared

Ethical approval: Not required

REFERENCES

1. Bahloul E, Amouri M, Charfi S, Boudawara O, Mnif H, Boudawara T et al. Angiolymphoid hyperplasia with eosinophilia: report of nine cases. *Int J Dermatol.* 2017;56(12):1373-8.
2. Abhay H, Swapna S, Darshan T, Vishal J, Gautam P. Kimura's disease: A rare cause of local lymphadenopathy. *Int J Sci Study.* 2014;2:122-5.
3. Wells GC, Whimster IW. Subcutaneous angiolymphoid hyperplasia with eosinophilia. *Bri J Dermatol.* 1969;81(1):1-5.
4. Weiss SW, Enzinger FM. Epithelioid hemangioendothelioma a vascular tumor often

- mistaken for a carcinoma. *Cancer.* 1982;50(5):970-81.
5. Kimura T, Yoshimura S, Ishikawa E. On the unusual granulation combined with hyperplastic changes of lymphatic tissue. *Trans Soc Patho Jpn.* 1948;37:179-80.
 6. Chitrapu P, Patel M, Readinger A, Menter A. Angiolymphoid hyperplasia with eosinophilia. *Proc (Bayl Univ Med Cent).* 2014;27:336-7.
 7. Esteves P, Barbalho M, Lima T. Angiolymphoid hyperplasia with eosinophilia: A case report. *Case Rep Dermatol.* 2015;7:113-16.
 8. Adler BL, Krausz AE, Minuti A. Epidemiology and treatment of angiolymphoid hyperplasia with eosinophilia (ALHE): a systematic review. *J Am Acad Dermatol.* 2016;74:506-12.
 9. Chen YM, Chen CH, Chen HH, Chen YH, Chen DY, Lan JL. Clinical manifestations, therapeutic response and disease outcome of Kimura's disease in Taiwan. *Formos J Rheumatol.* 2009;23:33-9.
 10. Calleja LAJM, Iturriaga TM, Romero MP, de María Martínez G, Martín-Moro JG, del Castillo JL. Kimura disease: Report of a case in a Caucasian male and revision of the literature. *Rev Esp Cir Oral Maxilofac.* 2006;28:353-8.
 11. Chen H, Thompson LD, Aguilera NS, Abbondanzo SL. Kimura disease: A clinicopathologic study of 21 cases. *Am J Surg Pathol.* 2004;28:505-13.
 12. Priyokumar OS, Niteshore MS, Ratan K. Bilateral Kimuras disease with sinusitis and parotid gland involvement: A case report and a brief review of literature. *IOSR J Dent Med Sci.* 2014;13:22-5.
 13. Hui PK, Chan JK, Ng CS, Kung IT, Gwi E. Lymphadenopathy of Kimura's disease. *Am J Surg Pathol.* 1989;13:177-86.
 14. Guo R, Gavino AC. Angiolymphoid hyperplasia with eosinophilia. *Arch Pathol Lab Med.* 2015;139(5):683-6.
 15. Kempf W, Haeffner AC, Zepter K, Sander CA, Flaig MJ, Mueller B et al. Angiolymphoid hyperplasia with eosinophilia: evidence for a T-cell lymphoproliferative origin. *Hum Pathol.* 2002;33(10):1023-9.
 16. Bastos JT, Rocha CR, Freitas BM, Cassia FD, Avelleira JC. Angiolymphoid hyperplasia with eosinophilia versus Kimura's disease: a case report and a clinical and histopathological comparison. *Anais Brasileiros de Dermatol.* 2017;92(3):392-4.
 17. Patel CS, Dave RV. Kimuras disease: A case report. *Int J Dent Clin.* 2011;3:115-6.
 18. Calleja LAJM, Iturriaga TM, Romero MP, de María Martínez G, Martín-Moro JG, del Castillo JL. Kimura disease: Report of a case in a Caucasian male and revision of the literature. *Rev Esp Cir Oral Maxilofac.* 2006;28:353-8.
 19. Alshaiji JM. Angiolymphoid Hyperplasia with Eosinophilia. *Harper's Textbook of Pediatrics Dermatology.* 2019;1350-5.
 20. Youssef A, Hasan AR, Youssef Y, Al-Soufi L, Elshimali Y, Alshehabi Z. Angiolymphoid hyperplasia with eosinophilia: a case report. *Journal of medical case reports.* 2018;12(1):1-6.
 21. Ghimire A, Singh I, Bhattarai M. Angiolymphoid hyperplasia with eosinophilia: a rare entity for otolaryngologist. *Nep Med Col J.* 2006;8(3):208-10.

Cite this article as: Shetty S, Chandrashekar S, Ganesan ND, Dey D, Bhaskarachar RS. Dilemma in diagnosing a post-auricular mass-angiolymphoid hyperplasia with eosinophilia versus Kimura's disease, an infrequent encounter. *Int J Otorhinolaryngol Head Neck Surg* 2021;7:544-7.