

Original Research Article

Clinical study of thyroid swellings

Ashwini S. Rathod*, Girija A. Ghate, Ammu Korah, Lakshmi Krishnan, Ruchir R. Dashora

Department of Otorhinolaryngology, Dr. D. Y. Patil Medical College, Hospital and Research Centre, DPU, Pune, Maharashtra, India

Received: 28 December 2020

Revised: 22 January 2021

Accepted: 30 January 2021

***Correspondence:**

Dr. Ashwini S. Rathod,

E-mail: drashwinirathod96@gmail.com

Copyright: © the author(s), publisher and licensee Medip Academy. This is an open-access article distributed under the terms of the Creative Commons Attribution Non-Commercial License, which permits unrestricted non-commercial use, distribution, and reproduction in any medium, provided the original work is properly cited.

ABSTRACT

Background: Thyroid swellings are very frequently encountered in ENT practice, ranging from a simple cyst to a malignant tumour. Disorder of structure of thyroid gland, due to various etiological factors, will give rise to swelling in the neck region. Clinical signs and symptoms are inadequate to diagnose thyroid disorders as similar presentations are seen in various thyroid disorders. So, this study of thyroid swellings was done to know different clinical presentations, age and sex distribution, correlation between thyroid swellings and thyroid function tests, analyse various thyroid swellings and etiological factors based on pathological reports.

Methods: A prospective study with 50 patients of thyroid swellings was conducted over 2 years, after taking consent from each patient. Patients were clinically examined by inspection, palpation, percussion, auscultation and underwent thyroid function tests. Ultrasonography (USG) and fine needle aspiration cytology (FNAC) was done in all patients.

Results: Total 50 patients of thyroid swellings were studied. Mean age of the patients was 38.92 years with female preponderance (74%). Thyroid swellings were commonly present bilaterally (54%). 82% cases showed euthyroid state. USG revealed that most of the patients had colloid nodule (46%), followed by MNG (26%). Majority of lesions were benign on both USG and FNAC reports. MNG (44%) was reported frequently in the provisional diagnosis, followed by colloid nodule (24%).

Conclusions: In all cases of thyroid swellings, detailed clinical history, thorough clinical examination is required. Thyroid function test, USG and FNAC reports help to reach the definitive diagnosis. Histopathological report confirms and gives final diagnosis.

Keywords: Thyroid, MNG, Euthyroid

INTRODUCTION

Thyroid gland is the largest endocrine organ in the body. Thyroid disorders can be broadly classified as disorders of functions, disorders of structure and miscellaneous. Disorder of structure, due to various etiological factors, will give rise to thyroid swelling in neck region. Thyroid swellings can vary right from simple diffuse physiological goitre to a high-grade malignancy. Clinical signs and symptoms are inadequate to diagnose the thyroid disorder as some similar presentation are seen in various thyroid swellings. For example, thyroglossal cyst and isthmus cyst

can both present with a midline neck swelling with cystic consistency, which has to be differentiated based on clinical examination. Thyroglossal cyst moves on protrusion of tongue while the isthmus cyst does not. Other example is benign and malignant disorders of thyroid gland with thyroid swelling, which may present with diffuse swelling which is difficult to differentiate clinically. So, the investigations are aimed at determining the biochemical thyroid dysfunction, like hypothyroidism/thyrotoxicosis and nature of structural lesion in thyroid.¹

Management of thyroid swelling begins with taking a complete history of the patient, thorough clinical

examination, lab investigations (mainly thyroid function tests - free T3, free T4 and ultra-thyroid stimulating hormone i.e. TSH levels in serum) to know the functional state of thyroid gland; FNAC and radiological investigations (USG). USG gives complete evaluation of thyroid with respect to its size, echotexture, multicentricity, its shape, presence of nodules and their details, vascularity, the involvement of lobes and isthmus, presence of calcification, infiltration in surrounding structure, localise lesion for FNAC, assess cervical lymphadenopathy, etc. FNAC gives cytological details to reach the final diagnosis, required for management planning.

A clinical study of thyroid swellings was undertaken, in order to find out the prevalence of various types of thyroid disorder in patients presenting with thyroid swellings in the region, their age and sex distribution and preponderance. After the clinical examination and required investigations, to reach to a particular diagnosis for the further management of the disorder.

METHODS

This prospective study on clinical evaluation of thyroid swellings was carried out in ENT OPD of Dr. D. Y. Patil Medical College, Hospital and Research Centre, DPU, Pimpri, Pune, Maharashtra for the duration of 2 years, from September 2018 to August 2020. Total 50 patients of thyroid swellings were studied.

The ethical approval was received for this study.

Patients above the age of 6 years with thyroid swellings were included in the study. Patients with thyroid swelling below 6 years and all patients without thyroid swellings were excluded from the study. Informed and written consent was taken from all the patients participating in the study.

All the patients presenting with thyroid swellings were subjected to thorough history to know the onset, duration and progression of thyroid swellings. Then they were clinically examined by inspection, palpation (by Pizzillo's, Lahey's and Crile's method – whichever was applicable), percussion and auscultation. The patients underwent thyroid function tests in the form of free T3, free T4 and ultra TSH in serum.

All the patients were subjected to ultrasonography of neck which gave the information about the size, extent, vascularity, echotexture, calcification, consistency (solid/cystic), laterality of thyroid swelling, infiltration in surrounding structure and cervical lymphadenopathy (if present).

They underwent fine needle aspiration cytological examination, which gave the histopathological diagnosis of the thyroid swellings. No statistical tool (software) was used for the analysis of data.

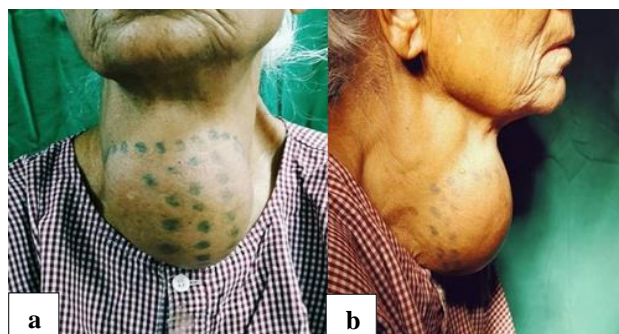

Figure 1: (a) Anterior view and (b) right lateral view of a 70 year old female, case of multinodular goitre.

RESULTS

In this study, 50 patients of thyroid swellings were studied. The age of the youngest patient participated in the study was 12 years and that of the eldest patient was 80 years with mean age of 38.92 years and median age of 39 years. Thyroid swelling was found most commonly in female patients (74%) with female: male ratio of 2.8:1 and total of 37 females and 13 males participated in the study. The thyroid swelling was mostly found in the age group of 21-40 years (54%) out of which majority (46%) were females and only 8% were males.

Laterality

The majority of thyroid swellings were bilateral (54%). The unilateral thyroid swellings found were mostly present in the right thyroid lobe (22%). Thyroid swelling in left thyroid lobe and midline were present only in 12% of cases each.

Thyroid state

Most of the patients showed euthyroid state - 82%, followed by hyperthyroid - 8%, subclinical hypothyroid - 6%, hypothyroid and subclinical hyperthyroid - 2% each. USG findings revealed that most of the patients had colloid nodule - 46%, followed by MNG (26%), thyroid malignancy (10%), thyroiditis (10%), thyroid cyst (4%) and thyroglossal cyst (4%) (Table 1).

Table 1: Ultrasonographic findings.

Ultrasonographic findings	No. of patients	M-ale	Fem -ale	Percent-age (%)
Colloid nodule	23	7	16	46
MNG	13	1	12	26
Thyroid malignancy	5	3	2	10
Thyroiditis	5	0	5	10
Thyroid cyst	2	1	1	4
Thyroglossal cyst	2	1	1	4
Total	50	13	37	100

On USG, 90% cases showed benign lesions while only 10% showed malignant lesion while on FNAC, 92% cases were confirmed as that of benign lesions and only 8% of malignant lesion. FNAC report revealed colloid goitre in majority of cases (48%), followed by colloid nodule in 14% cases, thyroiditis in 10% cases, colloid cyst in 8% cases, thyroglossal cyst and papillary thyroid carcinoma in 4% cases each and 2% cases each of Hashimoto's thyroiditis, lymphocytic thyroiditis, Hürthle cell carcinoma, hyperplastic thyroid nodule, benign follicular thyroid nodule and follicular lesion/atypia of undetermined significance (Table 2).

Table 2: FNAC findings.

FNAC findings	No. of patients	Female	Male	Percentage (%)
Colloid goitre	24	19	5	48
Colloid nodule	7	7	0	14
Colloid cyst	4	3	1	8
Thyroglossal cyst	2	1	1	4
Thyroiditis	5	5	0	10
Hashimoto's thyroiditis	1	1	0	2
Lymphocytic thyroiditis	1	1	0	2
Papillary thyroid carcinoma	2	1	1	4
Hürthle cell carcinoma	1	0	1	2
Hyperplastic thyroid nodule	1	0	1	2
Benign follicular thyroid nodule	1	0	1	2
Follicular lesion/atypia of undetermined significance	1	0	1	2
Total	50	38	12	100

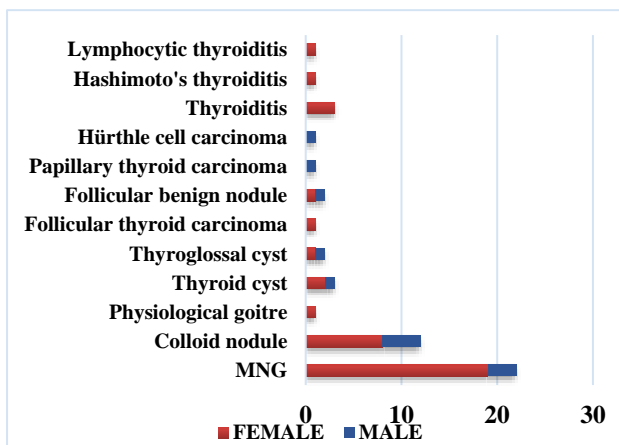


Figure 2: Distribution of patients based on provisional diagnosis.

DISCUSSION

The modality of treatment of thyroid swellings can differ based on the diagnosis, age of patient, underlying comorbid conditions. USG and FNAC form back bone of investigative tests in determining nature of thyroid lesions. In this context, the current study was conducted to evaluate the thyroid swellings seen in patients presenting to a tertiary care hospital in 50 patients.

In our study, we found that the mean age of the patients presenting with thyroid swelling was 38.92 years with median age of 39 years. The age of the patients was ranging from 12-80 years in our study. In our study, it was also found that thyroid swellings are common in age group of 21-40 years i.e. in 3rd and 4th decade. Similar results were observed in studies conducted by Hariprasad et al, Kusum et al and Bose et al.²⁻⁴

Thyroid swelling is more common in females than in males. In our study, thyroid swelling was most commonly seen in females with female: male ratio of 2.8:1 which was similar to that found by Bose et al and Islam et al.^{4,5} The ratio of female preponderance in our study differed from that found in study of Hariprasad et al and Kusum et al with the female:male ratio of 10:1 and 5:1 respectively.^{2,3}

The patients with thyroid swellings commonly present with symptoms like swelling in anterior part of neck, pain in the swelling, sometimes with dysphagia or hoarseness of voice, heat or cold intolerance, palpitations. In our study, after examining all the patients clinically, it was found that the most common presenting symptom was anterior neck swelling, while pain in swelling and weight loss was found only in 8% and 4% of cases respectively. Similar findings were seen in study by Tonape et al.⁶

The thyroid function test gives information about the functional state of thyroid gland. In our study, after the thyroid function test of all patients, it was found that maximum (82%) patients were in euthyroid state, followed by 8% in hyperthyroid state, which was similar to that found in the studies of Tonape et al and Bose et al.^{4,6}

Thyroid swelling can be present in midline or unilaterally or bilaterally depending on the involvement of thyroid lobes and isthmus. In our study, on clinical examination and correlating it with ultrasonographic findings, it was found that majority of the patients presented with bilateral swelling (54%), followed by unilateral swelling (34%) and few (12%) had swelling in the midline, which differed from other studies with swelling frequent unilaterally. In our study in unilateral swellings, the swelling was frequently found in right lobe of thyroid (22%) and only 12% swelling were present in left thyroid lobe, which was similar to the findings of Vyas et al and Deepthi et al.^{7,8}

On USG, in our study, colloid nodule was the commonest thyroid swelling followed by MNG, which differed from that found by Santosh et al.⁹

The ultrasonographic findings help in distinguishing whether the thyroid swelling is benign or malignant, by providing information about the nodularity, vascularity, calcification and extension of thyroid swelling. A high suspicion is needed to identify malignant swellings.

In studies conducted by Venkates et al, Tonape et al, Sudershan et al and Rout et al found that colloid goitre (81%, 40%, 66% and 55% respectively) as the most common benign thyroid lesion.^{6,10-12} Similarly, in our study, we found that 48% of cases had colloid goitre was the commonest benign thyroid lesion and papillary carcinoma (4%) was the frequent malignant thyroid lesion.

Findings in our study are similar to those in many other studies in aspects like age-sex distribution, functional state of thyroid and commonest benign and malignant thyroid lesion. The findings of our study, which differed from other studies were laterality of thyroid swellings, occurrence of thyroid cyst, thyroiditis, thyroglossal cyst and physiological goitre in thyroid swellings.

CONCLUSION

In our study, we observed that the commonest presentation of patients with thyroid swellings is anterior neck swelling. Thyroid swellings can have a wide range of age at presentation appearing in children as well as geriatric patients, but the commonest age group is between 21-40 years. Thyroid swellings are commonly seen in female patients, with female: male ratio of 2.8:1. The thyroid function tests help in knowing the thyroid status of the patient. Majority of the patients with thyroid swellings belonged to the euthyroid state in this study. The ultrasonographic findings provide information about the nodularity, vascularity, calcification, extension and infiltration into surrounding structures. Ultrasonographic findings cannot give definitive diagnosis and the histopathological features, so FNAC is required to confirm histopathological diagnosis. The commonest benign thyroid swellings are multinodular goitres. The second commonest benign thyroid swellings are colloid nodules. Malignancies are not very common and are seen only in about 8% of cases, commonest of malignancy being papillary thyroid carcinoma.

Funding: No funding sources

Conflict of interest: None declared

Ethical approval: The study was approved by the Institutional Ethics Committee

REFERENCES

1. Waraporn I, Ashok RS, Neil S. History of thyroid and parathyroid surgery. Scott Brown. Vol 1, 8th edn. 2019;52:597-602.

2. Hariprasad S, Teerthnath S. Clinicopathological study of thyroid swellings – a two years prospective study. *Indian J Basic Appl Med Res.* 2017;6(3):152-60.
3. Borsaikia K, Patar M. Clinicopathological study of thyroid swellings with some emphasis on geographical and community distribution: A hospital-based analysis. *Bengal J Otorhinol Head Neck Surg.* 2016;24(2):74-9.
4. Bose A, Sharma N, Hemvani N, Chitnis DS. A hospital-based prevalence study on thyroid disorders in Malwa region of Central India. *Int J Curr Microbiol App Sci.* 2015;4(6):604-11.
5. Islam MS, Siddiquee BH, Akhtar N, Salam KS, Aktaruzzaman M. Comparative study of FNAC and histopathology in the diagnosis of thyroid swelling. *Bangladesh J Otorhinolaryngol.* 2010;16(1):35-43.
6. Tonape T, Athavale VS, Shetty I. Clinicopathological correlation of thyroid swellings. *J Med Sc Clin Res.* 2016;4(12):14382-5.
7. Vyas CS, Vijayvargiya SC, Porwal S, Gupta R. A study of thyroid swelling with clinicopathological parameters. *Int J Biol Med Res.* 2013;4(2):3250-2.
8. Deepthi M, Sukthankar PS, Narsimloo K. Solitary nodule thyroid: diagnosis and management. *Int J Otorhinolaryngol Head Neck Surg.* 2017;3(3):611.
9. Santosh UP, Kumar KBS, Trupthi MC, Boobalan S. A comprehensive approach to Thyroid Swellings: Clinical, Sonological, Cytological and Histopathological Correlation. *Otorhinolaryngol Clin.* 2014;6(1):5-8.
10. Venkates TK, Vighnesh VV. A clinicopathological study of thyroid swellings. *CIB Tech J Surg.* 2015;4(3):1-8.
11. Sudershan K, Ashwani K. Study of clinical pattern of thyroid swellings and their management. *J Dent Med Sc.* 2018;17(2):27-35.
12. Rout K, Ray CS, Behera SK, Biswal R. A Comparative study of FNAC and Histopathology of Thyroid Swellings. *Indian J Otolaryngol Head Neck Surg.* 2011;63(4):370-2.

Cite this article as: Rathod AS, Ghate GA, Korah A, Krishnan L, Dashora RR. Clinical study of thyroid swellings. *Int J Otorhinolaryngol Head Neck Surg* 2021;7:448-51.