

Case Report

Maxillary odontogenic myxoma presenting mainly on nasal manifestation: a unique CT appearance of ‘floating’ tooth

Najlaa Raihana Juhari*, Chong Aun Wee

Department of Otorhinolaryngology Head and Neck Surgery, University Malaya Medical Centre, Bangsar Kuala Lumpur, Malaysia

Received: 13 December 2020

Accepted: 19 December 2020

*Correspondence:

Dr. Najlaa R. Juhari,

E-mail: najlaaraihana@gmail.com

Copyright: © the author(s), publisher and licensee Medip Academy. This is an open-access article distributed under the terms of the Creative Commons Attribution Non-Commercial License, which permits unrestricted non-commercial use, distribution, and reproduction in any medium, provided the original work is properly cited.

ABSTRACT

An odontogenic myxoma is a benign odontogenic tumor with locally aggressive behavior. It is relatively rare in the oral cavity. The diagnosis poses a challenge because its features overlap with those of other benign and malignant neoplasms. We present an unusual case of odontogenic myxoma with involvement of the maxilla extending to the maxillary sinus in a 17-year-old lady. A unique computed tomography (CT) appearance revealed a well circumscribed lytic lesion arising from the left maxilla causing expansion and thinning of the maxillary cortex. There is a discernible tooth with adjacent amorphous calcification in a round formation noted within the lesion. Biopsy revealed an odontogenic myxoma. The patient however did not undergo surgical excision as was not consented at the time of this write ups. This paper highlights the unique radiographic appearance of the pathology that has not been reported so far as well as to discuss its clinical significance.

Keywords: Maxillary odontogenic myxoma, Odontogenic myxoma, Myxoma, Maxillary cyst, Jaw cyst

INTRODUCTION

Odontogenic myxomas (OM) are categorized by the modified WHO classification under odontogenic ectomesenchyme with or without included odontogenic epithelium arising from the dental papilla, follicle or the periodontal ligament. Odontogenic myxoma is an uncommon benign tumor that mainly affects the mandible, with a peak incidence in the second to fourth decades of life and predilection for the female sex.¹ Thoma and Goldman first described myxomas of the jaws involving maxilla.² These tumors are found exclusively within the jaw bones and can generate at any stage of the individual's life but most common in 2nd and 3rd decade.^{3,4} Cortical expansion and perforation are common findings; maxillary myxomas often extend into the sinus.⁵ It presents as an asymptomatic cortical expansion with a soap bubble or honeycomb appearance, without sensory nerve changes. Odontogenic myxomas bear a close

microscopic resemblance to the mesenchymal portion of the developing tooth.⁶ Even though it is benign, odontogenic myxoma can be locally invasive and cause significant morbidity. Complete surgical excision is the treatment of choice, but it can be challenging because of the tumour's indistinct margins. Recurrence are expected with curettage and enucleation.

CASE REPORT

A 17-year-old female patient presented to our clinic with 6 month history of left nasal blockage and intranasal “fullness”. Further history revealed she also had complaints of left cheek fullness together with bony hard, painless left nasal swelling from past 4 months.

On clinical examination there was a smooth and hard swelling of left nasolabial fold. Anterior rhinoscopy revealed medialization of medial wall of maxilla with

complete obstruction between inferior turbinate and septum – resulting in inability to pass the rigid endoscope for further evaluation. The left upper premolar was noted to be absent. Other oral examination is unremarkable.

A computed tomography (CT) scan was performed showing a well circumscribed lytic lesion arising from the left maxilla causing expansion and thinning of the maxillary cortex measuring 4.0×3.8×3.8 cm. There is a discernible tooth (unerupted premolar) with adjacent amorphous calcification in a round formation noted within the lesion. The lesion is causing obliteration of the left nasal cavity and right lateral deviation of the nasal septum (Figure 1-4).

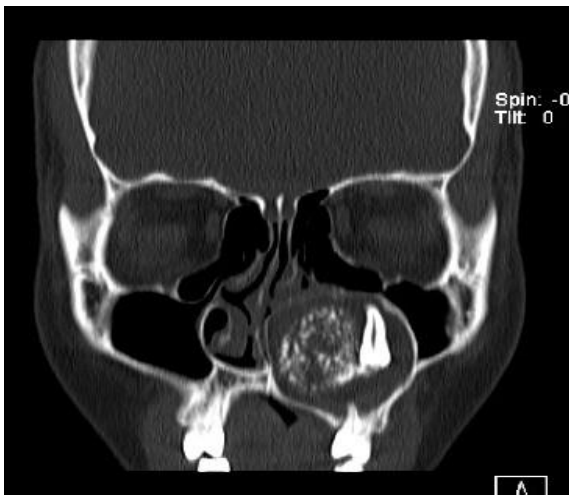


Figure 1: Coronal CT scan of the patient showing well circumscribed lytic lesion arising from the left maxilla with a discernible “floating” tooth with adjacent amorphous calcification in a round formation noted within the lesion.

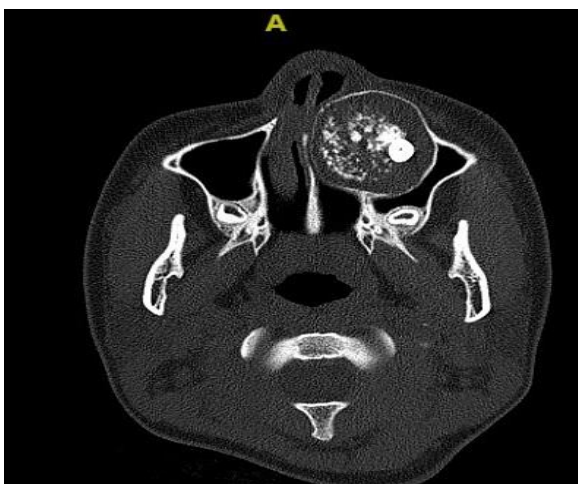


Figure 2: Axial CT scan of the patient showing the lesion is causing obliteration of the left nasal cavity and right lateral deviation of the nasal septum.

Results of a radiological examination revealed a unilocular radiolucency with cortical expansion and displacement of the left upper premolar and the first molar. Based on these features and probability of odontogenic origin, it was provisionally diagnosed as cemento-ossifying fibroma with a differential diagnosis of myxoma and unilocular ameloblastoma.

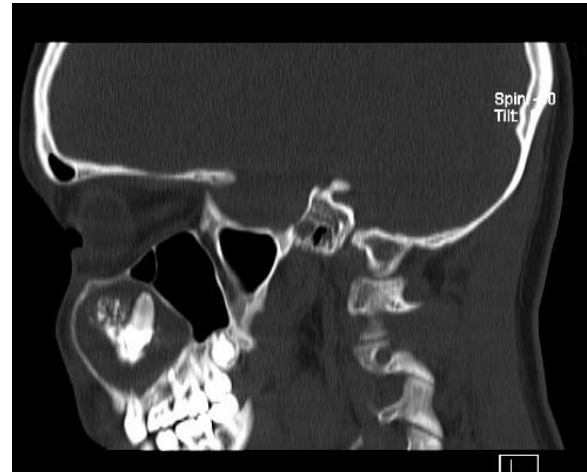


Figure 3: Sagittal CT scan of the patient showing well circumscribed lytic lesion arising from the left maxilla causing expansion and thinning of the maxillary cortex.

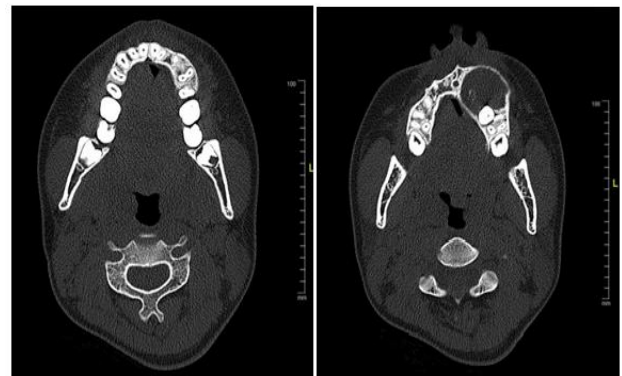

Figure 4: Axial CT scan of the patient showing showing unerupted tooth (left premolar) and the origin of the cyst from maxillary bone.

Incisional biopsy was done under general anaesthesia via sublabial incision with part of the maxilla and cystic lining tissue was sent for the histopathological examination.

Histopathology examination of the biopsied sample revealed the tumour is composed of occasional quiescent odontogenic epithelial islands within a background of prominent loosely arranged myxoid stroma. The fibrous connective tissue is moderately cellular with scattered spindle and stellate-shaped fibroblasts. Several blood vessels and areas containing dystrophic calcifications are also present. Based on these features it was consistent

with odontogenic myxoma. The patient was consulted for a surgical excision however was not consented at the time of this case write up.

DISCUSSION

Myxomas of head and neck are divided into two forms: i) deriving from facial bone which has also been subdivided into osteogenic myxoma and odontogenic myxoma; ii) deriving from soft tissue which originate from perioral soft tissues, parotid glands, ears and larynx.⁷ Myxomas of the jaw bones have been traditionally considered to have an odontogenic origin due to the close relation to teeth. The evidence for its odontogenic origin arises from its location in the tooth bearing areas of the jaws, its occasional association with missing or unerupted teeth and the presence of odontogenic epithelium.

According to the literature, OM represents between 3% and 10% of all odontogenic tumours.⁸ In a retrospective radiographic analysis of 21 cases, the mandible was more involved than the maxilla.⁹ They have predilection for the molar and premolar region of the maxilla.¹⁰

Odontogenic maxillary myxomas were first mentioned in the literature by Thoma et al on the basis of site of occurrence, age at occurrence, association with missing teeth, and histopathological examination, which showed structural resemblance with dental mesenchyme and the sporadic presence of islands of odontogenic epithelium.²

Clinical presentation of OM ranges from patient being asymptomatic to symptoms such as pain, paraesthesia or facial asymmetries when they take on larger sizes. Their growth is usually slow; however, they are locally aggressive. Based on various case reports, patients with maxillary odontogenic myxoma commonly present with facial fullness with or without buccal and palatal involvement. However, the case presented here is an unusual variant in view of the main presentation of intranasal fullness with left nasal blockage. Based on aforementioned clinical findings, differential diagnosis includes ameloblastoma, odontogenic keratocyst, radicular cyst, dentigerous cyst lateral periodontal cyst, intraosseous hemangioma, simple bone cyst, giant cell granuloma, aneurismal bone cyst and metastasis of malignant tumours which shows the slow growth pattern.¹¹

Although the radiographic aspects of odontogenic myxomas are markedly variable, they are always radiolucent. Most of the cases reported the appearance of soap bubbles, tennis racket and honey combs. Therefore, it should always be considered in the differential diagnosis of radiolucent and mixed radiolucent-radiopaque lesions of both jaws in all age groups.

Literature studies have described OM as unilocular or multilocular radiolucency with well-defined borders and fine bony trabeculae within its structure. Dental

displacement and root resorption on conventional radiographs and panoramic radiographs are relatively common findings.^{11,18} Herein, we report an appearance of 'floating' teeth within the typical CT appearance of OM which is unique radiological variant. There was no tooth resorption and none of the tooth were found to be loose on clinical examination. In a study done by Kaffe et al, he concludes that only 5% of the tumours were associated with unerupted tooth.¹²

In its histological aspect, the odontogenic myxoma has abundant mucosal intercellular substance, made up of eosinophilic lax connective tissue, immersed in this stroma there are spindle-like cells and star-shaped cells with elongated cytoplasm, with or without small masses of inactive odontogenic epithelium.¹³

Microscopically the intercellular matrix is mucoid, and the cytoplasm is slightly basophilic, finely granular and with a well-defined nucleus, mitotic figures are few. Cells may show pleomorphism. Bone may be rarely present with islands of inactive odontogenic epithelium.¹⁴ Recent ultrastructural studies have showed that myxoma is a tumour of fibroblasts, modified in such a way to form a matrix composed of glycosaminoglycans and do not form collagen fibrils-designated as 'myxoblasts'.¹¹

Histological differential diagnosis must be made with rhabdomyosarcoma, myxoid liposarcoma, neurogenic sarcoma, neurofibroma, lipoma, fibroma, chondromyxoid and nodular fasciitis.¹⁵

The current treatment for OM includes resection with bony margins of at least 1.0 to 1.5 cm and leaving behind one uninvolved anatomic boundary. Maxillectomy and sometimes resection of the orbital floor is required for OM in the upper jaw.¹⁶ Enucleation, curettage and peripheral ostectomy are inadequate because of its gelatinous and nonencapsulated nature which makes the lesion to recur. Period of the greatest recurrence rate is seen in the first 2 years.¹⁷

CONCLUSION

This a rare case of maxillary odontogenic myxoma with maxillary sinus involvement. The radiological aspect of OM are variables. Nonetheless this is so far the only reported CT appearance of odontogenic myxoma with discernible tooth presented within the lesion. Due to varied radiographic presentation it makes difficult to diagnose lesion based on radiographic features alone. Because of its variable clinical and radiographic features, hence histopathological examination is mandatory to confirm its diagnosis.

Funding: No funding sources

Conflict of interest: None declared

Ethical approval: Not required

REFERENCES

1. Shivashankara C, Nidoni M, Patil S, Shashikala KT. Odontogenic myxoma: a review with report of an uncommon case with recurrence in the mandible of a teenage male. *Saudi Dent J.* 2017;29(3):93-101.
2. Thoma KH, Goldman HM. Central myxoma of the jaw. *Am J Orthodont Ora Surg.* 1947;33(7):B532-40.
3. Philipsen HP, Reichart PA. Classification of odontogenic tumours. A historical review. *J Oral Pathol Medic.* 2006;35(9):525-9.
4. PRESIDENT IP, ELECT P. Edited by: Dr. K. Nandakumar, Hon. Editor• Published By: Dr. OV Sanal, Hon Secretary• For IDA, Kerala State Branch• Production: Suman Graphics, sumangf x@gmail. com.
5. Brannon RB. Central odontogenic fibroma, myxoma (odontogenic myxoma, fibromyxoma), and central odontogenic granular cell tumor. *Oral Maxillofac Surg Clin.* 2004;16(3):359-74.
6. Martínez-Mata G, Mosqueda-Taylor A, Carlos-Bregni R, de Almeida OP, Contreras-Vidaurre E, Vargas PA, et al. Odontogenic myxoma: clinicopathological, immunohistochemical and ultrastructural findings of a multicentric series. *Oral Oncol.* 2008;44(6):601-7.
7. Fenton S, Sloomweg PJ, Dunnebie EA, Mourits MP. Odontogenic myxoma in a 17-month-old child: a case report. *J Oral Maxillofac Surg.* 2003;61(6):734-6.
8. Parihae AS, Malhotra R, Nagpal N, Joshi A, Rajguru SA, Bhatia G. Adenomatoid odontogenic tumor: An unusual tumor. *J Res Adv Dent.* 2015;4:207-10.
9. Peltola J, Magnusson B, Happonen RP, Borrmann H. Odontogenic myxoma—a radiographic study of 21 tumours. *Br J Oral Maxillofac Surg.* 1994;32(5):298-302.
10. Kaymakci M, Yazici S. Odontogenic myxoma of the maxilla. *Clinics Pract.* 2011;1(4).
11. Vasudevan V, Das UM, Manjunath V, Bavle RM, Sudhakar M, Kumar N, et al. Odontogenic myxoma of the maxilla: A report of unusual pediatric case. *Int J Clin Pediat Dentist.* 2011;4(3):264.
12. Kaffe I, Naor H, Buchner A. Clinical and radiological features of odontogenic myxoma of the jaws. *Dentomaxillofac Radiol.* 1997;26(5):299-303.
13. Manjunath S, Gupta A, Swetha P, Moon Nj, Singh S, Singh A. Report of a rare case of an odontogenic myxoma of the maxilla and review of literature. *Ann Med Health Sci Res.* 2014;4(Suppl 1):S45-8.
14. Oygur T, Dolanmaz D, Tokman B, Bayraktar S. Odontogenic myxoma containing osteocementum-like spheroid bodies: Report of a case with an unusual histopathological feature. *J Oral Pathol Med.* 200;30(8):504-6
15. Costa AD, Rocha AC, Cavalcanti MD, Silva JS. Mixoma odontogênicos: relato de caso com considerações clínicas, radiográficas e histopatológicas. *Rev Pos-grad.* 1996;3(3):246-9.
16. Ferri J, Caprioli F, Peuvrel G, Langlois JM. Use of the fibula free flap in maxillary reconstruction: a report of 3 cases. *J oral Maxillofac Surg.* 2002;60(5):567-74.
17. Batsakis JG. Myxomas of soft tissues and the facial skeleton. *Ann Otol Rhinol Laryngol.* 1987;96(5):618-9.
18. Friedrich RE, Scheuer HA, Fuhrmann A, Zustin J, Assaf AT. Radiographic findings of odontogenic myxomas on conventional radiographs. *Anticanc Res.* 2012;32(5):2173-7.

Cite this article as: Juhari NR, Wee CA. Maxillary odontogenic myxoma presenting mainly on nasal manifestation: a unique CT appearance of ‘floating’ tooth. *Int J Otorhinolaryngol Head Neck Surg* 2021;7:163-6.