

## Case Report

# Trans-cervical approach to parapharyngeal space occupying lesion: case report

Manish Munjal\*, Porshia Rishi, Harjinder Sidhu, Shubam Munjal, Shivam Talwar,  
Salony Sharma, Hardeep Kaur, Karan Dhillon

Department of ENT, Dayanand Medical College and Hospital, Ludhiana, Punjab, India

**Received:** 07 December 2020

**Accepted:** 08 January 2021

### \*Correspondence:

Dr. Manish Munjal,

E-mail: [manishmunjal30@gmail.com](mailto:manishmunjal30@gmail.com)

**Copyright:** © the author(s), publisher and licensee Medip Academy. This is an open-access article distributed under the terms of the Creative Commons Attribution Non-Commercial License, which permits unrestricted non-commercial use, distribution, and reproduction in any medium, provided the original work is properly cited.

## ABSTRACT

A parapharyngeal mass was resected utilising the trans-cervical parapharyngeal approach with minimal morbidity. Intricacies of procedure are elaborated upon.

**Keywords:** Parapharyngeal space, Transcervical approach, Pharynx, FNAC, Computed tomography

## INTRODUCTION

Parapharyngeal space occupying lesions are embedded in the space between pharynx i.e. naso-oro-laryngo-pharynx internally and the parotid and mandibular ramus externally.<sup>1</sup> The access to this hidden area is difficult and diagnosis of any lesion revolves around myriad of differential diagnoses keeping in view the normal neurovascular structures at this site.

A bulge of the uvulo-palatal region or tonsillar prolapse is often the only clinical presentation. Fine needle aspiration cytology (FNAC) traverses through soft tissues and the usual report is 'inconclusive or a blood aspirate with suggestion of a repeat FNAC or a biopsy, from the existing oropharyngeal bulge.

We hereby present an intriguing case of a parapharyngeal space occupying lesion.

## CASE REPORT

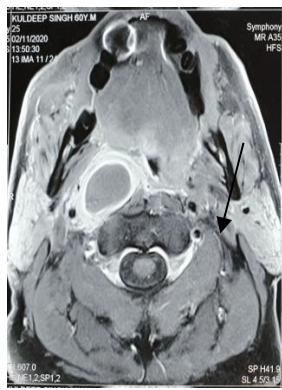A 60 year individual presented with a bulge on the right soft palate in proximity to the supra tonsillar fossa for the last 6 months. The swelling was smooth with a healthy mucosal lining. There was slight post nasal trickle with

muffling of voice. There was no trismus nor any nasal regurgitation nor dysphagia. There was an associated swelling on the basi sphenoid region from which the biopsy was reported as epithelial soft tissue lining only. External FNAC was deferred in view of the mass lying medial to the carotid sheath.

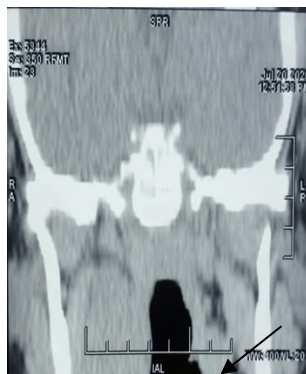
Magnetic resonance imaging T2, was suggestive of hyperintense 2.6×2.6×4 cm well defined lesion displacing the carotid vessels laterally and superiorly abutting the medial pterygoid with medial effacement of fat plane of the parapharyngeal space. The pharynx lateral wall showed a bulge with luminal narrowing on MR arteriography, the branches of external carotid artery were seen reaching close to the lesion with a small feeder from the ascending pharyngeal artery.

Incision from middle of hyoid bone to anterior border of sternocleidomastoid muscle just above the level of hyoid bone (Figure 4).

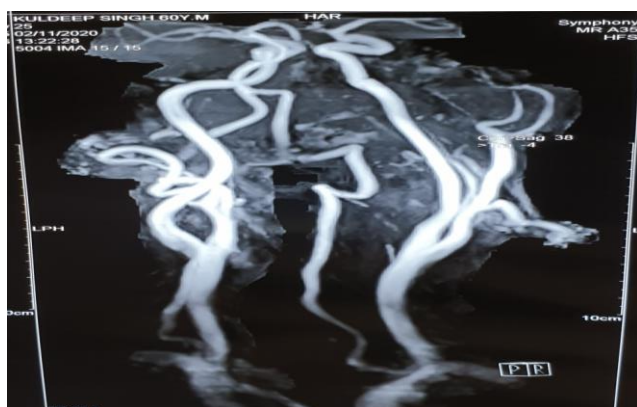
Common facial vein ligated. Submandibular gland was mobilised and removed after ligating anterior vessels and facial artery and its submental division at its superior and inferior poles and transfixing the submandibular duct.



**Figure 1: Axial magnetic resonance imaging section showing hyperintense 2.6x2.6x4 cm well defined lesion (black arrow) displacing the carotid vessels laterally superiorly abutting medial pterygoid and schematic representation showing parapharyngeal space.**



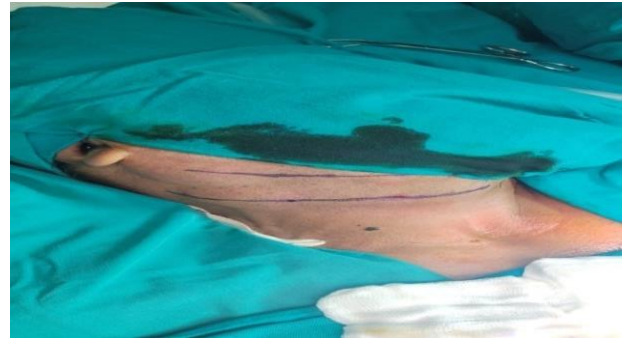
**Figure 2: Coronal section showing parapharyngeal mass below the medial pterygoid muscle and schematic representation showing parapharyngeal space.**



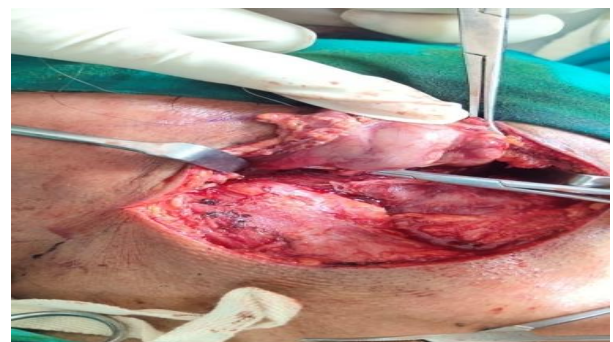**Figure 3: MR arteriography, the branches of external carotid artery (white arrow) were seen reaching close to the lesion.**

The integrity of rami mandibularis, lingual nerve, and hypoglossal nerves was maintained. The sternocleidomastoid muscle was retracted to expose the ‘surgeon’s friend’ the posterior belly of digastric muscle,

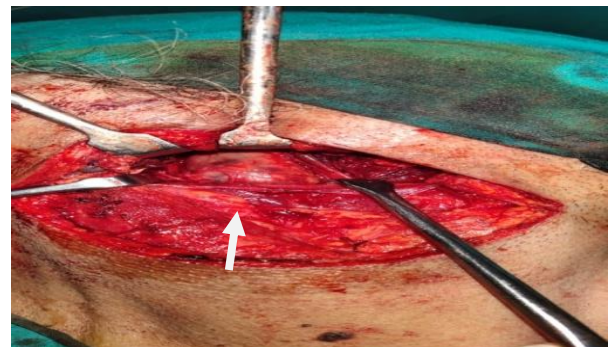
which was transected at common tendinous level to visualise the carotid sheath.



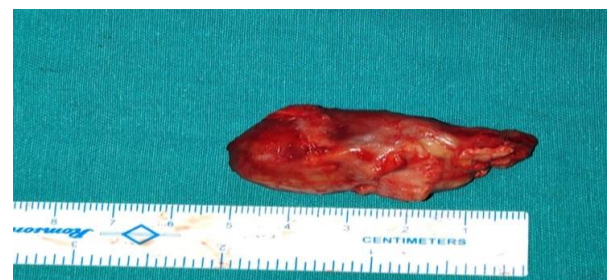**Figure 4: Incision from middle of hyoid bone to anterior border of sternocleidomastoid muscle.**



**Figure 5: Mobilised submandibular gland to increase access to parapharyngeal space.**



**Figure 6: Parapharyngeal lobular mass (white arrow) freed at superior and inferior pole.**



**Figure 7: Removed 5x3 cm parapharyngeal mass in toto.**



The parotid tail was lifted off to enter the parapharyngeal corridor, remaining medial to the carotid sheath. The styloid process was palpated with its overlying styloglossus and stylohyoid muscle and ligament.

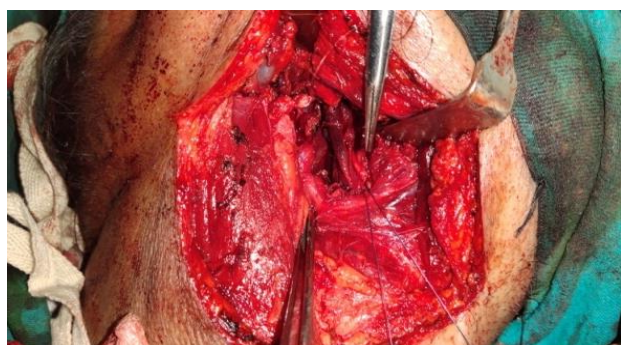
With blunt dissection a plane was created medially between the inverted lobular shaped mass and the middle constrictor, superiorly the medial pterygoid and laterally the carotid sheath.

Two feeding vessels, one at the superior and one at the inferior aspect of the mass were ligated and transfixed. The mass was mobilized and delivered inferiorly.

Middle constrictor was injured inadvertently at one site and was repaired with inverting sutures. The integrity of the carotid sheath and its contents was checked with betadine instillation and oropharyngeal gasing maneuver thereby confirming a water tight repair of the constrictor.

An indwelling negative pressure drain was inserted in wound and sutured externally.

A feeding naso-gastric tube was inserted for nutrition, to be removed after 7-15 days. Tongue protrusion, eyelid elevation, vocal cord mobility, absence of nasal regurgitation, nasal twang confirmed integrity of IX, X, XI nerves. Post-operative phase was uneventful. Ryle tube was removed on 15th day.



**Figure 8: Water tight seal of repaired middle constrictor muscle (black arrow).**

Histopathology reported it as an acute necrotizing inflammatory mass.

## DISCUSSION

The nomenclature for the parapharyngeal space includes, lateral pharyngeal space, pterygo-pharyngeal space, pterygo-maxillary space and the pharyngo-maxillary space. It extends from base of the skull to the hyoid bone forming an inverted pyramid bounded medially by pharynx, anteriorly pterygomandibular raphe, posterolaterally carotid sheath, posteromedially retropharyngeal space, laterally above the level of mandible it is bounded by ramus of mandible, deep lobe of parotid and medial pterygoid muscle. Below the level of

mandible; it is bounded by posterior belly of digastric muscle laterally.

Facial condensation joining the styloid process to the tensor veli palatini is called aponeurosis of Zuckercandle and Testut divided the parapharyngeal space into prestyloid and poststyloid compartments.<sup>1</sup>

The differential diagnosis of a parapharyngeal space lesion include infectious or inflammatory lesions, neoplastic, neurogenic, salivary gland pathology, glomus tumour, lymphoma, lipoma, secondary malignancy from adjacent spaces and vascular anomalies.<sup>2</sup>

Parapharyngeal tumors account for only 0.8% of all head and neck tumors, which often present the problem of pre-operative diagnosis. Upto 80% of parapharyngeal tumors are benign.<sup>3</sup>

Pleomorphic adenoma is the most common tumor of prestyloid compartment whereas poststyloid tumors are mostly neurogenic like the schwannoma, paraganglioma, neurofibroma, hemangiomas etc. Chordomas, lipomas, lymphomas, chemodectomas, rhabdomyomas, chondrosarcomas, desmoid tumours, ameloblastomas, amyloid tumours, ectomesenchymomas, fibrosarcomas and plasmacytomas have also been reported.<sup>4</sup>

Symptoms depend on the space affected. Those found in the pre-styloid compartment manifest as otitis media, hoarseness, nasal obstruction, dysphagia or dyspnea while those in the post-styloid compartment as compression of cranial nerves IX, X, XI, XII and the sympathetic chain causing, nasal regurgitation dysphagia, dysphonia dysarthria and the Horner's syndrome.<sup>5</sup>

These pathologies pose a diagnostic dilemma due to their location and plethora of presentations with morphological overlap leading to diagnosis being confirmed only by histopathological examination and not on fine needle aspiration cytology.<sup>6</sup>

Displacement patterns of fat within the parapharyngeal space will aid in the localization of lesions within adjacent deep spaces of the head and neck. A lesion arising in the: masticator space displaces the parapharyngeal fat posteromedially, parotid space displaces the parapharyngeal fat anteromedially, pharyngeal mucosal space displaces the parapharyngeal fat posterolaterally, retropharyngeal space, danger space, and prevertebral space displace the parapharyngeal fat anterolaterally, carotid (poststyloid parapharyngeal) space displaces the parapharyngeal fat anteriorly. In contrast, a lesion primarily involving the parapharyngeal space will displace the carotid space posteriorly and the pharynx medially.<sup>7,8</sup>

MRI clearly delineates the dimensions of the parapharyngeal space lesions with advantage of distinguishing tumor from muscular structures.<sup>9</sup>

Surgical management of parapharyngeal space tumors is very challenging owing to anatomic complexity of the space and vicinity of the tumor with major neurovascular structures. Critical points to assess before surgery are the intraoperative exposure for an optimal dissection and preservation of neurovascular structures as well as complete resection of the neoplasm, with minimal postoperative morbidity or adverse results, both functional and esthetic.

There are seven different approaches described for these tumors namely transcervical, transcervical- transparotid, transoral-transcervical approach, extended approach, transcervical-mandibulotomy approach.<sup>10,11</sup>

In our patient a transcervical approach was used to access and remove the parapharyngeal mass which turned out to be a benign pathology.

Displacement or resection of the submandibular gland depends on the size of the parapharyngeal tumour to be resected.

The transcervical approach is indicated for lesions with 3–6 cm in diameter, specifically regarding the vertical dimension, with clear separation from the skull base ( $\geq 0.5$  cm). The transcervical approach is unique in that it permits extending the operating field based on the surgical findings.<sup>12</sup>

Complications after surgical management are unavoidable. Expected complications are due to sacrifice of cranial nerves. There may be unexpected neurological complications in spite of preservation of nerves like first bite syndrome, trismus, facial nerve weakness, orocutaneous fistula, seroma.<sup>13</sup>

## CONCLUSION

The highlight of this presentation is whatever may be the parapharyngeal lesion (tumour or a cyst) has to be removed and the approach to be undertaken should have minimal morbidity and maximal access.

*Funding: No funding sources*

*Conflict of interest: None declared*

*Ethical approval: Not required*

## REFERENCES

1. Som PM, Curtin HD. Parapharyngeal and masticator space lesions. *Head Neck Imag.* 2003;2:1955-87.
2. Som PM, Biller HF, Lawson WT, Sacher M, Lanzieri CF. Parapharyngeal space masses: an updated

- protocol based upon 104 cases. *Radiology.* 1984;153(1):149-56.
3. Weber A, Tannapfel A, Kösling S, Bootz F. Parapharyngeale Raumforderungen Differenzialdiagnostik anhand von Fallbeispielen. *HNO.* 2002;50(3):223-9.
4. Chu W, Strawitz JG. Parapharyngeal growth of parotid tumors: Report of two cases. *Arch Surg.* 1977;112(6):709-11.
5. Dimitrijevic MV, Jesic SD, Mikic AA, Arsovic NA, Tomanovic NR. Parapharyngeal space tumors: 61 case reviews. *Int J Oral Maxillofac Surg.* 2010;39(10):983-9.
6. Mondal A, Raychoudhuri BK. Peroral fine needle aspiration cytology of parapharyngeal lesions. *Acta Cytologica.* 1993;37(5):694-8.
7. Arya S, Rane P, D'Cruz A, Hathiram BT, Khattar VS. Infratemporal fossa, masticator space and parapharyngeal space: can the radiologist and surgeon speak the same language. *Int J Otorhinolaryngol Clin.* 2012;4(3):125-35.
8. Aygun N, Zinreich SJ. Overview of diagnostic imaging of the head and neck" in Flint PW, editor. *Cummings Otolaryngology-head & neck surgery.* 2019.
9. Shin JH, Lee HK, Kim SY, Choi CG, Suh DC. Imaging of parapharyngeal space lesions: focus on the prestyloid compartment. *Am J Roentgenol.* 2001;177(6):1465-70.
10. Bozza F, Vigili MG, Ruscito P, Marzetti A, Marzetti F. Surgical management of parapharyngeal space tumours: results of 10-year follow-up. *Acta Otorhinolaryngologica Italica.* 2009;29(1):10.
11. Tincani AJ, Martins AS, Altemani A, Scanavini Jr RC, Barreto G, Lage HD, Valério JB, Molina G. Parapharyngeal space tumors: considerations in 26 cases. *Sao Paulo Med J.* 1999;117(1):34-7.
12. Luna-Ortiz K, Villa-Zepeda O, Carrillo JF, Molina-Frias E, Gómez-Pedraza A. Parapharyngeal space tumor: Submandibular approach without mandibulotomy. *J Maxillofacial Oral Surg.* 2018;17(4):616-24.
13. Cohen SM, Burkey BB, Netterville JL. Surgical management of parapharyngeal space masses. *Head Neck: J Sci Specialties Head and Neck.* 2005;27(8):669-75.

**Cite this article as:** Munjal M, Rishi P, Sidhu H, Munjal S, Talwar S, Sharma S, et al. Trans-cervical approach to parapharyngeal space occupying lesion: case report . *Int J Otorhinolaryngol Head Neck Surg* 2021;7:540-3.