

Case Report

Cavernous hemangioma of the nasal cavity: mimicking as the inverted papilloma

Sushil Natthuji Panbude, Amrita Harish Guha*, Abhishek Mahajan,
Nilesh Pandurang Sable, Supreeta Arya

Department of Radiodiagnosis, Tata memorial Hospital, Mumbai, Maharashtra, India

Received: 24 December 2016

Accepted: 03 February 2017

*Correspondence:

Dr. Amrita Harish Guha,

E-mail: amritaguha85@gmail.com

Copyright: © the author(s), publisher and licensee Medip Academy. This is an open-access article distributed under the terms of the Creative Commons Attribution Non-Commercial License, which permits unrestricted non-commercial use, distribution, and reproduction in any medium, provided the original work is properly cited.

ABSTRACT

Cavernous hemangioma of the nasal cavity is extremely rare with only case reports in the literature highlighting the imaging findings on CT and MRI. Haemangioma are benign vascular tumours, which originate in the skin, mucosa and deep structures such as bones, muscles and glands. Exact etiopathogenesis of the haemangioma is not known, although they are divided into two types depending on the dominant vessel size at microscopy, capillary and cavernous. When these neoplasms arise in the nasal cavity, they are predominantly capillary and are found to arise from the nasal septum and are more common in the children. On the other hand, Cavernous haemangiomas are more likely to be found on the lateral wall of the nasal cavity and are more commonly seen in elderly. Also, inverted papilloma also more commonly arise from the lateral wall of the nasal cavity, from the middle turbinate and also has the same demographics as the cavernous hemangioma. So, the distinction between the two should be carefully made based on the imaging findings so as to give the appropriate treatment to the patient. We have presented a rare case cavernous haemangioma arising from the mucosa of the middle nasal meatus, in a 37-year-old male which is mimicking as an inverted papilloma based on the imaging features; however on histopathology proved to be cavernous hemangioma and also on the multimodal imaging that helps in early diagnosis and advocating appropriate and timely treatment.

Keywords: Cavernous hemangioma, CT and MRI, Histopathology, Inverted papilloma

INTRODUCTION

Haemangiomas are benign vascular tumours, which originate in the skin, mucosa and deep structures such as bones, muscles and glands. Exact etiopathogenesis of haemangiomas formation is not known, although they are divided into two types depending on the dominant vessel size at microscopy into capillary and cavernous types. When these neoplasms arise in the nasal cavity, they are predominantly capillary and are found to arise from the nasal septum and are more common in the children. On the other hand, cavernous haemangiomas are more likely to be found on the lateral wall of the nasal cavity and are more commonly seen in elderly.¹ In the largest study of nasal haemangiomas by Osborn in 1959 which reviewed

51 patients with nasal haemangiomas over an 11-year period, only two were of the cavernous variety.² We have presented a rare case cavernous haemangiomas arising from the mucosa of the middle nasal meatus, in a 37-year-old male mimicking as an inverted papilloma.

CASE REPORT

A 37 year old male patient presented with intermittent swelling of the left side of face and epistaxis since 1.5 years. Anterior rhinoscopy revealed a large soft tissue mass almost completely filling in the left nasal cavity, with active mucoid discharge and minimal blood clots. A contrast enhanced MR scan was done which revealed a well-defined non bone erosive mass within and limited to

the left nasal cavity arising from the left middle meatus, displacing the nasal septum contra laterally. It was seen obstructing the left maxillary ostium, with resultant mucosal thickening and retained secretions in the left maxillary sinus.

It appeared iso to hypointense to muscles on T1W as in Figure 1a, heterogeneously hyperintense on T2WI as shown in Figure 2a and STIR Figure 1b and showed early heterogeneous post contrast enhancement Figure 1c and 2b. On coronal STIR and coronal T1+C images, it showed a convoluted cerebriform pattern Figure 1b and 1c. This characteristic imaging pattern led us the diagnosis of an inverted papilloma.

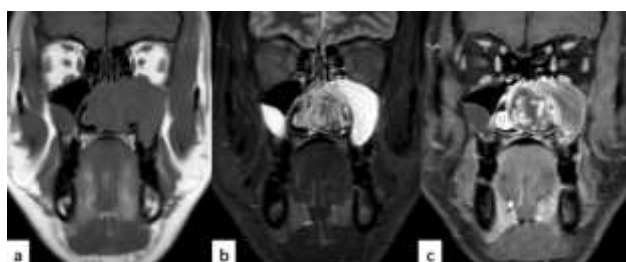

Figure 1: Cor T1WI (a) shows mass filling the left nasal cavity iso intense to the muscles, hyperintense on STIR (b) and shows heterogeneous post contrast enhancement (c) Convoluted cerebriform pattern is seen on STIR (b) and T1+C (c) images.

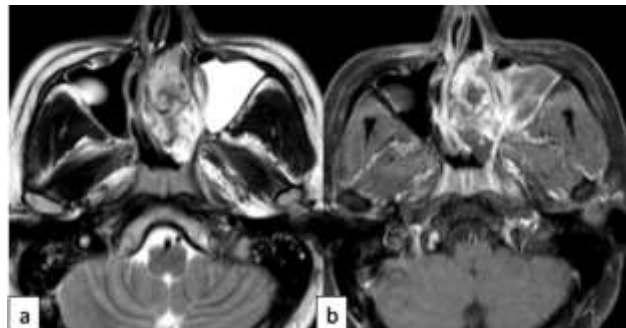


Figure 2: Ax T2WI (a) shows T2 hyperintense mass in the left nasal cavity with retained secretion in the left maxillary sinus. Ax T1+C (b) images shows heterogeneous enhancement of the mass.

Punch biopsy of the nasal mass was done which showed mainly fibrin blood clots along with tiny fragments showing dilated, ectatic channels lined by endothelial cells Figure 3a and positive for vascular marker CD31 Figure 3b. There was no inverted papilloma like morphologic features on histopathology. Hence, histopathology confirmed the lesion to be a cavernous haemangiomas. No evidence of any epithelial neoplasm or malignancy was seen in the biopsy. The patient underwent an endoscopic assisted modified medial maxillectomy with complete removal of tumor. Though there was minimal intraoperative bleeding, postoperative course in the hospital was uneventful.

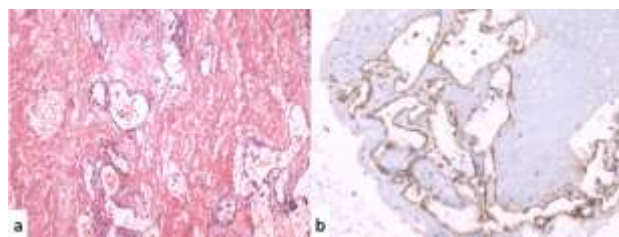


Figure 3: Histopathology images showing (a) ectatic vascular channels lined by endothelial cells and (b) positive for special stain with CD31.

DISCUSSION

Haemangiomas are benign vascular tumors composed of newly formed vessels with endothelial lining. Though they are the most common soft tissue tumor in head and neck, they are rare in the nasal cavity and the paranasal sinuses.³ Depending on the dominant vessel size at microscopy, they are of three types- capillary, cavernous and mixed.³ The most common type of haemangiomas in nasal cavity is the capillary type composed of capillary sized vessels, occurring more commonly in the nasal septum or vestibule and is more common in children, while cavernous haemangiomas more commonly arise from the lateral wall of the nasal cavity, appear at around fourth decade and contain large endothelium-lined vascular spaces.^{1,4} In nasal cavity and paranasal sinuses, they have been described arising from the inferior turbinate, vomer, lamina perpendicularis, os ethmoidalis and maxillary sinus.⁵⁻⁹ Thrombi within these vascular spaces can occasionally calcify and be identified at CT as phleboliths. Although they are benign, hemangiomas often infiltrate adjacent structures and recur after operation.¹⁰ Therefore, preoperative diagnosis and extent of the tumor on imaging is important. The presence of a bleeding mass in the nasal cavity can be due to various malignant and benign lesions and the definitive diagnosis is made by histological confirmation of the surgical specimen. Preoperative biopsy is essential to confirm the diagnosis, but it is not an easy task as severe bleeding may occur. Care has to be taken to avoid severe bleeding and arrangement should be made for emergency blood transfusion. Imaging and routine blood investigations should be performed prior to any attempt of biopsy.

The differential diagnosis of the nasal haemangiomas includes inverted papilloma, olfactory neuroblastoma, lymphoma, haemangiopericytoma, haemangioendothelioma, arteriovenous fistula, lymphangioma, glomangioma, melanoma, adenocarcinoma, squamous cell carcinoma and metastatic malignancies such as renal cell carcinoma. The presence of benign findings on imaging, with its typical enhancement pattern and history of recurrent epistaxis should lead a radiologist to suspect vascular origin.

Inverted papilloma of the nose is a benign epithelial tumor arising from the Schneiderian mucosa of the nasal cavity, a distinct form of the endodermally derived

mucosa of the upper respiratory tract.¹¹ Classical imaging finding of an inverted papilloma is described to be a convulated cerebriform pattern typically seen on T2WI and post contrast T1WI. It manifests on T2WI as alternating hypointense areas due to cellular epithelium and hyperintense areas due to less cellular edematous stroma on T2WI and on contrast enhanced T1WI less cellular edematous stroma is seen as enhancing striations.¹² Diagnosis is often difficult as convulated cerebriform pattern is also seen in other malignant sinonasal neoplasms.¹² However, a cavernous haemangioma presenting in a convulated cerebriform pattern has not been reported in literature as yet.

Imaging features for sinonasal cavernous hemangiomas have been described in literature on both CT and MR imaging, however, MRI is superior to computed tomography in sinonasal cavernous hemangiomas because of greater soft tissue resolution and less artifact. On computed tomography, cavernous haemangiomas appear as soft tissue density circumscribed mass, heterogeneously enhancing after injection of contrast. Non enhancing areas correspond to the areas of necrosis and hemorrhage. Contrast CT scanning usually reveals anatomical location and extension of the tumor. The underlying bone is usually normal but may be remodeled by adjacent long-standing pressure from the expanding mass.^{13,14} Less frequently, cavernous hemangiomas cause adjacent bone destruction, making them difficult to differentiate from other malignant tumors.¹⁵ The occurrence of phleboliths which appear as hyper dense areas on CT are considered to be more typical of cavernous haemangiomas.

Itoh et al first described the MR features of the cavernous haemangiomas.¹⁴ These lesions typically show the signal intensity of the non-clotted blood, having prolonged T1 and T2 relaxation time. They show low signal intensity T1-weighted images and very high signal intensity on T2-weighted images compatible with low flow vascular structure. Foci of hypointense signals may represent phleboliths and T1WI hyper intensity corresponds to the areas of hemorrhage or fat content. Characteristically these lesions do not contain large vessels and, therefore, they don't demonstrate the signal voids associated with hypervascularity which is typical of other vascular malformations.^{13,14}

If there is any suspicion regarding the nature of these vascular tumours, angiography should always be performed, not only because it can offer the possibility of correct diagnosis but also with the aid of trans-arterial embolization using particulate emboli, undue hemorrhage during surgical intervention can be avoided.^{16,17} Hemangiomas are supplied by small arteries which have slow blood flow, which is why these tumors may not be demonstrated by arterial angiography. Zhao et al performed cavity angiography by direct puncture of the hemangiomas and obtained successful results.¹⁸ Shimshak et al suggested the use of venography to demonstrate

these tumors.¹⁹ Angiography was not performed in our patient.

Various forms of treatment are available for haemangiomas with surgical resection of the tumor, with a cuff of surrounding uninvolved tissue and ligation or cauterization of the feeding vessels, being the most successful.¹ Other methods of treatment available are cryotherapy, corticosteroid treatment, sclerosing solutions and resection using YAG laser, which have been used with differing results. An alternative form of management is embolization of the haemangiomas, which is, however, only possible if appropriate angiographic facilities and expertise are available and in case of favorable anatomy.⁵ The surgical approach depends on the exact location of the tumor. Various surgical choices available are midfacial degloving, lateral rhinotomy, trans-palatal, trans-antral approach and the Le Fort I osteotomy procedure. The trans-nasal endoscopic approach has been proposed as the technique of choice in cases of haemangiomas of the nasal cavity and paranasal sinuses.^{1,20}

In our patient, endoscopic assisted modified medial maxillectomy was done with complete removal of tumor associated with mild intra-op bleeding. Thus, this was an unusual case of a male patient with left sinonasal cavernous hemangiomas which was mimicking an inverted papilloma on imaging. Hence, to conclude, knowledge of imaging features and local tumor extent on imaging is a must in advocating appropriate treatment.

Funding: No funding sources

Conflict of interest: None declared

Ethical approval: Not required

REFERENCES

1. Iwata N, Hattori K, Nakagawa T, Tsujimura T. Hemangioma of the nasal cavity: a clinicopathologic study. *Auris Nasus Larynx.* 2002;29(4):335-9.
2. Osborn DA. Haemangiomas of the nose. *J Laryngol Otol.* 1959;73(3):174-9.
3. Batsakis JG, Rice DH. The pathology of head and neck tumors: vasoformative tumors, part 9A. *Head Neck Surg.* 1981;3(3):231-9.
4. Enzinger F WS. No Title. 2nd edition. Soft tissue tumor. 1998.
5. Webb CJ, Porter G, Spencer MG, Sissons GR. Cavernous haemangioma of the nasal bones: an alternative management option. *J Laryngol Otol.* 2000;114(4):287-9.
6. Fahmy FF, Back G, Smith CE, Hosni A. Osseous haemangioma of inferior turbinate. *J Laryngol Otol.* 2001;115(5):417-8.
7. Nakahira M, Kishimoto S, Miura T, Saito H. Intraosseous hemangioma of the vomer: a case report. *Am J Rhinol.* 1997;11(6):473-7.
8. Graumüller S, Terpe H, Hingst V, Dommerich S, Pau HW. An intraosseous hemangioma in the

- perpendicular lamina of the ethmoid bone. *HNO.* 2003;51(2):142–5.
9. Engels T, Schörner W, Felix R, Witt H, Jahnke V. Cavernous hemangioma of the maxillary sinus. *HNO.* 1990;38(9):342–4.
 10. Hoehn JG, Farrow GM, Devine KD, Masson JK. Invasive hemangioma of the head and neck. *Am J Surg.* 1970;120(4):495–500.
 11. Pasquini E, Sciarretta V, Farneti G, Modugno GC, Ceroni AR. Inverted papilloma: report of 89 cases. *Am J Otolaryngol.*;25(3):178–85.
 12. Jeon TY, Kim H-J, Chung S-K, Dhong H-J, Kim HY, Yim YJ, et al. Sinonasal inverted papilloma: value of convoluted cerebriform pattern on MR imaging. *AJNR Am J Neuroradiol.* 2008;29(8):1556–60.
 13. Dillon WP, Som PM, Rosenau W. Hemangioma of the nasal vault: MR and CT features. *Radiology.* 1991;180(3):761–5.
 14. Itoh K, Nishimura K, Togashi K, Fujisawa I, Nakano Y, Itoh H, et al. MR imaging of cavernous hemangioma of the face and neck. *J Comput Assist Tomogr.* 1986;10(5):831–5.
 15. Liu JK, Burger PC, Harnsberger HR, Couldwell WT. Primary Intraosseous Skull Base Cavernous Hemangioma: Case Report. *Skull Base.* 2003;13(4):219–28.
 16. Kim HJ, Kim JH, Hwang EG. Bone erosion caused by sinonasal cavernous hemangioma: CT findings in two patients. *AJNR Am J Neuroradiol.* 1995;16(5):1176–8.
 17. Hayden RE, Luna M, Goepfert H. Hemangiomas of the sphenoid sinus. *Otolaryngol Head Neck Surg.* 1979;88(2):136–8.
 18. Zou ZJ, Wu YT, Sun GX, Zhu XP, Meng XZ, He ZQ. Clinical application of angiography of oral and maxillofacial hemangiomas. *Clinical analysis of seventy cases. Oral Surg Oral Med Oral Pathol.* 1983;55(5):437–47.
 19. Shimshak RR WD. *J Can Assoc Radiol.* 1976;(27):203–5.
 20. Jungheim M, Chilla R. The monthly interesting case -case no. 64. Cavernous hemangioma. *Laryngorhinootologie.* 2004;83(10):665–8.

Cite this article as: Panbude SN, Guha AH, Mahajan A, Sable NP, Arya S. Cavernous hemangioma of the nasal cavity: mimicking as the inverted papilloma. *Int J Otorhinolaryngol Head Neck Surg* 2017;3:423-6.