

Original Research Article

Level IIb involvement in oral cavity squamous cell carcinoma

Parth Patni, Deepak Dalmia*, Narsinha Davange, Karthika Bhagavan,
Amit Palwade, Rizul Goyal

Department of ENT, Dr. Baba Saheb Ambedkar Central Railway Hospital, Byculla, Mumbai, Maharashtra, India

Received: 07 December 2020

Revised: 04 January 2021

Accepted: 05 January 2021

***Correspondence:**

Dr. Deepak Dalmia,

E-mail: drdeepakdalmia@gmail.com

Copyright: © the author(s), publisher and licensee Medip Academy. This is an open-access article distributed under the terms of the Creative Commons Attribution Non-Commercial License, which permits unrestricted non-commercial use, distribution, and reproduction in any medium, provided the original work is properly cited.

ABSTRACT

Background: Cervical lymph node status is the most significant prognostic factor in the treatment of patients with OSCC. Adequate clearance of level IIb lymph nodes require traction and elevation of the spinal accessory nerve (SAN) and can lead to consequent shoulder problems. Therefore, avoiding the dissection of level IIb has been increasingly proposed to overcome this complication. The aim of this study was to determine the prevalence of level IIb metastasis in patients with oral squamous cell carcinomas (OSCCs).

Methods: A total of 106 newly diagnosed oral cavity cancer patients requiring surgery as the primary modality were included in the study. Preoperative clinical examinations were done and tumor-node-metastasis staging was noted. Intraoperative, level IIb nodal tissue was dissected and sent separately.

Results: A total of 106 neck dissections were done out of which male: female ratio of 2.78:1. 49.05% patients were suffering from buccal mucosa carcinoma followed by tongue carcinoma (22.64%). 52.83% of patients had no neck involvement. Among neck positive cases, pN1 was the most common presentation. Out of these, only 8 (7.54%) neck dissections had level IIb positive.

Conclusions: Dissection of the level IIb region in patients with OSCC may be required only in cases with advanced N stage, positive level IIa lymph nodes, and extra capsular spread. Further evaluation can be done among various subsites of OSCC, clinical staging of tumour, occult bilateral nodal metastasis to assess the need of resection of level IIb in OSCC.

Keywords: Level IIb, Lymph node, Neck dissection, Nodal metastasis, Oral squamous cell carcinoma

INTRODUCTION

Squamous cell carcinoma of oral cavity (OSCC) contributes around 32-40% of all the head and neck cancers, with frequent metastasis to cervical lymph nodes via lymphatic drainage.^{1,2}

Cervical lymph node status is the most significant prognostic factor in the treatment of patients with OSCC. Once the tumor involves the neck nodes, survival drops by almost 50%. Even in cases with no clinical or radiologic evidence of lymph node involvement preoperatively, occult regional lymph node metastases

were revealed by histopathological analysis with an incidence of 15-34%.³ Thus, neck dissection plays vital role management of oral cancers, as it has diagnostic and prognostic value to determine adjuvant therapy depending on stages and histopathologic characteristics.

Different types and techniques of neck dissection have evolved gradually with time and experience giving improved functional results after surgery. Recent trend is to preserve the functional outcome without compromising loco regional resection and survival rate.⁴⁻⁷ Supraomohyoid neck dissection and selective neck dissection are now the most commonly used surgical

technique for detecting occult metastatic cervical lymph nodes and treating the clinically N0 neck. Supraomohyoid neck dissection removes the contents in levels I-III, to which oral cavity cancer most frequently spreads via lymphatic drainage.^{8,9} But preserves functionally important anatomic structures, such as the sternocleidomastoid muscle, the internal jugular vein, and the spinal accessory nerve (SAN).

As the cervical level II is one of the most likely regions to which OSCC tends to metastasize, meticulous dissection is needed in this area.⁹ However, level IIb clearance is technically more challenging for surgeons because of its crucial anatomic position, difficult accessibility, and important anatomic contents.

The SAN splits level II into sublevels IIa and IIb.^{10,11} The sublevel IIb, also called submuscular recess, is a triangular area bounded anteromedially by the SAN, superiorly by the skull base, inferiorly by the horizontal plane defined by the hyoid bone, and posteriorly by the posterior border of the sternocleidomastoid muscle. Lymph nodes in this region surround the upper internal jugular vein and SAN. Adequate clearance of level IIb lymph nodes require traction and elevation of the SAN. This may lead to consequent shoulder problems ranging from a difficulty at overhead abduction to a frozen shoulder due to neurapraxia and devascularization induced by dissection.¹²

Therefore, avoiding the dissection of level IIb has been increasingly proposed to overcome this complication. Some groups stated that the incidence of metastases to level IIb was rather low in OSCC. But the incidence of metastases to level IIb remains controversial, and despite various published literature, the necessity of level IIb dissection needs to be discussed further.¹³⁻¹⁸

Hence, the purpose of this study is to clarify whether level IIb dissection should be performed or avoided in the treatment of OSCC by analyzing the frequency of metastases to level IIb. The answer to this question may have some guiding significance on the clinical management strategy for OSCC.

METHODS

After taking approval from the ethics committee, this retrospective Study was conducted at the Department of ENT Dr. Babasaheb Ambedkar Memorial Central Railway Hospital, Mumbai from January 2015 to January 2019. A total 106 patients were included in the study that underwent surgery for oral squamous cell carcinoma with selective neck dissection including level IIb. Patients who underwent surgery for oral squamous cell carcinoma who were willing to give written informed consent between 18 and 75 years of age were included in the study. Patients who had prior history of head and neck cancer treatment and received any neoadjuvant, concomitant chemoradiotherapy or radiotherapy were excluded from

the study as these treatments altered the lymphatic drainage of neck nodes affecting the pattern of spread. This will bias the involvement of level IIb nodes in such cases. Patients were diagnosed with oral SCC with biopsy, clinical and radiological evaluation was done. Patients were then investigated and planned for appropriate surgery after taking consent. For all the cases, neck dissection was performed, and the levels of cervical nodes dissected were sent for histopathology separately labeled. The nodal status for level IIb was then specially followed up to know the involvement by metastatic deposits of oral SCC. Statistical analysis was done using SPSS software version 23.

RESULTS

Total of 106 cases were included in the study over a period of 5 years from 2015 to 2020. Statistical analysis was done using SPSS software version 23. There was male preponderance with a male: female ratio of 2.78:1 (Figure 1).

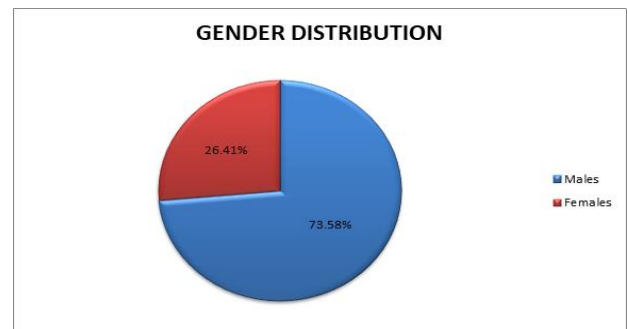


Figure 1: Graph of gender distribution.

Among various subsites, 49.05% patients were suffering from buccal mucosa carcinoma followed by tongue carcinoma (22.64%). other subsites involved were lower alveolus (11.32%), RMT (7.54%), upper alveolus (5.66%), hard palate (1.88%) and lip (1.88%).

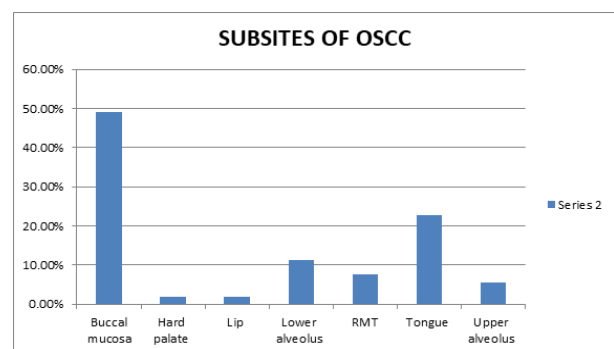


Figure 2: Distribution among various subsites of OSCC.

On histological evaluation, we observed 52.83% patients had no neck involvement. However, among cervical

metastasis we observed that pN1 was most common presentation Figure 3.

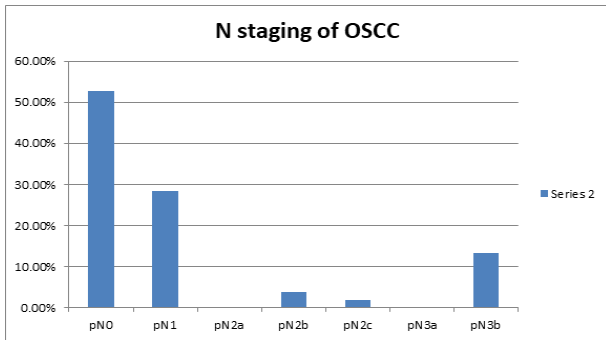


Figure 3: N staging of OSCC among all subsites involved.

In our analysis, we found that 10.60% patients had level IIb lymph node involvement on histological evaluation. 89.40% patient who underwent neck dissection did not have IIb lymph node involvement.

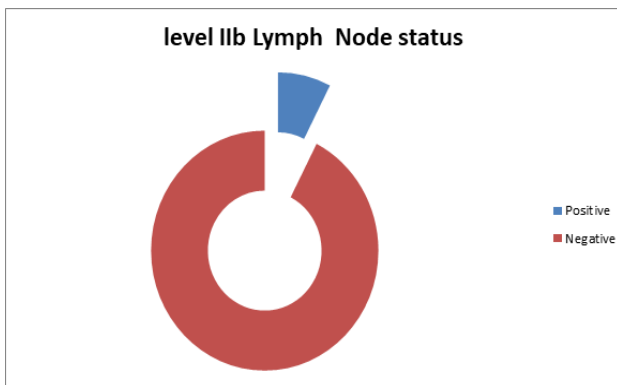


Figure 4: Level IIb lymph node involvement.

DISCUSSION

One of the most important prognostic factors in head and neck cancer is the presence or absence, level, and size of metastatic neck disease. Many tumours of the head and neck will at some stage metastasize to lymph nodes and several factors control the natural history and spread of disease.

It is widely accepted that patterns of subclinical microscopic metastases follow a similar distribution. The high incidence of occult metastases in tumours of the oral cavity forms the basis for SND and removal of the echelon lymph nodes which are the most likely sites of initial metastatic deposits. The echelon nodes of oral cavity are levels I, II and III.

The aim of SND is to reduce morbidity by preserving the SAN, the sternocleidomastoid muscle and the internal jugular vein. The SAN is important in supplying motor function to the trapezius in the majority of people, and

sacrifice of this nerve causes significant shoulder dysfunction and pain. Some authors have reported that even if the SAN is preserved, some degree of shoulder morbidity could occur.^{12,19}

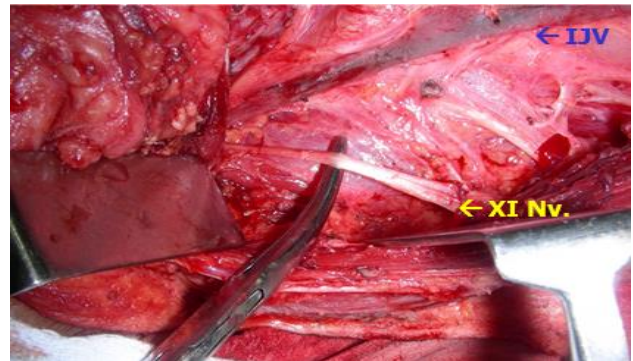


Figure 5: Image of clearance of level IIb lymph node region during selective neck dissection.

The incidence of neck metastasis in study population was 47.17%. Out of which lymph node metastasis at level IIb was detected in 10.60% study population. Maher et al found cervical level IIb lymph node metastasis in 4 out of 71 (5.6%) patients with primary OSCC and they also concluded relatively high incidence of level IIb lymph node involvement from tongue carcinoma.²⁰ Chone et al performed a retrospective analysis of 51 patients with different carcinomas of the upper aero digestive tract and found metastatic lymph nodes in the sub muscular recess in 4 of 62 neck dissections.²¹ Lim et al reported that level IIb nodal metastasis was present in four (5.4%) of 74 cases of cN0 OSCC in which an SOHND was performed.¹⁴ Elsheikh et al found a prevalence of 10% at level IIb in a molecular study on 48 patients with OSCC and N0 neck who underwent a SOHND.²² Villaret et al stated that the oral cavity has the highest overall prevalence of level IIb metastasis (10%) among head and neck squamous cell carcinomas, but these metastases are only found in 2% of cN0 cases.²³ Lea et al observed that the frequency of level IIb nodal metastasis ranges in the literature from 0 to 10.4%, with 95% confidence intervals (CI) of 0% to 44.4%.²⁴

CONCLUSION

Level IIb dissection can be avoided in clinically N0 neck in oral cavity cancer. This gives an advantage to prevent any iatrogenic injury to accessory spinal nerve and also reduce the operative time period. Routine level IIb clearance should be considered in advanced cases. By preserving level IIb, we can prevent the morbidity associated with dissection in level IIb region. The limitation of our study is limited sample size. Further evaluation can be done among various subsites of OSCC, clinical staging of tumour, occult bilateral nodal metastasis.

Funding: No funding sources

Conflict of interest: None declared

Ethical approval: The study was approved by the Institutional Ethics Committee

REFERENCES

- Kumar T, Patel MD. Pattern of lymphatic metastasis in relation to the depth of tumor in oral tongue cancers: a clinico pathological correlation. *Indian J Otolaryngol Head Neck Surg.* 2013;65(1):59-63.
- Massano J, Regateiro FS, Januário G, Ferreira A. Oral squamous cell carcinoma: review of prognostic and predictive factors. *Oral Surg Oral Med Oral Pathol Oral Radiol Endod.* 2006;102(1):67-76.
- Noguti J, De Moura CF, De Jesus GP, Da Silva VH, Hossaka TA, Oshima CT et al. Metastasis from oral cancer: an overview. *Cancer Genomics Proteomics.* 2012;9(5):329-35.
- Li XM, DI B, Shang YD, Li J, Cheng JM. Clinicopathologic features and prognostic factors of cervical lymph node metastasis in oral squamous cell carcinoma. *Ai Zheng.* 2005;24(2):208-12.
- Tao L, Lefèvre M, Callard P, Périé S, Bernaudin JF, St Guily JL. Reappraisal of metastatic lymph node topography in head and neck squamous cell carcinomas. *Otolaryngol Head Neck Surg.* 2006;135(3): 445-50.
- Woolgar JA. Histological distribution of cervical lymph node metastases from intraoral/oropharyngeal squamous cell carcinomas. *Br J Oral Maxillofac Surg.* 1999;37(3):175-80.
- Shah JP, Candela FC, Poddar AK. The patterns of cervical lymph node metastases from squamous carcinoma of the oral cavity. *Cancer.* 1990;66(1):109-13.
- Carlson ER, Cheung A, Smith B, Pfohl C. Neck dissections for oral/head and neck cancer: 1906-2006. *J Oral Maxillofac Surg.* 2006;64(1):4-11.
- Yu S, Li J, Li Z, Zhang W, Zhao J. Efficacy of supraomohyoid neck dissection in patients with oral squamous cell carcinoma and negative neck. *Am J Surg.* 2006;191(1):94-9.
- Suen JY, Goepfert H. Standardization of neck dissection nomenclature. *Head Neck Surg.* 1987;10(2):75-7.
- Robbins KT, Clayman G, Levine PA, Medina J, Sessions R, Shaha J et al. Neck dissection classification update: revisions proposed by the American head and neck society and the American Academy of Otolaryngology head and neck surgery. *Arch Otolaryngol Head Neck Surg.* 2002;128(7):751-58.
- Cheng PT, Hao SP, Lin YH, Yeh AR. Objective comparison of shoulder dysfunction after three neck dissection techniques. *Ann Otol Rhinol Laryngol.* 2000;109(8 Pt 1):761-66.
- Giordano L, Sarandria D, Fabiano B, Del Carro U, Bussi M. Shoulder function after selective and superselective neck dissections: clinical and functional outcomes. *Acta Otorhinolaryngol Ital.* 2012;32(6):376-79.
- Lim YC, Song MH, Kim SC, Kim KM, Choi EC. Preserving level IIB lymph nodes in elective supraomohyoid neck dissection for oral cavity squamous cell carcinoma. *Arch Otolaryngol Head Neck Surg.* 2004;130(9):1088-91.
- Santoro R, Franchi A, Gallo O, Burali G, de' Campora E. Nodal metastases at level IIB during neck dissection for head and neck cancer: clinical and pathologic evaluation. *Head Neck.* 2008;30(11):1483-7.
- Lea J, Bachar G, Sawka AM, Lakra DC, Gilbert RW, Irish JC et al. Metastases to level IIB in squamous cell carcinoma of the oral cavity: a systematic review and meta-analysis. *Head Neck.* 2010;32(2):184-90.
- Koerdt S, Röckl J, Rommel N, Mücke T, Wolff KD, Kesting MR. Lymph node management in the treatment of oral cancer: Analysis of a standardized approach. *J Craniomaxillofac Surg.* 2016;44(10):1737-42.
- Manola M, Aversa C, Moschillo L, et al. Status of level IIB lymph nodes of the neck in squamous cell carcinoma of the oral tongue in patients who underwent modified radical neck dissection and lymph node sentinel biopsy. *Acta Otorhinolaryngol Ital.* 2011;31(3):130-4.
- Lloyd S. Accessory nerve: anatomy and surgical identification. *J Laryngol Otol.* 2007;121(12):1118-25.
- Maher NG, Hoffman GR. Elective neck dissection for primary oral cavity squamous cell carcinoma involving the tongue should include sublevel IIB. *J Oral Maxillofac Surg.* 2014;72(11):2333-43.
- Chone CT, Crespo AN, Rezende AS, Carvalho DS, Altemani A. Neck lymph node metastases to the posterior triangle apex: evaluation of clinical and histopathological risk factors. *Head Neck.* 2000;22:564-71.
- Elsheikh MN, Mahfouz ME, Elsheikh E. Level IIB lymph nodes metastasis in elective supraomohyoid neck dissection for oral cavity squamous cell carcinoma: a molecular-based study. *Laryngoscope.* 2005;115:1636-40.
- Villaret AB, Piazza C, Peretti G, Calabrese L, Ansarin M, Chiesa F. Multicentric prospective study on the prevalence of sublevel IIB metastases in head and neck cancer. *Arch Otolaryngol Head Neck Surg.* 2007;133:897-903.
- Lea J, Bachar G, Sawka AM, Lakra DC, Gilbert RW, Irish JC. Metastases to level IIB in squamous cell carcinoma of the oral cavity: a systematic review and meta-analysis. *Head Neck.* 2010;32:184-90.

Cite this article as: Patni P, Dalmia D, Davange N, Bhagavan K, Palwade A, Goyal R. Level IIB involvement in oral cavity squamous cell carcinoma. *Int J Otorhinolaryngol Head Neck Surg* 2021;7:292-5.