

Case Report

Management of severe maxillary discrepancy in unilateral cleft lip and palate: six year follow up in a patient with tongue graft

Amrit Thapa¹, Nanda Kishore Sahoo², Balakrishnan Jayan³,
Sukhbir Singh Chopra³, Andrews Navin Kumar^{4*}

¹Department of Orthodontics and Dentofacial Orthopedics, Command Military Dental Centre, Kolkata, India

²Department of Oral and Maxillofacial Surgery, ³Department of Orthodontics and Dentofacial Orthopedics, Armed Forces Medical College, Pune, India

⁴Dental Centre, INHS Sanjivani, Willingdon Island, Kochi, Kerala, India

Received: 21 November 2020

Revised: 28 June 2021

Accepted: 29 June 2021

*Correspondence:

Dr. Andrews Navin Kumar,

E-mail: navin.andrews@gmail.com

Copyright: © the author(s), publisher and licensee Medip Academy. This is an open-access article distributed under the terms of the Creative Commons Attribution Non-Commercial License, which permits unrestricted non-commercial use, distribution, and reproduction in any medium, provided the original work is properly cited.

ABSTRACT

The purpose of this original case study was to present the efficiency of combined orthodontic and distraction osteogenesis (DO) in severe maxillary hypoplasia along with importance of tongue graft for closure of large residual palatal defect. DO has been successfully chosen in lengthening and widening the maxilla transversely to relieve anterior dental crowding and transverse discrepancies between the dental arches. A UCLP (unilateral cleft lip and palate), 15 year old male with the chief complaint of esthetic and functional problems because of skeletal class III malocclusion with anterior crossbite and severe midline shift was taken up for this modality of treatment. Considering the severity of malocclusion, combined orthodontic and DO treatment was considered adequate which was likely less invasive and equally stable procedure. RED (rigid external distractor) was used for distraction after initial alignment followed by closure of residual large palatal defect with tongue graft. Result obtained was esthetically good with acceptable occlusion considering the severity with pleasing soft tissue profile. The review was done after six year which showed remarkable skeletal stability with no dehiscence of tongue graft in palate area. The combined use of DO and orthodontic correction in ULCP case had substantial skeletal stability, improving patient esthetic and self-esteem.

Keywords: Distraction osteogenesis, RED, Maxillary hypoplasia, UCLP

INTRODUCTION

Maxillary hypoplasia is a common clinical manifestation in patients with ULCP. Clinically, this manifests as an anteriorly divergent profile, midface deficiency and class III skeletal malocclusion. Type of treatment is in accordance with the severity of the malocclusion. In moderate to severe skeletal discrepancy, combined ortho-surgical correction is required to obtain optimal results. In most instances, definitive orthognathic surgery is pursued after achieving skeletal maturity. However, in severe cases early surgical correction with LeFort I

osteotomy and DO is also indicated. This technique empowers effective adjustment of a huge maxillary hypoplasia in a developing patient with long term stable outcomes. It was subsequently adapted to the midface and upper craniofacial skeleton.¹

DO has its origins in orthopedic surgery that allows the generation of new bone in a gap between two vascularized bone surfaces in response to the application of graduated tensile stress across the bone gap.^{1,2} The technique was popularized by Ilizarov in the 1940s to lengthen long bones without the need for a graft.³

McCarthy et al was the first to report a craniofacial application in patients with congenital deformities of the mandible.⁴ Maxillary advancement by distraction osteogenesis started in late 90's and is now widely used, especially in patients with skeletal class III malocclusion caused by maxillary hypoplasia.⁵⁻¹⁰ Originally the concept was introduced as gradually advancing the maxilla after LeFort I corticotomy.¹¹ In their technique, an orthodontic facemask with elastic was used to deliver the traction force to the maxilla. In this original case study, we presented the successful treatment of a ULCP who had skeletal class III malocclusion due to severe maxillary hypoplasia was managed with RED along with closure of large residual palatal defect by tongue graft. The aim of this study was to highlight the importance of modified surgery first approach in the severe maxillary hypoplasia along with successful correction of residual large palatal defect with tongue graft followed by six years follow up of case which showed remarkable skeletal stability with no clinical sign of relapse.

CASE REPORT

An adolescent male reported to department of orthodontics with chief complaint of forwardly placed lower jaw. He had a complete left UCLP with no associated syndromes. History revealed, rehabilitation process was started with primary plastic surgeries, that is, lip repair which was performed at 4 months of age followed by palate repair at 10 months of age. The patient had undergone secondary alveolar grafting was done at the age of 11 years to facilitate the eruption of canine in occult area.

At 15 years of age, the patient had his first orthodontic appointment. A skeletal class III malocclusion with severe maxillary deficiency associated with severe crowding and skeletal midline shift towards right side. In the frontal view, the face showed mild asymmetry with the chin deviated to the left. The facial profile photograph demonstrated a marked midfacial deficiency, a retruded upper lip. The nose also showed asymmetry with flattening of the alar base on the cleft side. The sagittal interarch relationship score was 5 according to the Goslon Yardstick.¹² The patient was in the permanent dentition with a negative overjet of 3 mm and negative overbite of 9 mm, bilateral crossbite and maxillary constriction (Figure 1). At this stage, severe crowding was observed in the maxillary arch with dental midline shift towards right side. In the mandible, mild dental crowding was observed along with lingually tipped maxillary and mandibular incisors. The maxilla was short and retruded. The skeletal and soft tissue profile was severely concave.

Intervention done

Based on the initial orthodontic diagnosis, the objectives of treatment were to correct the maxillary arch constriction; level and align the maxillary and mandibular teeth in their basal bones, correcting the maxillary dental

midline deviation; coordinate the maxillary and mandibular dental arches; correct the skeletal class III relationship; achieve adequate overjet and overbite; correct the asymmetry and improve the facial esthetic; and rehabilitate the residual palatal defect. Combined orthodontic and DO treatment for maxillary advancement was planned.

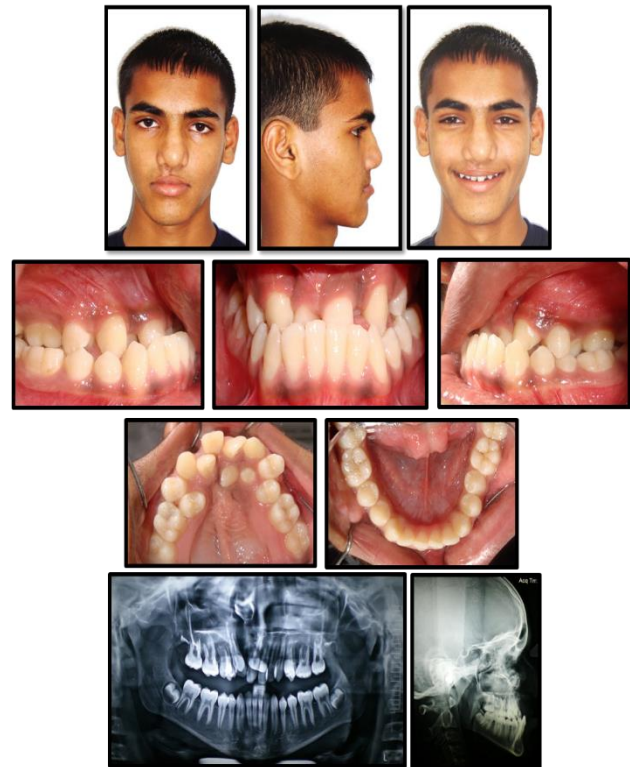


Figure 1: Facial, intraoral photographs and X-ray at 14 years of age.

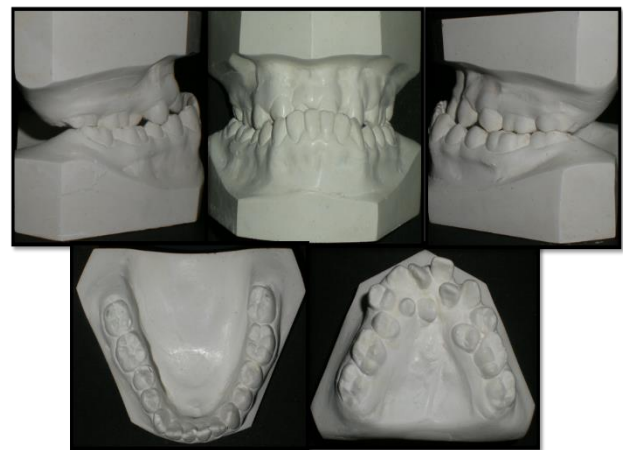

Figure 2: NiTi Expander.

The treatment was initiated by orthodontic treatment where presurgically NiTi Expander was placed to expand the narrow maxilla for transverse correction. Fixed orthodontics was done with 0.22 MBT appliances in both upper and lower arch. Therapeutic extraction of 25 was

done to alleviate crowding. Cephalometric analysis, when compared with standard, showed a skeletal class III relationship ($ANB=5.0^\circ$ and $WITS=11^\circ$) with maxillary hypoplasia ($SNA=75.0^\circ$), ($SNB=79^\circ$), low Frankfurt mandibular plane ($FMA=20^\circ$), retroclined upper and lower incisors ($U1-NA=21^\circ(4)$ and $L1-NB=12^\circ(3)$) (Table 1). Due to severe skeletal severity as revealed by clinical and cephalometric analysis, we planned DO to protract the maxilla in order to correct skeletal discrepancy and improve facial appearance.

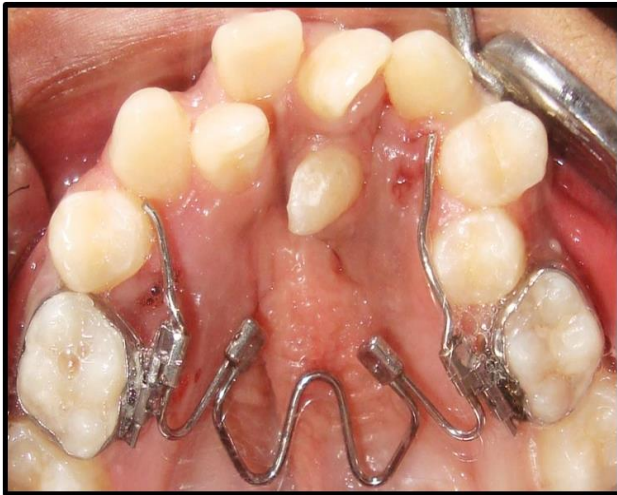

Figure 3: Rigid external distractor.

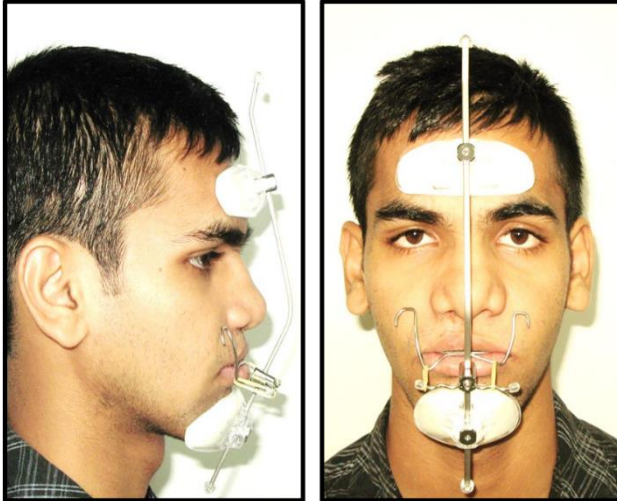


Figure 4: Facemask for retention.

After initial alignment of both arches, maxillary advancement was planned with DO. To some extent, modified surgery first approach was done as complete alignment was not done prior to surgery which hastened the alignment post surgically due to rapid acceleratory phenomenon.¹³ The objective of maxillary distraction was to advance and reposition maxilla anterior-inferiorly. The patient underwent a standard LeFort I osteotomy were incision was placed below inferior turbinate. Incision were placed around the cleft defect followed by excision

of mucosal edges were done, nasal floor was reconstructed using 4-0 vicryl than RED system (KLS Martin, Germany) was placed. DO was started from the fifth postoperative day at a rate of 1 mm per day. The maxilla was advanced 8.0 mm horizontally at point A relative to the SN plane and its perpendicular, including overcorrection of 2 mm. Rotation of maxilla was also done by asymmetric distraction to correct the yaw of patient. After osteogenesis, the RED device was kept in place for 11 days as a rigid retention, then a facemask was used for 3 months for retention were the device was kept in place passively for retention of additional eight weeks of night wearing of a face mask elastic traction (Figure 3 and 5). Such a long consolidation period was capital to guarantee a better long-term stability, thus lessening the risk of skeletal relapse.¹⁴⁻²²

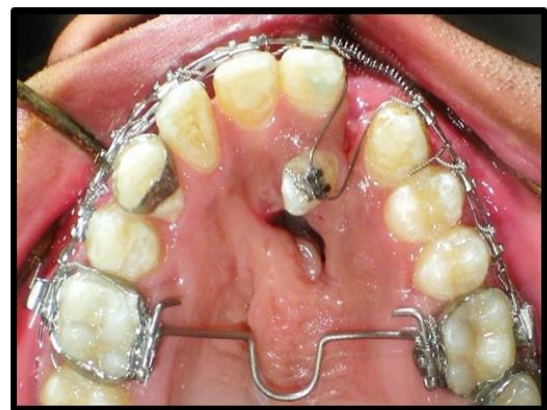

Figure 5: Lateral incisor bonding after RED.

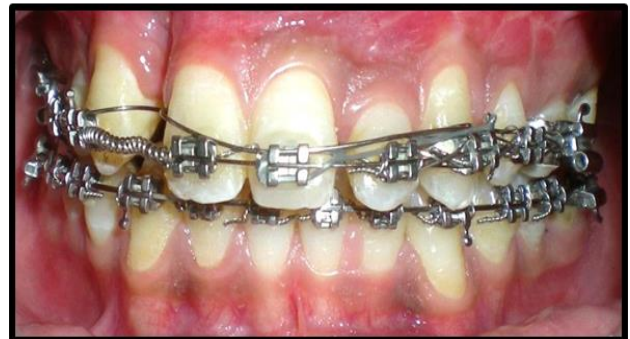

Figure 6: Stabilisation of tongue and suturing of tongue flap.

Table 1: Cephalometric reading at different period intervals.

| Parameters | Pre-treatment | Pre-surgical | Post-surgical | Six years after retention |
|----------------------|---------------|--------------|---------------|---------------------------|
| SNA | 75° 55° | 75° 55° | 81° 1° | 81° 1° |
| SNB | 79° | 79° | 79° | 79° |
| ANB | -4° | -4° | 2° | 2° |
| U1-NA | 21° (4) | 29° (12) | 25° (4) | 26° (4) |
| L1-NB | 12° (3) | 26° (6) | 23°(4) | 24°(4) |
| Wits (in mm) | -11 | -11 | 0 | 0 |
| GoGn-SN | 26° | 28° | 32° | 32° |
| FMA | 20° | 23° | 26° | 26° |
| IMPA | 86° | 90° | 92° | 93° |
| LAFH (in mm) | 65 | 69 | 63 | 63 |
| Co-A (in mm) | 81 | 84 | 85 | 85m |
| Co-Gn (in mm) | 117 (107-110) | 117 | 116 | 116 |

Finally after three months, face mask therapy discontinued and customized splint was removed. A lateral incisor was pulled labially after completion of complete distraction (Figure 5). Standard anteriorly based dorsal tongue flap of dimension 3.5×1.5 cm was raised with muscle pedicle to provide adequate vascularisation and was sutured in an unstrained position to the cleft margins with 4-0 vicryl interrupted suture. Donor site was closed using 3-0 vicryl suture. The patient was retaken for surgery for sectioning of flap and the posterior margins were secured with 4-0 vicryl suture. Healing was adequate and no dehiscence was observed (Figure 6). After achieving considerable stability, it showed remarkable improvement in speech and closure of oronasal communication due to tongue graft.²⁴ Final levelling and alignment was done to get optimum overjet and overbite.

Result

Post treatment extraoral and intraoral photographs, cephalograms and orthopantomography were taken (Figure 7). Post treatment dental casts showed acceptable alignment of upper and lower arch with corrected sagittal relationships (Figure 8). Inclination of upper and lower arch was within normal limit UI-NA=25° (4) and L1-NB=23° (4) associated with SNA increase to 81° (75°), SNB of 78° (78°), ANB increase of 2° (-5°) and IMPA increase to 92° (76°). The transverse relations were maintained while the sagittal relations have improved, finishing of the case was done with a class I canine relation bilaterally. The patient was extremely satisfied of results and had considerable improvement in his self-esteem. Surgical skeletal stability even after 6 years with minimal relapse skeletally (Table 1) and clinically (Figure 9).

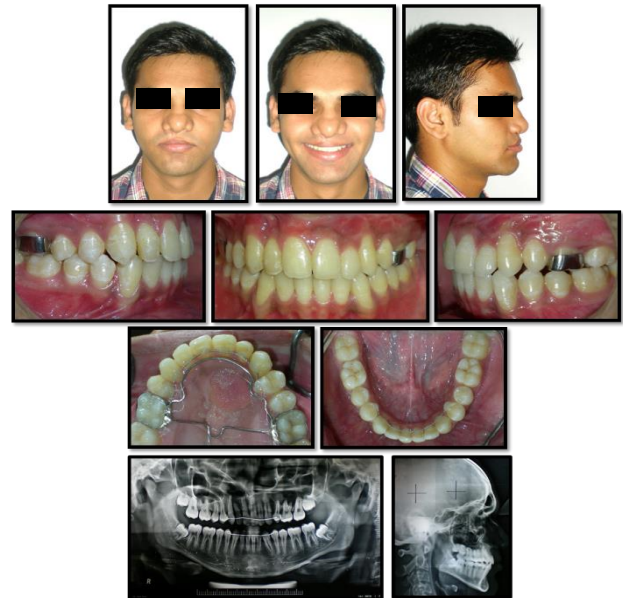


Figure 7: Post treatment extraoral and intraoral photographs, X-rays.

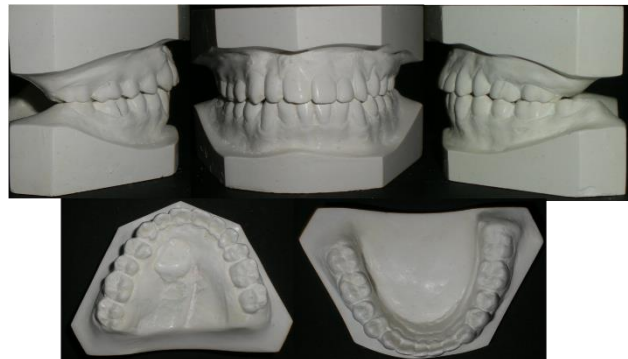

Figure 8: Post treatment dental casts.

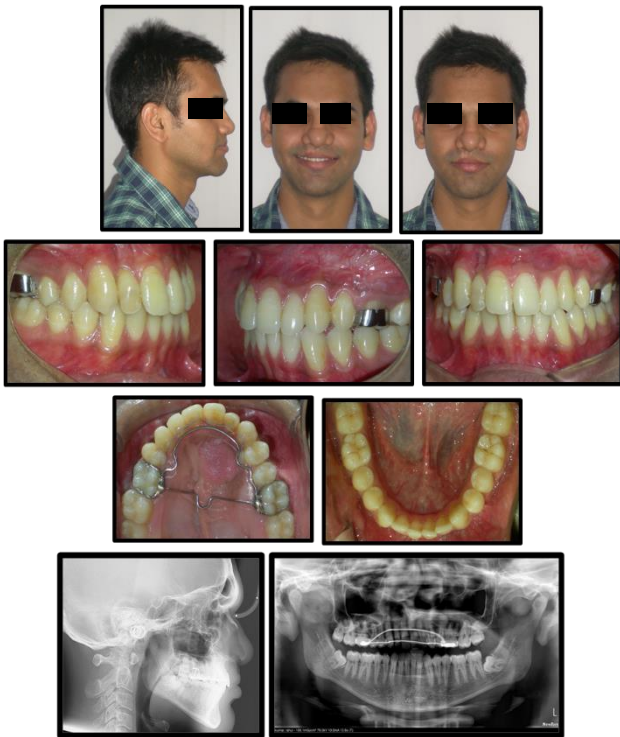


Figure 9: Post treatment extraoral and intraoral photographs, X-rays after six years.

DISCUSSION

UCLP patient's treatment is multidisciplinary team approach because of the complex skeletal discrepancy, bone deformity, multiple dental abnormalities, the necessity of various specialties involvement and the need for excellent patient cooperation. Even if solutions to all of these challenges are developed, some patients might see only partial correction depending upon the severity of cleft cases. Midfacial hypoplasia is commonly found in such cleft patients usually treated by conventional maxillary orthognathic surgery after cessation of growth, which include LeFort I advancement depending on the severity that results in the displacement of the maxilla anteriorly and stabilization afterward with rigid fixation. However, several limitations have been reported with this procedure, the literature documents 25%-40% relapse, excessive blood loss and edema, it may induce an undesirable fracture, especially in the patient with abnormal bone structure such as CLP patient.^{24,25} The frequent surgical intervention creates a tight surgical scar which is considered a factor for growth retardation and relapse of the midface after conventional orthognathic surgery. In addition, maxillary advancement more than 6 mm is difficult to achieve using this technique.²⁶

First clinical application of distraction osteogenesis, they showed the elongation of hypoplastic mandible by biological process generating new bone between the bony segments.²⁷ Traction force applied to bone also creates tension in the soft tissue, initiating a sequence of adaptive change termed distraction histogenesis.^{28,29} DO can be

performed either by intraoral distractor device or RED system. The major drawbacks of internal distractors are poor vector control, differential movement within the midface, discomfort, infection and trauma during activation.³⁰ RED system has provided a significant alternative to treat severe midface hypoplasia with minimally invasive procedure. The gradual advancement and lengthening of the soft tissue in distraction osteogenesis procedure offers proper adaptation and lowers relapse rates 5.56-10%, with more advancement.³⁰ This technique can be used to treat skeletal dysplasia at a young age (in comparison conventional surgery done afterward cessation of active growth of an individual). The intraoral customized splint was fabricated for our patient due to unusual arch form and is inexpensive, hygienic, and comfortable. It does not interfere with speech and eating. The main advantages of intraoral splint are the ability to control the direction of the force vectors at any time during the distraction process without discomfort the patient, adjusting the force to pass through or above the center of the mass of the maxilla alters the rotation movement direction, activating one side more than other allows for midline correction when the maxilla skewed to one side.³¹ The same was used in this patient were asymmetric rotation of maxilla was initiated to correct the yaw of patient towards left side. After successful distraction of maxillary segment, tongue graft was used to close to large residual palatal defect in order to prevent the oronasal communication and hyper nasality.³² The limitation of the rigid distraction technique relate to those patients with complete absence of teeth or lack of adequate bone in the cranial vault. Limited patient acceptance of the halo frame due to unaesthetic external component, in compliant patients, or parents may contribute to postoperative problems such as turning the screw to the wrong side, avoidance of daily turning due to pain and forgetting daily turning of the screw when activating the traction screw.³³ Malocclusion may occur due to traction force through the teeth. The cost of the device is only a minor disadvantage.³⁴ Some complications related to the use of the cranium fixation have been reported such as device failure, pin loosening after trauma and infections surrounding the pins.³⁵ However, patients do not complaint of the pain after placement the halo pins. Patients can shampoo their hair in the usual fashion. The device is removed in the clinic without local anesthesia after the rigid retention (consolidation) phase. Thus, we believe that it is mandatory to the professions to offer special care for patients with CLP such as innovative techniques, regular supervision and motivation to achieve the desired outcome with minor complications so that maximum benefit can be accomplished with good esthetic outcome which motivates compromised CLP cases so that they can be part of all social events.³⁶

CONCLUSION

A careful systematic treatment planning in UCLP cases with regular counseling of parents and patients is

minimum necessity for optimum result. Short presurgical period and rapid movement of teeth post surgically are important cascading effect by modified surgery first approach for management of UCLP patient by RED which not only improve overall result but also help in reduction in overall treatment duration especially in compromised craniofacial cases. It markedly improves patients esthetics and self-esteem providing long term skeletal stability with minimal relapse.

Funding: No funding sources

Conflict of interest: None declared

Ethical approval: Not required

REFERENCES

1. Samchukov ML, Cope JB, Cherkashin AM. Craniofacial Distraction Osteogenesis. St Louis MO: CV Mosby Co; 2001.
2. Codivilla A. On the means of lengthening in lower limbs, the muscles and tissues which are shortened through deformity. *Clin Orthop Relat Res.* 2008;466(12):2903-9.
3. Ilizarov GA. The principles of the Ilizarov method. *Bull Hosp Jt Dis Orthop Inst.* 1988;48(1):1-11.
4. Sugihara T, Kawashima K, Igawa H, Ohura T, Yamamura M, Ohata N. Mandibular Lengthening by gradual distraction in humans. *Euro J Plastic Surg.* 1995;18:7-10.
5. Ortiz-Monasterio F, Molina, Andrade L, Rodriguez C, Arregui JS. Simultaneous mandibular and maxillary distraction in hemifacial microsomia in adults: avoiding occlusal disasters. *Plast Reconstr Surg.* 1997;100(4):852-61.
6. Polley JW, Figueroa AA. Management of severe maxillary deficiency in childhood and adolescence through distraction osteogenesis with an external, adjustable, rigid distraction device. *J Craniofac Surg.* 1997;8(3):181-5.
7. Pelo S, Gasparini G, Petrillo DA, Tamburrini G, Rocco CD. Distraction osteogenesis in the surgical treatment of craniostenosis: a comparison of internal and external craniofacial distractor devices. *Childs Nerv Syst.* 2007;23(12):1447-53.
8. Swennen G, Dujardin T, Goris A, Mey AD, Malevez C. Maxillary distraction osteogenesis: a method with skeletal anchorage. *J Craniofac Surg.* 2000;11(2):120-7.
9. Takigawa Y, Uematsu S, Takada K. Maxillary advancement using distraction osteogenesis with intraoral device. *Angle Orthod.* 2010;80(6):1165-75.
10. Park Y, Hobar PC, Sinn DP, Peanchitlertkajorn S. Patient with Pfeiffer's syndrome treated by midfacial distraction and comprehensive orthodontics. *Am J Orthod Dentofacial Orthop.* 2011;139(2):260-70.
11. Molina F, Ortiz-Monasterio F. Mandibular elongation and remodeling by distraction: a farewell to major osteotomies. *Plast Reconstr Surg.* 1995;96(4):825-40.
12. Mars M, Plint DA, Houston WJ, Bergland O, Semb G. The Goslon Yardstick: a new system of assessing dental arch relationships in children with unilateral clefts of the lip and palate. *Cleft Palate J.* 1987;24:314-22.
13. Uribe F, Agarwal S, Shafer D, Nanda R. Increasing orthodontic and orthognathic surgery treatment efficiency with a modified surgery-first approach. *Am J Orthod Dentofacial Orthop.* 2015;148(5):838-48.
14. Cohen SR, Burstein FD, Stewart MB, Rathburn MA. Maxillary-midface distraction in children with cleft lip and palate: a preliminary report. *Plast Reconstr Surg.* 1997;99(5):1421-8.
15. Polley JW, Figueroa AA. Rigid external distraction: its application in cleft maxillary deformities. *Plast Reconstr Surg.* 1998;102(5):1360-72.
16. Hierl T, Hemprich A. Callus distraction of the midface in the severely atrophied maxilla: a case report. *Cleft Palate Craniofac J.* 1999;36(5):457-61.
17. Yeow VK, Chen PK, Lin WY, Yun C. Midface distraction osteogenesis in cleft patients: a case report. *Ann Acad Med Singap.* 1999;28(5):757-9
18. Ko EW, Figueroa AA, Polley JW. (2000). Soft tissue profile changes after maxillary advancement with distraction osteogenesis by use of a rigid external distraction device: a 1-year follow-up. *J Oral Maxillofac Surg.* 2000;58(9):959-69
19. Kuroda S, Watanabe K, Ishimoto K, Nakanishi H, Moriyama K, Tanaka E. Long-term stability of LeFort III distraction osteogenesis with a rigid external distraction device in a patient with Crouzon syndrome. *Am J Orthod Dentofacial Orthop.* 2011 Oct;140(4):550-61.
20. Swennen G, Figueroa AA, Schierle H, Polley JW, Malevez C. Maxillary distraction osteogenesis: a two-dimensional mathematical model. *J Craniofac Surg.* 2000;11(4):312-7.
21. Hierl T, Kloppel R, Hemprich A. Midfacial distraction osteogenesis without major osteotomies: a report on the first clinical application. *Plast Reconstr Surg.* 2001;108(6):1667-72
22. Krimmel M, Cornelius CP, Roser M, Bacher M, Reinert S. External distraction of the maxilla in patients with craniofacial dysplasia. *J Craniofac Surg.* 2001;12(5):458-63.
23. Vasishta SMS, Krishnan G, Rai YS, Desai A. (2012) The versatility of the tongue flap in the closure of palatal fistula. *Craniofacial Trauma Reconstr.* 2012;5(3):145-60.
24. Yamauchi K, Mitsugi M, Takahashi T. Maxillary distraction osteogenesis using Le Fort I osteotomy without intraoperative down-fracture. *Int J Oral Maxillofac Surg.* 2006;35(6):493-8.
25. Sahoo NK, Jayan B, Roy ID, Desai A. Evaluation of the hard and soft tissue changes after maxillary advancement with rigid external distractor in unilateral cleft lip and palate induced maxillary hypoplasia. *Med J Armed Forces India.* 2015;71(2):355-61.

26. Li H, Dai J, Si J, Zhang J, Wang M, Shen SG, et al. Anterior maxillary segmental distraction in the treatment of severe maxillary hypoplasia secondary to cleft lip and palate. *Int J Clin Exp Med.* 2015;8(9):16022-8
27. McCarthy JG, Schreiber J, Karp N, Thorne CH, Grayson BH. Lengthening the human mandible by gradual distraction. *Plast Reconstr Surg.* 1992;89(1):1-8.
28. Stewart KJ, Lvoff GO, White SA, Bonar SF, Walsh WR, Smart RC, et al. Mandibular distraction osteogenesis: A comparison of distraction rates in the rabbit model. *J Craniomaxillofac Surg.* 1998;26(1):43-9.
29. Triaca A, Minoretti R, Merz BR. Distraction osteogenesis of the mandibular angle and inferior border to produce facial symmetry: case report. *J Oral Maxillofac Surg.* 2000;58(9):1051-5.
30. Choi SH, Kang DY, Hwang CJ. Adult patient with hemifacial microsomia treated with combined orthodontics and distraction osteogenesis. *Am J Orthod Dentofacial Orthop.* 2014;145(1):72-84.
31. Figueroa AA, Polley JW, Ko EW. Maxillary distraction for the management of cleft maxillary hypoplasia with a rigid external distraction system. *Semin Orthod.* 1999;5(1):46-51.
32. Coghlan K, O'Regan B, Carter J. Tongue flap repair of oronasal fistula in cleft palate patients: a review of 20 patients. *J Craniomaxillofac Surg.* 1989;17(6):255-9.
33. Nout E, Wolvius EB, vanAdrichem LN, Ongkosuwito EM, Vander WKG. Complications in maxillary distraction using the RED II device: A retrospective analysis of 21 patients. *Int J Oral Maxillofac Surg.* 2006;35(10):897-902.
34. Wiltfang J, Hirschfelder U, Neukam FW, Kessler P. Long-term results of distraction osteogenesis of the maxilla and midface. *Br J Oral Maxillofac Surg.* 2002;40(6):473-9.
35. Garfin SR, Botte MJ, Waters RL, Nickel VL. Complications in the use of the halo fixation device. *J Bone Joint Surg Am.* 1986;68(3):320-5.
36. Sudhir R, Ramnathan M. Distraction osteogenesis in the maxilla for a patient with a repaired cleft lip and palate: a case report. *Spec Care Dentist.* 2011;31(5):182-7.

Cite this article as: Thapa A, Sahoo NK, Jayan B, Chopra SS, Kumar AN. Management of severe maxillary discrepancy in unilateral cleft lip and palate: six year follow up in a patient with tongue graft. *Int J Otorhinolaryngol Head Neck Surg* 2021;7:1347-53.