

Original Research Article

Morphometric cadaveric analysis of thyroid cartilage in Indian adults with comparative review of studies on other ethnic population

Satyanjaya Sahoo^{1*}, Ajay Mallick², Ashwani Sethi³, Himanshu Joshi⁴, Aroma Ghotra⁵

¹Department of ENT, Military Hospital, Shillong, Meghalaya, India

²Department of ENT, Military Hospital, Secunderabad, Telangana, India

³Army College of Medical Sciences, New Delhi, India

⁴Department of ENT, Military Hospital, Jabalpur, Madhya Pradesh, India

⁵Military Base Hospital, Tezpur, Assam, India

Received: 19 November 2020

Revised: 30 December 2020

Accepted: 31 December 2020

*Correspondence:

Dr. Satyanjaya Sahoo,

E-mail: mallick_doc@yahoo.com

Copyright: © the author(s), publisher and licensee Medip Academy. This is an open-access article distributed under the terms of the Creative Commons Attribution Non-Commercial License, which permits unrestricted non-commercial use, distribution, and reproduction in any medium, provided the original work is properly cited.

ABSTRACT

Background: The larynx besides being used in respiration, performs the function of production of voice. A thorough knowledge of relevant surgical anatomy is a must for any surgeon before performing laryngeal framework surgery (LFS). Most of the relevant anatomic details for LFS are based on Western population and the studies based on Indian population are extremely scarce. We propose to undertake this study in order to understand the relevant anatomy of the thyroid cartilage in adult Indian population and to compare these dimensions with those studied in the western population as available in literature.

Methods: Fifty-two samples of adult thyroid cartilage (35 males and 17 females) taken from cadavers were analysed. Digital Vernier callipers & goniometer were used to take morphometric measurements of the Thyroid cartilage to see for normal variation, sex differences and bilateral asymmetry. Observation were analysed by calculating mean & SD.

Results: Most parameters measured in thyroid cartilage did not show significant difference in males & females. All the parameters of thyroid cartilage except thyroid angle were higher in males than females. Bilateral asymmetry in the size of thyroid lamina was seen in majority of specimens though not statistically significant.

Conclusions: The detailed study of thyroid cartilage in the form of morphometric parameters of thyroid cartilage is useful for anatomists, radiologists, reconstructive and ENT surgeons. Comparison with other populations in the world reveals that the absolute values differ in different populations which could be due to differences in body built, racial differences and age group of cadavers.

Keywords: Larynx, Morphometry, Thyroid cartilage, Thyroid laminae

INTRODUCTION

A thorough knowledge of relevant surgical anatomy is a must for any surgeon before practising any surgical procedures. The larynx is one of the most complex organs of the human body, both anatomically and physiologically.¹ Understanding the morphology of the thyroid cartilage is absolutely necessary before contemplating the intricate laryngeal framework surgeries

(LFS) where in precision and exact measurements are essential for optimum results. Hence it is imperative that the morphometric study of the thyroid cartilage, the largest among all laryngeal cartilages, is essential. It is useful for, reconstructive and ENT surgeons and also for radiologists to plan and perform advanced surgical procedures, and to analysis imaging of larynx. Most of the relevant anatomic details for LFS are based on Western population and the studies pertaining to Indian

population are extremely scarce. We propose to undertake this study in order to understand the relevant anatomy of the thyroid cartilage in our adult Indian population and to compare these dimensions with those studied in the western population as available in literature.

METHODS

Materials and method

The data for the present study was collected from the cadaveric larynges from the department of Anatomy, of a medical college attached to a tertiary care hospital in India.

Study design

This study was cross sectional study

Sample size

Total no. of sample size was 52.

Study period

Duration of the study was January 2017 to June 2019.

Institutional ethical permission obtained before the start of the study (109/12/Dec/BH-2016 dt 26 Dec 2016).

Inclusion criteria

Cadaveric adult larynx specimens of both the sexes was included.

Exclusion criteria

Post-mortem larynx specimens of hanging, strangulation, lacerated wound over the neck, Post-mortem larynx specimens with history of any previous laryngeal surgery.

Preparation of specimens

Larynx specimens were collected and fixed in 10% formalin solution. After fixation careful dissection was done to isolate thyroid cartilages by removing muscles, ligaments, small cartilages (arytenoids, epiglottis).

Instruments used were as under (Figure 1)

An electronic digital vernier calliper with least count of 0.01 mm, goniometer, unbraided silk thread for measuring the curved distances of the laryngeal cartilages, scale, protractor for measuring different angles, tooth forceps, divider.

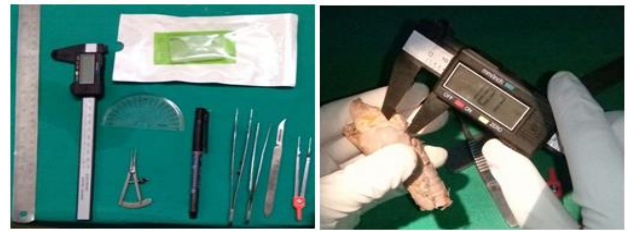

Figure 1: Instruments used and measurement procedure.

Measurements

Following parameters of thyroid cartilage were taken for measurements (Figure 2).

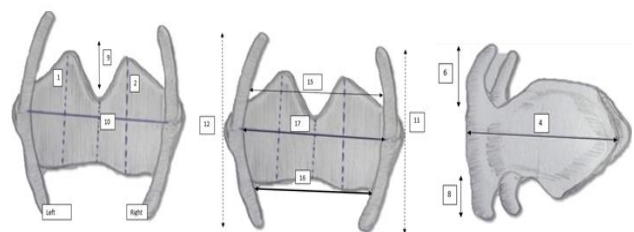


Figure 2: Measurements of thyroid cartilage (refer to text).

1 and 2 - length (height) of left and right thyroid lamina (maximum vertical distance from upper to lower border of lamina)

3 and 4 breadth of left & right thyroid lamina (horizontal distance from laryngeal prominence to the posterior margin of lamina)

5 and 6 - length of right & left superior cornu (distance from tip to base)

7 and 8 - length of right & left inferior cornu (distance from tip to base)

9 - depth of superior thyroid notch (vertical distance from highest level of laminae to the floor of the superior thyroid incisure)

10 - anterior thyroid height (distance from upper to lower thyroid incisure)

11 and 12 dorsal thyroid height (distance between tips of right & left superior and inferior horns)

13 and 14 - maximum thyroid breadth at superior and inferior tubercle (distances between two superior tubercles and two inferior tubercles) respectively

15 and 16 - upper and lower thyroid breadths (outer distances between bases of superior and inferior cornua respectively (from posterior aspect)

17 - maximum breadth of thyroid cartilage (Distance between posterior border of lamina from the posterior aspect)

18 - thyroid Angle (angle between the two thyroid laminae)

Statistical analysis

Means and proportions were calculated for continuous and categorical variables respectively. Difference between means were compared using independent sample t test. A p value<0.05 was considered statistically significant. Data entry was done in MS Excel 2013 and SPSS version 21.0 was used for statistical analysis

RESULTS

A total of 52 adult thyroid cartilages were studied, out of which 35 thyroid cartilages were of male and 17 of female. The average dimensions were significantly higher in males than in females in all parameters except in the thyroid angle dimension.

Length and breadth of left lamina was more than that of the right and more in males than in females. The left superior cornu (14.1 ± 2.7) was more than that of the right (13.8 ± 2.6). However, the length of the right inferior cornu (13.8 ± 2.6) was more than that of the left side (8.3 ± 1.9). The mean depth of the thyroid notch was significantly more in males (10.9) than those in females (5.6) giving rise to a more prominent Adams apple in adult males. There was not much significant difference between the mean height of the right (37.1 ± 4.9) dorsal thyroid cartilage when compared to the left (37.1 ± 4.9). The mean breath at the superior tubercles (37.9 ± 4.9) was more than that of the inferior tubercles (37.9 ± 4.9). The thyroid angle was the only parameter which was significantly more in females (105.6) than in males (105.6). Results of different parameters of the laryngeal specimens obtained during the study including the shows means, standard deviation maximum and minimum of various measurements of thyroid cartilages in both sexes is summarized in Table 1.

Table 1: Various morphometric measurements of thyroid cartilage.

S. no.	Dimensions measured (n=52)	Gender				Mean difference (95% CI)	p value*
		Male (n=35)		Female (n=17)			
	Mean and Range	Mean	SD	Mean	SD		
1	Length of left lamina 26.7±3.3	27.8	2.6	24.3	3.3	3.5 (1.8– 5.5)	<0.001
2	Length of right lamina 5.7±4.7	26.7	5.0	23.8	3.2	2.85(0.16-5.5)	0.038
3	Breadth of left lamina 34.4±5.9	37.1	4.3	28.78	4.6	8.4(5.7– 11.0)	<0.001
4	Breadth of right lamina 33.89±6.1	36.8	4.5	27.9	4.4	8.9(6.2-11.6)	<0.001
5	Length of left superior cornu 14.1±2.7	15.6	2.1	11.1	0.9	4.48 (3.4– 5.5)	<0.001
6	Length of rt superior cornu 13.8±2.6	15.1	2.1	11.2	0.99	3.8(2.7-4.9)	<0.001
7	Length of left inferior cornu 8.3±1.9	8.8	2.1	7.3	1.1	1.45 (0.3– 2.5)	0.011
8	Length of right inferior cornu 8.8±2.3	9.7	2.3	7.2	1.2	2.5(1.3-3.7)	<0.001
9	Depth of superior thyroid notch 9.2±3.2	10.9	2.2	5.6	1.6	5.3(4.1-6.5)	<0.001
10	Height of Ant ventral thyroid 17.1±2.3	18.0	1.7	15.2	2.3	2.7(1.6-3.9)	<0.001
11	Height of right dorsal thyroid 37.1±4.9	39.4	3.5	33.9	5.4	5.5(3.0-8.0)	<0.001
12	Height of left dorsal thyroid 37.6±4.7	39.0	3.5	34.8	5.7	4.1(1.6-6.7)	0.002
13	Maximum thyroid breadth at superior tubercle 37.9±4.9	40.0	3.7	33.4	4.0	6.6(4.3-8.8)	<0.001
14	Maximum thyroid breadth at inferior tubercle 28.3±4.3	29.7	3.6	25.3	4.0	4.4(2.2-6.7)	<0.001
15	Maximum breadth between posterior borders of thyroid 35.7±4.5	36.1	4.4	31.8	3.3	4.3(1.8-6.7)	0.001
16	Thyroid angle 93.1±12.2	87.0	8.0	105.6	9.6	18.6(23.7- 13.6)	<0.001

DISCUSSION

The primary intent of this study was to understand the normal anatomy of the thyroid cartilage in adult Indian population. Apart from anthropometric information, this has a role in application to studies in laryngeal physiology, in imaging and in surgery of the laryngeal framework. A staging system for the post-surgical classification of larynx carcinoma is based on the metrical extent of the tumour rather than on vague descriptions of its visible spread.² Hence it is obvious that the application of such an elaborate system requires a profound knowledge of the normal morphometry of the larynx. The differences in the parameters between male and female thyroid cartilages are conspicuous and mostly highly significant in males except angle between laminae, which is greater in females than males. Each result was analysed with present literature on the subject available.

Length of Thyroid Lamina: In our study we can see the length is larger in left which is similar to the trend found in the study done in North Indian population.³ Jain and Dhall (2008) had found the lamina to be larger on left side in males and on right side in females.⁴ The size of the thyroid lamina in males in our study was less compared to other studies done for the same parameter. In females, the present study was in consonance with some other studies.³⁻⁵ It was less than the findings of Ajmani who conducted their study on Nigerian population and Europeans. The difference may be attributed to racial factors.^{6,7}

Breadth of thyroid laminae

It is seen that on both the sides, the mean breadth of left thyroid lamina was larger than right. And breadth of male lamina was significantly larger compared to females. It is seen that values of the present study are comparable to those of other studies done in Indians (92-4), But it was less than the one done on Germans by Eckel et al.²

Length of superior horn of thyroid cartilage

The mean length of superior horn was more in left side for males and more on right side for females. When comparing between the sexes it was found to be significantly more in males compared to females. Earlier Jain and Dhall and Kaur et al had measured it on the two sides however others measured only the right side. Our values are similar to other studies done in Indians by Kaur et al, Jain and Dhall, Ajmani et al, and Harjeet et al. And was lesser than similar parameter measured in other races such as Nigerians and Europeans.^{6,8,9}

Length of Inferior Horn: The mean length of inferior horn in males was longer in right than the left one while in females the reverse was true. The findings in the present study were in consonance with other studies done in Indian population.^{3,4} The values are lesser than the studies done by Ajmani in Nigerians.⁶

Depth of superior thyroid notch

The depth of superior thyroid notch was found to be significantly high among males (p value<0.001). The values of the present study are quite similar to values of Jain and Dhall.⁴ **Ventral Thyroid Height:** The mean ventral thyroid height was larger in males as compared to females (P value<0.001). It is seen that the values in were in accordance with those of Jain et al and Kaur et al while it was much smaller from values found by Ajmani et al.³⁻⁶

Dorsal thyroid height

The mean dorsal thyroid height in male is marginally larger in right and in females it's in the left side. It is seen that the values in present study were less than those given by the other authors. It could be due to racial factors.^{5,8,9}

Upper breadth of thyroid cartilage at superior tubercles

The mean upper breadth of thyroid cartilage at superior tubercle is more in males compared to females. The difference being statistically significant in males (p value<0.1). This parameter values are in congruence with other studies.^{3,5} In Western literature, the parameter was higher.^{8,9}

Lower breadth of thyroid cartilage (maximum thyroid breadth at inferior tubercles)

Earlier Jain and Dhall and Kaur et al had researched this parameter. Our values are higher than them in females and same for males.^{3,4}

Breadth of thyroid cartilage at midpoints of posterior borders of laminae on posterior aspect

Our values are being variable to those found in literature. They were similar to those of Kaur et al and Patel but are lower than those of other studies.^{3,7}

Thyroid angle

Our values are matching to the other studies done for this parameter.^{2,3,9} However in a study on Brazilian population, no morphometric changes between sexes was observed.¹⁰

Most of the relevant anatomic details are based on Western population and the studies pertaining to Indian population are extremely limited, especially for measurement of thyroid cartilage thickness. Our study provides a comprehensive and detailed description of the dimensions of the thyroid cartilages of a cadaveric adult human larynx. All the major measurements of thyroid cartilage were found to be more in males as compared to females except for thyroid angle.

A fair amount of inter subject variability in the dimensions was observed. Bilateral asymmetry, though

present in majority of specimens, was insignificant. Comparison of present observations with other African and Western populations reveals that the absolute values differ in different populations which could be due to differences in body built, racial differences and age group of cadavers.

Limitations

This study was carried out in cadaver which were preserved in formalin. It is known that tissue tend to shrink in size due to fixation and preservation of cadaver. Therefore, there may be some difference/variation in the measurements obtained in this study and the actual life situation.

CONCLUSION

In conclusion the morphometric differences of laryngeal morphology is highly variable. Future studies with larger sample sizes are necessary to make accurate judgments about how laryngeal morphometry analysis can influence surgical plans in the operation room.

ACKNOWLEDGEMENTS

The authors would like to acknowledge the help of Col (Prof) MS Ahuja, HOD Department of Anatomy, ACMS, Delhi for his guidance and provision of the cadaveric specimens.

Funding: No funding sources

Conflict of interest: None declared

Ethical approval: The study was approved by the Institutional Ethics Committee

REFERENCES

1. Krishna Kumar Prasad Singh, Kumar Martand. A Morphological Study of Adult Human Larynx in Jharkhand Population. J Dent Med Sci. 2020;19(1):6;44-52.
2. Eckel HE, Sittel C, Zorowka P, Jerke A. Dimensions of laryngeal framework in adults. Surg Radiol Anatomy. 1994;16(1) 31-6.
3. Kaur R, Singla RK, Laxmi V. Morphology and Morphometry of Adult Human Thyroid Cartilage :A Cadaveric Study in North Indian Population. CIBTech J Surg. 2014;3(1):8-26.
4. Jain M, Dhall U. Morphometry of the thyroid and cricoid cartilages in adults. J Anat Soc India. 2008;57(2):119-23.
5. Ajmani ML, Jain SP, Saxena SK. A metrical study of laryngeal cartilages and their ossification. Anat Anz. 1980;148(1):42-8.
6. Ajmani ML. A metrical study of laryngeal skeleton in adult Nigerians. Journal of Anatomy. 1990;171:187-91.
7. Patel S, Bhardwaj R, Parmar P, Vaniya VH. Morphometric characteristic of thyroid cartilage in Gujarat region: A cadaveric study. J Res Medic Dent Sci. 2016;4(2):150-4.
8. Kovac T, Popović B, Marjanović K, Wertheimer V, et al. Morphometric characteristics of thyroid cartilage in people of Eastern Croatia. Coll Antropol. 2010;34 (3):1069-73.
9. Enver N, Doruk C, Kara E, Aslıyüksel H, Başaran B. A morphometric analysis of laryngeal anatomy: A cadaveric study. Tr-ENT. 2018;28 (2):71-77.
10. Jotz GP, Stefani MA, Pereira da Costa Filho O, et al. A morphometric study of the larynx. J Voice. 2014;28(6):668-72.

Cite this article as: Sahoo S, Mallick A, Sethi A, Joshi H, Ghotra A. Morphometric cadaveric analysis of thyroid cartilage in Indian adults with comparative review of studies on other ethnic population. Int J Otorhinolaryngol Head Neck Surg 2021;7:287-91.