

## Review Article

# The human larynx physiological and pathophysiological aspects

Manish Munjal<sup>1\*</sup>, Shubham Munjal<sup>2</sup>, Kanwarpreet Sadhu<sup>1</sup>, Vidushi Gupta<sup>2</sup>,  
Hem Lata Badyal<sup>2</sup>, Joginder Sidhu<sup>2</sup>, Garima Sharma<sup>2</sup>, Roop Harnoor Kaur<sup>1</sup>

<sup>1</sup>Department of ENT and HNS, <sup>2</sup>Department of Physiology, Dayanand Medical College Ludhiana, Punjab, India

**Received:** 18 November 2020

**Accepted:** 18 December 2020

### \*Correspondence:

Dr. Manish Munjal,

E-mail: manishmunjaldr@yahoo.com

**Copyright:** © the author(s), publisher and licensee Medip Academy. This is an open-access article distributed under the terms of the Creative Commons Attribution Non-Commercial License, which permits unrestricted non-commercial use, distribution, and reproduction in any medium, provided the original work is properly cited.

### ABSTRACT

In this era of minimally invasive surgical interventions, the knowledge of the physiology and pathophysiology of the larynx is vital to the laryngologist. The conventional procedure of laryngeal surgery has been superseded by functional micro-laryngeal surgery whereby now the emphasis is not on removing the pathology but reverting the function of the larynx. The surgical intervention is at the superficial mucosal level only. The physiology and pathophysiology of the larynx needs introspection.

**Keywords:** Larynx, Physiology, Pathophysiology, Micro-laryngeal surgery

## INTRODUCTION

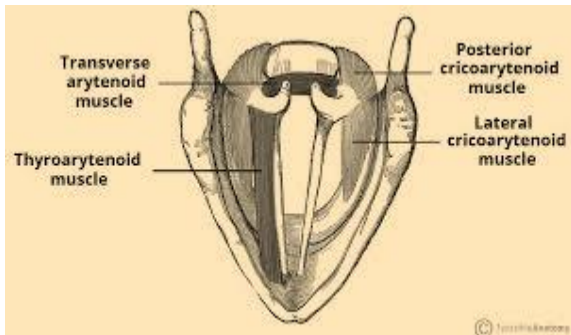
The larynx has a number of functions. The most vital is to protect the airways by IC and sphincter action during the phase of deglutition. It even serves as a valve to control air pressure and airflow, as well as a vibrator for generating sound. Either function is of fundamental importance during breathing, weight bearing and phonation.<sup>1</sup> During swallowing the primary function of the larynx is to prevent the food and liquid from entering the airway. The mechanism which protects the laryngeal inlet is reflex inhibition of respiration, closure of glottic sphincter, elevation and anterior displacement of larynx to bring its inlet under the protection of the base of tongue and clearing of ingested material from the pharynx before inspiration is resumed. The airway is also protected by the epiglottis which covers the laryngeal entrance and directs the bolus in two 'carts', into the vallecula and pyriform sinuses. Cessation of respiration during deglutition is a reflex act resulting from stimuli arising in the pharynx on entry of bolus of food. The stimuli are mediated by a central pathway through cranial nerves IX and X.<sup>1</sup> Laryngeal structure has evolved in order to contain intra thoracic pressure, so as to provide a stable fulcrum for upper limbs. Expiratory effort against a

closed glottis is known as Valsalva maneuver. During any form of exertion involving use of arms, the vocal folds are firmly adducted preventing expulsion of air and collapse of chest walls, thus providing a fixed origin for the arm and shoulder muscles. This fact is clinically important in that those who have undergone laryngectomy or who have paralysis of one or both vocal folds, with consequent difficulty in weight bearing activities due to their inability to close the glottis effectively.

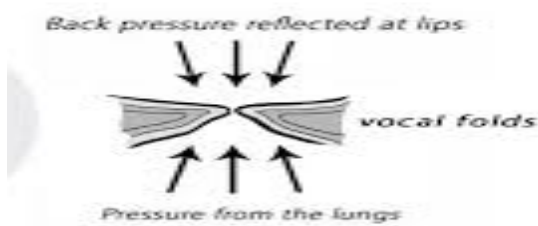
## REVIEW OF LITERATURE

During respiration, the glottis opens a fraction of second before air is drawn in by descent of the diaphragm, Green and Neil 1955.<sup>2</sup> This opening is brought about by contraction of the posterior cricoarytenoid muscles (Figure 1). Inspiratory widening of the larynx is not confined to the glottis, nor is dependent entirely on muscular activity. The inspiratory descent of the larynx, away from the hyoid bone stretches the true and false vocal cords, the arytenoids cartilages to slide laterally, and the glottis opens. Fink and Demarest, 1978.<sup>3</sup> Adjustments in glottic aperture compensate for changes

in the airway resistance arising in the nose and bronchi, Rattenborg.<sup>4</sup> (Figure 2).



**Figure 1: Muscles of the vocal cords.**



**Figure 2: Opening and closure of the vocal cords.**

Sound production originates in the larynx as a fundamental tone that is modified by various resonating chambers above and below the larynx. This interpretation of vocal cord vibration is known as myeloelastic aerodynamic theory, as contrasted with "neurochronic" theory of Husson 1950. Kirchner, 1991.<sup>5</sup> During phonation, the vocal folds act as an energy transducer that converts aerodynamic power generated by the chest, diaphragm, and abdominal musculature into acoustic power that is heard as the voice. This energy transformation occurs primarily in the space between the vocal folds; however, it is also influenced by subglottic and supraglottic parameters. The vocal cord movements during phonation have been analyzed in the high-speed recordings of the Bell telephone laboratories 1940. This classical recording of cord movements was carried out at 4000 frames per second, Fransworth.<sup>6</sup> Other techniques of observing vocal cord excursions during phonation include frontal tomography and electronic stroboscopy by Smith.<sup>7</sup>

During phonation, the vocal cord is adducted to near the midline by the cricothyroid muscle. Medial movement of the cord approximates it to the other cord by three forces which are tension in the cord, decrease in subglottic air pressure with each vibratory opening of the glottis and the sucking in effect of the escaping air i.e. the "Bernoulli effect", Van Den Berg.<sup>8</sup> When air passes from one large space to another (e.g. from lung to pharynx), through a constriction (glottis), the velocity will be greatest and the pressure least at the site of constriction, Maran.<sup>9</sup>

Fink emphasised that the axis of vibration of human vocal folds is not in the midline but is paramedian and appears bowed and elliptical.<sup>3,10</sup> If the glottis is observed in the frontal plane, it will be seen that the area of vocal cord surface, in contact with the other cord varies according to pitch. At low pitches, the cross-sectional area of the vocal folds is large. As pitch is raised, the folds become thinner, Hollen et al.<sup>11</sup>

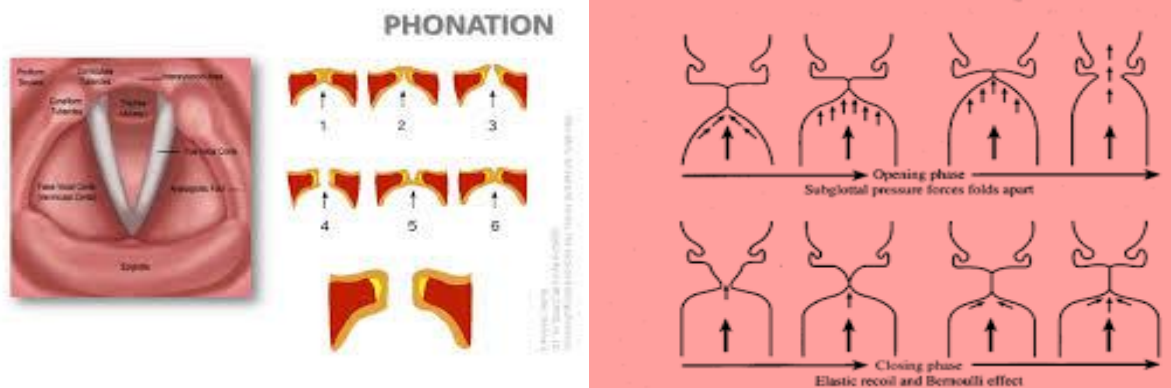
The vibratory motion of vocal folds is a complex cycle that results in voice production. Each vibratory cycle of the vocal folds consists of three phases: adduction, aerodynamic separation and recoil. Each cycle is a manifestation of a mucosal wave travelling from the inferior to the superior surface of each vocal fold. The process by which this undulating wave of movement of the mucus membrane occurs is dependent on what is known as the cover/body theory. That is, the vocalis muscle provides the firm body of the vocal fold over which the mucus membrane cover of the vocal fold is thrown by the expiratory air stream Lesley.<sup>1</sup> The periods of vocal fold contact and lack of contact in one vibratory cycle can be broadly divided into closed and open phases, respectively, with associated closing and opening phases Hirano et al.<sup>12</sup>

The closing phase of the vocal folds is more rapid than the opening phase. As the subglottic pressure increases against closed vocal folds, this pressure eventually opens the glottis. At its maximum opening, the upper lip of the vocal fold continues to move laterally, while the lower lip begins to move medially. Eventually the upper lip also begins to move medially. The medial movement of the vocal folds results from a passive recoiling force (because of an innate elasticity of the vocal folds), a drop in subglottic pressure, and the negative pressure caused by the bernoulli Effect. This negative pressure pulls the vocal folds toward each other. The initial recontact occurs at the lower lip of the vocal folds. The contact area of the vocal folds to increases until the subglottic pressure becomes high enough push the vocal folds apart. This aeromechanical cycle is repeated over and over and results in phonation. This glottal cycle results in the occurrence of a travelling wave of mucosa from the inferior to superior surface of the vocal cords, known as the mucosal wave. This mucosal wave is present only if there is a pliable mucous membrane covering the vocal fold. The speed at which mucosal wave travels is increased with the vocal fold lengthening greater airflow, greater sub-glottic pressure, and laryngeal muscle contraction, which is associated with increased fundamental frequency (Figure 3).<sup>13,14</sup>

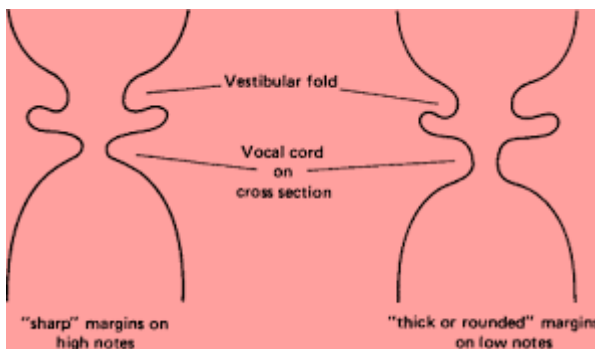
The fundamental frequency for an adult male is approximately 120 Hz (number of vibratory cycles per second), whereas for an adult female, the frequency is approximately 200 Hz. (Figure 4) The horizontal displacement of the vocal folds is called amplitude. The distance between the vocal folds is known as the glottal width. The area between the two vocal fold edges (when

viewed from above) is called the glottal area.<sup>15</sup> Normal vocal folds can produce three typical vibratory patterns: 'falsetto, modal voice, and glottal fry (Figure 5).

In the falsetto or light voice, no complete glottal closure takes place. During this high-pitched voice, only the upper edge of the vocal fold vibrates.



**Figure 3: Stages of vibration of vocal cords.**



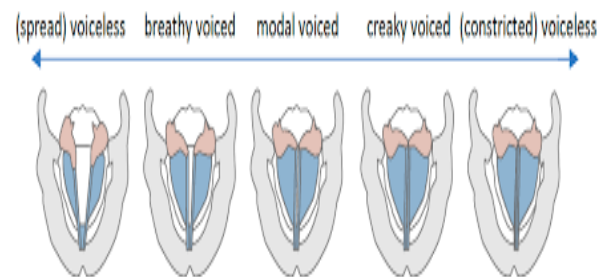
**Figure 4: Stages of vibration of vocal cords (Physiological states).**

In the modal voice, complete glottal closure occurs and results in the majority of the midfrequency range voice. During the modal phonation, the vocal fold mucosa vibrates independently of the underlying vocalis muscle. Glottal fry, or very low-frequency phonation, is characterized by a closed phase, which is relatively long compared with the open phase. During glottal fry, the mucosal cover and underlying muscle vibrate as a unit.<sup>15</sup>

Vocal abuse is any behavior or occurrence that strains or injures the vocal folds (or vocal cords). This may include excessive talking, throat clearing, coughing, inhaling irritants, smoking, screaming, or yelling.

Vocal misuse is improper voice usage such as speaking too loudly or at an abnormally high or low pitch. Frequent "vocal abuse and misuse can damage the vocal folds and cause temporary or permanent changes in vocal function, voice quality, and possible loss of voice. The factor that correlates most strongly with the formation and maintenance of many mucosal fold disorders appears to be personality. Patients can be asked to rate themselves on a seven-point talkativeness scale, where one is very untalkative, four is averagely talkative, and seven is

unusually talkative. (this scale deals with innate predisposition not the demands of work or lifestyle).<sup>16</sup>



**Figure 5: Stages of vibration of vocal cords (Pathological states).**

**CONCLUSION**

A precise know how of the dynamics of the voice box is essential to detect qualitative change in the voice and rehabilitate the same. An early diagnosis of a neoplastic pathology with timely intervention and a better prognosis is thereby possible.

*Funding: No funding sources*  
*Conflict of interest: None declared*  
*Ethical approval: Not required*

**REFERENCES**

1. Mathieson L, Carding P. Physiology of larynx. Scott Brown's Otorhinolaryngology-head and neck surgery. 7th Ed 2008; 2:164/2155-63.
2. Green JH, Neil E. The respiratory function of the laryngeal muscles. J Physiol. 1955;129(1):134.
3. Fink BR, Demarest RJ. Respiratory folding. Laryng Biomechan. 1978:15-44.
4. Rattenborg C. Laryngeal regulation of respiration. Acta Anaesthesiol Scand. 1961;5(3):129-40.

5. Weiss DA. Discussion of the neurochronaxic theory (Husson). *Arch Otolaryngol.* 1959;70(5):607-18.
6. Farnsworth DW. High-speed motion picture of the human vocal cords. *Bell Lab Record.* 1940;18:203-8.
7. Smith S. Remarks on the physiology of the vibrations of the vocal cords. *Folia Phoniatica et Logopaedica.* 1954; 6(3):166-78.
8. Van den Berg J. Myoelastic-aerodynamic theory of voice production. *J Speech Hear Res.* 1958;1(3):227-44.
9. Maran AGD. Logan Turner's disease of nose, throat, ear, 10th Ed. 1988.
10. Kotby MN, Haugen LK. The mechanics of laryngeal function. *Acta oto-laryngologica.* 1970;70(3):203-11.
11. Hollien H, Curtis JF. A laminagraphic study of vocal pitch. *J Speech Hear Res.* 1960;3(4):361-71.
12. Hirano M, Bless DM. Video stroboscopic examination of the larynx. 1993.
13. Titze IR, Jiang JJ, Hsiao TY. Measurements of mucosal wave propagation and vertical phase difference in vocal fold vibration. *J Acoust Soc Am.* 1992;91(4):2420.
14. Nasri S, Sercarz JA, Berke GS. Noninvasive measurement of traveling wave velocity in the canine larynx. *Ann Otol Rhinol Laryngol.* 1994;103(10):758-66.
15. Noordzij JP, Ossoff RH. Anatomy and physiology of the larynx. *Otolaryngologic Clinics Nor Am.* 2006;39(1):1-0.
16. Bastian RW. Benign vocal fold mucosal disorders. Cummings, CW et al.-*Otolaryngology Head & Neck Surgery*, Mosby. 1998.

**Cite this article as:** Munjal M, Munjal S, Sadhu K, Gupta V, Badyal HL, Sidhu J. The human larynx physiological and pathophysiology aspects. *Int J Otorhinolaryngol Head Neck Surg* 2021;7:213-6.