

Case Report

T4 squamous cell cancer of buccal mucosa successfully treated combination of interstitial brachytherapy, concurrent chemo-radiotherapy and salvage surgery

Jyoti Sharma*, Aman Sharma, Swati Verma

Department of Radiation Therapy and Oncology, IGMC Shimla, Himachal Pradesh, India

Received: 05 November 2020

Revised: 10 December 2020

Accepted: 12 December 2020

*Correspondence:

Dr. Jyoti Sharma,

E-mail: jyotisharma217@gmail.com

Copyright: © the author(s), publisher and licensee Medip Academy. This is an open-access article distributed under the terms of the Creative Commons Attribution Non-Commercial License, which permits unrestricted non-commercial use, distribution, and reproduction in any medium, provided the original work is properly cited.

ABSTRACT

We report a case of advanced case of right sided buccal mucosa deemed inoperable achieving long term cure with a combination of interstitial brachytherapy and concurrent chemoradiotherapy (CRT) followed by salvage surgery for small recurrence. The patients were considered for upfront double plane 12 catheter implant to a dose of 25 Gy in 8 fractions at the rate of 3.125 Gy per fraction. Two fractions were delivered in a day at least 6 hours apart. Thereafter patient was subjected to CRT to a dose of 40 Gy in 20 fractions. At follow up there was complete resolution of disease barring a small induration raw area at angle of mouth, which was successfully managed by salvage surgery. Patient is now on regular follow up for 18 months from completion of treatment and is disease free for 1 year.

Keywords: Buccal mucosa, Interstitial brachytherapy implant, CRT

INTRODUCTION

Incidence of oral cavity and pharynx cancer cases in India in 2016 is 1,88,969 in both sexes combined (95% UI 106 000–118 000).¹ There is relatively high incidence of oral cancer in India is mainly because of the habit of chewing betel nut leaves rolled with lime and tobacco (mixture known as “paan”) which results in prolonged carcinogen exposure of the buccal mucosa.² It results in condition called as oral submucous fibrosis (OSF) Initially these premalignant lesions are characterized by blanching of the mucosa with marble like appearance.³ At advanced stages palpable fibrous bands become more evident along buccal mucosa and mouth opening. It is estimated that as many as 5 million individuals are affected by OSF. Treatment in early stages remains surgery. Radiotherapy in form of interstitial implants along with chemoradiotherapy is an attractive strategy providing a chance of cure in patients deemed inoperable due to large tumor burden.

CASE REPORT

We present a case of 40-year-old male of CA Rt Buccal Mucosa. Patient presented in our department with complaint of an ulcerative lesion in right angle of mouth since past 3 months. He was apparently well 3 months back when he had complaint of an ulcerative lesion in rt sided buccal mucosa of cheek. It was initially small in size and gradually progressed in size to extend up to rt angle of mouth. It was associated with pain and relieved on taking painkillers. Patient had no comorbidities at presentation. He was a non-vegetarian, ex bidi smoker 1bundle/day for 10 years, ex tobacco chewer for past 10 years and ex chronic alcoholic.

He was conscious cooperative well oriented to time place and person and there was no significant finding on general physical examination and systemic examination.

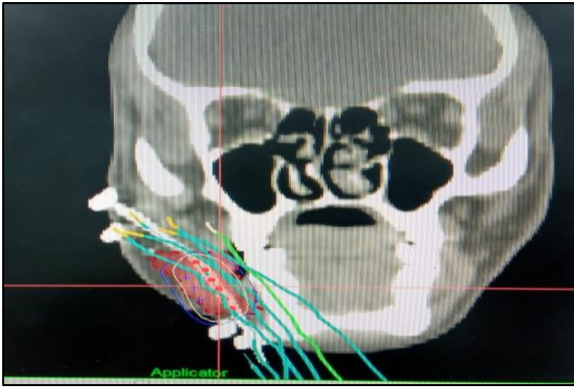


Figure 1: Planning post insertion of interstitial implants.




Figure 2: Final plan approved for implementation.

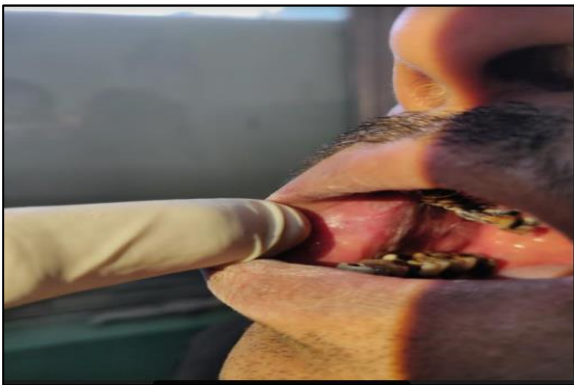

Figure 3: Patient 1-year post implant and salvage surgery.

On local examination

Oral cavity

Dental staining was present, and an ulcer proliferative lesion was present on right buccal mucosa extending from right angle of mouth to the 2nd molar 5×3 cm involving gingivobuccal sulcus and was tender on palpation.

Histopathology from right buccal mucosa lesion biopsy revealed well differentiated squamous cell cancer.

CECT from base of skull to neck revealed a localised homogenous isodense mass lesion of size 3.9×2.3×2 cm in the right perioral region. Lesion apparently involved the right orbicularis oris levator anguli oris and zygomaticus minor.

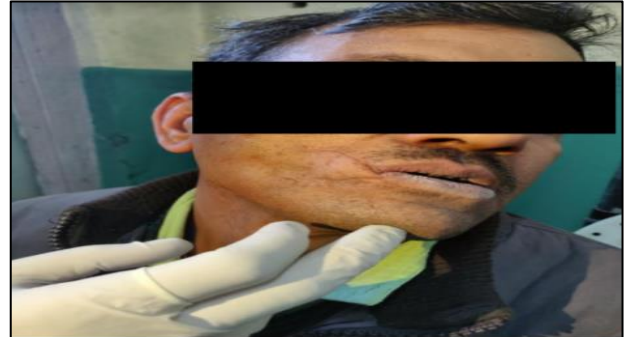

Figure 4: Patient 1-year post implant and salvage surgery.

Treatment modality

Patient was treated with 2 cycles of NACT based on TPF. Otolaryngology opinion was sought, and patient was considered inoperable. In view of patient inoperable patient was planned on upfront interstitial brachytherapy followed by EBRT to buccal mucosa and neck.

12 catheter double plane implant was done under GA on right buccal mucosa. Dose prescribed was 25 Gy/8# (3.125 Gy/# 6 hours apart with lead shield between right buccal mucosa and right mandible.

Patient reported after 2 and half weeks after procedure with good general condition. Implant scar healed 4x3 cm induration present with ulceration at the angle of mouth trismus present.

CRT was given 40 Gy/20#/4 weeks with injection cisplatin 50 mg IV weekly.

Patient reported after 1 and half weeks after EBRT with complaints of change in taste and dryness of mouth. Interstitial needle scar marks were present and there was a raw area over the angle of mouth. There was no palpable cervical LAP. On digital palpation there were post RT changes and no evidence of growth.

Patient was kept on 2 monthly follow up. Patient came after 2 months on 2nd follow up with complaints of dry mouth decreased appetite and on local examination there was raw area on right angle of mouth extending posteriorly. There was no LAP. Otolaryngology review was taken, and a punch biopsy was advised which revealed moderately differentiated squamous cell carcinoma right angle of mouth.

In view of raw area revealing the small recurrent disease, Otolaryngology opinion was again sought for salvage

surgery. Further workup of the patient was done at same department.

MRI revealed enhancement with total thickness of 9 mm length of 3.5 mm right buccal space with loss of fat planes.

Wide local excision of squamous cell carcinoma of right buccal mucosa with supraomohyoid neck dissection with reconstruction was performed with 1cm margin and split skin graft harvested from left thigh.

On HPE depth of invasion was 2 mm, tumor involved subepithelial connective tissue with uninvolved facial skin. Margins were uninvolved by invasive carcinoma and distance from closest margin was 6 mm There was no LVSI or PNI identified. 24 lymph nodes were resected all free from tumor metastasis.

DISCUSSION

This case report reveals a successful management of an advanced case of right sided buccal mucosa with the modalities of interstitial brachytherapy and concurrent CRT with the residual disease managed with the help of surgical salvage. Patient is disease free since past one year and is on follow up. He has a better quality of life as assessed by EORTC QLQ-H and N35, EORTC QLQ-C30 questionnaire and improvement in dysphagia as assessed by The MD Anderson dysphagia inventory.⁵

Buccal mucosa is the most common cancer of oral cavity in India. There are many challenges in the treatment of advanced stage cancers which are deemed inoperable. Interstitial brachytherapy implants (which has a long history initially starting from radium needles being implanted in superficial tumors in 1930s) systems have been developed in course of time and offer a chance of cure to those patients who are not surgical candidates/ deemed inoperable. In our setup the patient benefitted in terms of cure from the disease and attained good quality of life with the help of interstitial brachytherapy and CRT.

CONCLUSION

Interstitial Brachytherapy is an excellent treatment modality with not only the major advantages of organ

preservation better cosmetic and functional outcomes but also a better quality of life in oral cavity cancers. It may offer a last chance of cure in patients of advanced stage cancer who are deemed inoperable.

Funding: No funding sources

Conflict of interest: None declared

Ethical approval: Not required

REFERENCES

1. Mathur P, Sathishkumar K. Report From National Cancer Registry Programme, India (National Centre for Disease Informatics and Research, Bengaluru, India). Cancer Statistics, 2020.
2. Ko YC, Huang YL, Lee CH, Chen MJ, Lin LM, Tsai CC. Betel quid chewing, cigarette smoking and alcohol consumption related to oral cancer in Taiwan. J Oral Pathol Med. 1995;24(10):450-3.
3. grawal M, Pandey S, Jain S, Maitin S. Oral cancer awareness of the general public in Gorakhpur city, India. Asian Pac J Cancer Prev. 2012;13:5195-9.
4. Prisciandaro JJ, Foote RL, Herman MG, Lee SJ, LaJoie WN, Van Blarcom AB et al. A buccal mucosa carcinoma treated with high dose rate brachytherapy. Journal of Applied Clinical Medical Physics. 2005;6:8-12.
5. Chen AY, Frankowski R, Bishop-Leone J, Hebert T, Leyk S, Lewin J et al. The development and validation of a dysphagia-specific quality-of-life questionnaire for patients with head and neck cancer: the M. D. Anderson dysphagia inventory. Arch Otolaryngol Head Neck Surg. 2001;127(7):870-6.
6. Puthawala A, Nisar Syed AM, Gamie S, Chen YJ, Londrc A, Nixon V. Interstitial low-dose-rate brachytherapy as a salvage treatment for recurrent head-and-neck cancers: long-term results. Int J Radiat Oncol Biol Phys. 2001;51(2):354-62.

Cite this article as: C Sharma J, Sharma A, Verma S. T4 squamous cell cancer of buccal mucosa successfully treated combination of interstitial brachytherapy, concurrent chemo-radiotherapy and salvage surgery. Int J Otorhinolaryngol Head Neck Surg 2021;7:167-9.