

## Case Report

# Late dacrocystitis in post endoscopic angiofibroma excision: a case report

Manish Munjal<sup>1\*</sup>, Priyanka Arora<sup>2</sup>, Porshia Rishi<sup>1</sup>, Harjinder Sidhu<sup>1</sup>, Shubham Munjal<sup>1</sup>,  
Shivam Talwar<sup>1</sup>, Salony Sharma<sup>1</sup>, Nimisha Kaushal<sup>1</sup>

Department of ENT and HNS, Department of Ophthalmology, Dayanand Medical College, Ludhiana, Punjab, India

**Received:** 03 November 2020

**Accepted:** 10 December 2020

### \*Correspondence:

Dr. Manish Munjal,

E-mail: manishmunjal@yahoo.com

**Copyright:** © the author(s), publisher and licensee Medip Academy. This is an open-access article distributed under the terms of the Creative Commons Attribution Non-Commercial License, which permits unrestricted non-commercial use, distribution, and reproduction in any medium, provided the original work is properly cited.

### ABSTRACT

Epiphora consequent to stenosis of the nasolacrimal duct, an unexpected sequel of trans nasal endoscopic angiofibroma excision was treated by a revision flap dacryocystorhinostomy.

**Keywords:** Stenosis, Dacryocystorhinostomy, Nasolacrimal duct, Angiofibroma, Endoscopic

### INTRODUCTION

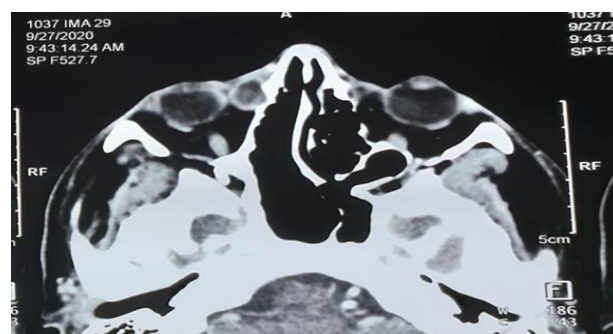
Angiofibroma characteristically arises from the periosteum of the sphenopalatine foramen, widens and occupies the pterygopalatine fossa with a potential to spread three dimensionally. The conventional external approaches have been taken over by the trans nasal endoscopic ones.<sup>1</sup> Angiofibroma excision necessitates a lateral plane/para-sagittal plane access, involving a sequential, medial maxillectomy, anterior decompression of pterygopalatine fossa and ligation of the internal maxillary as well as the sphenopalatine arteries.<sup>2,3</sup> The intervening naso-lacrimal duct, confronted during the medial maxillectomy stage is obliquely transected, to keep apposing edges apart and thereby synechia formation. A late restenosis is likely due to closure of the terminal resected end. We report an intriguing patient with late epiphora.

### CASE REPORT

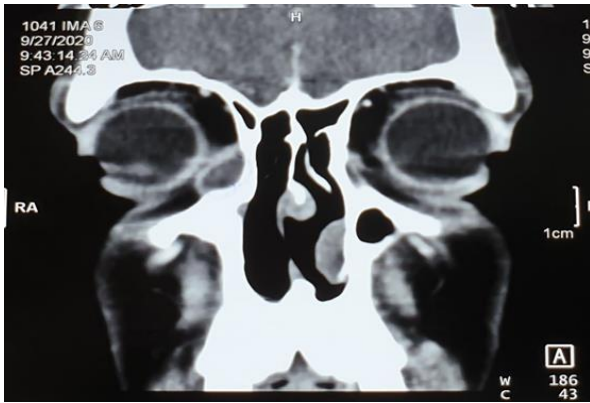
A 20-year male underwent a trans nasal endoscopic resection of angiofibroma using the medial maxillectomy Denker's approach. The nasolacrimal duct was delineated, meticulously dissected and obliquely transected high at

the junction of the roof of the maxillary sinus with the lamina papyracea. The sphenopalatine and internal maxillary arteries and veins were ligated and the benign tumor delivered. Three years following surgery, he developed epiphora, and on syringing there was regurgitation from the opposite punctum.

A computed tomography scan showed an oval balloned out lacrimal sac with a bony flake at its lower end (Figure 1, 2) patient with late epiphora.

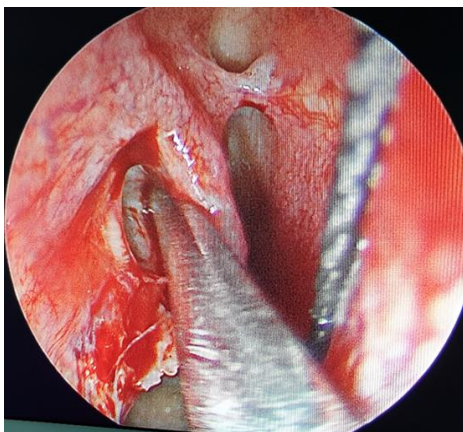


**Figure 1: Axial computed tomographic section showing balloned right lacrimal sac with a bony flake at its lower end.**



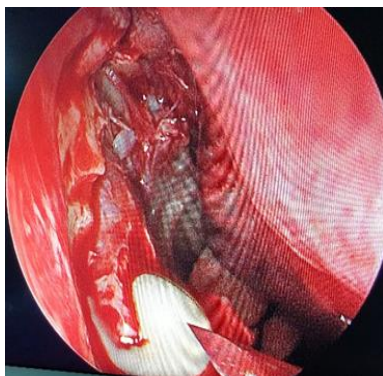**Figure 2: Coronal computed tomographic section showing dilated lacrimal sac right side.**

Patient was taken up for endoscopic dacryocystorhinostomy under local anaesthesia. A bony chip was lifted off the lacrimal sac and the residual nasocrimal duct (Figure 3). The sac and duct were marsupialised and stagnant purulent collection was drained (Figure 4 and 5).



**Figure 3: Bony chip lifted off the lacrimal sac.**

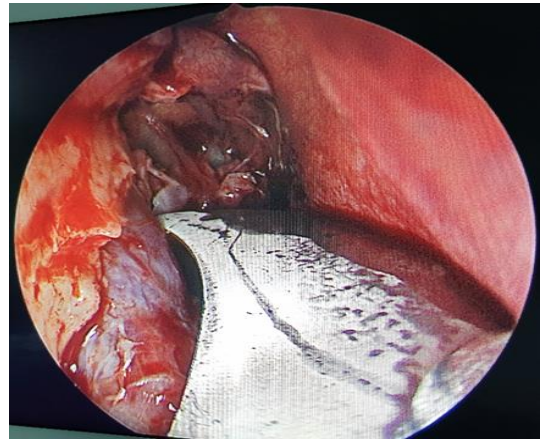
The anterior and posterior flaps of the lacrimal sac were everted and spread anteriorly over the nasomaxillary process and posteriorly over the uncinat process and the axilla of the middle turbinate (Figure 6).



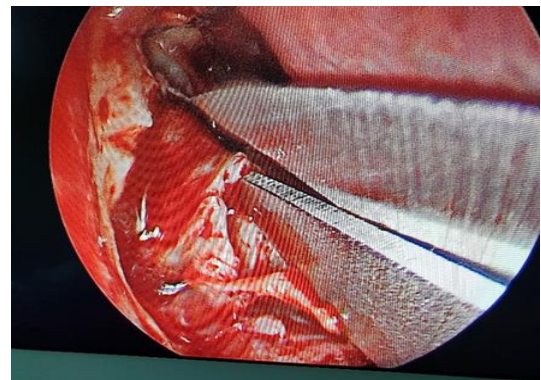
**Figure 4: Purulent collection drained out.**

Moment of the lacrimal sac on external digital pressure confirmed its position. Gelfoam was placed to keep the flaps everted.

Post-operative syringing and egress of secretions in the nasal cavity completed the dacryocystorhinostomy procedure.



**Figure 5: Lacrimal sac and duct marsupialized.**



**Figure 6: Anterior and posterior flaps of the lacrimal sac everted.**

## DISCUSSION

During endoscopic removal of angiofibroma, the nasolacrimal duct (NLD) is resected as it forms part of the medial wall of the maxillary sinus disrupting the nasolacrimal drainage system. The overall incidence of prolonged epiphora reported in literature after maxillectomy is 15.6%.<sup>4</sup>

Techniques for transected ducts include simple oblique transection without any additional procedure, silicone tube stenting, transcanalicular Silastic stenting, and marsupialization without stenting.<sup>5-7</sup>

As the nasolacrimal duct is transected obliquely during resection, the incidence of epiphora after angiofibroma removal is very less. The main cause of chronic

dacrocystitis after angiofibroma surgery by medial maxillectomy is fibrosis of the terminal resected end .

Postoperative probing of the transected healing with a nasolacrimal duct helps in preventing obstruction due to fibrotic membrane (healing) at the lower end of the transected nasolacrimal duct.

Computed tomographic dacryocystography is a technique in which radiopaque dye is instilled in the lacrimal sac and computed tomography is subsequently performed. This helps in excluding recurrent tumor and providing a surgical template in the presence of an altered anatomy.<sup>8</sup> The limiting factor being the high cost.

Late management options for chronic dacrocystitis after angiofibroma excision include stenting, endoscopic dacryocystorhinostomy (DCR) and postoperative lacrimal lavage.

The emphasis is on removal of all bony chips in the vicinity of the transected nasolacrimal duct lest during nasal packing to achieve haemostasis they may get impacted in the nasolacrimal duct with consequent epiphora.

## CONCLUSION

In major surgeries on the antero-medial region of the maxilla, the role of post-operative syringing is emphasised to confirm patency of the nasolacrimal system.

*Funding: No funding sources*

*Conflict of interest: None declared*

*Ethical approval: Not required*

## REFERENCES

1. Ardehali MM, Ardestani SH, Yazdani N, Goodarzi H, Bastaninejad S. Endoscopic approach for excision of juvenile nasopharyngeal angiofibroma: complications and outcomes. *Am J Otolaryngol.* 2010;31:343-9.
2. Nicolai P, Villaret AB, Farina D, Nadeau S, Yakirevitch A, Berlucchi M, et al. Endoscopic surgery for juvenile angiofibroma: a critical review of indications after 46 cases. *Am J Rhinol Aller.* 2010;24(2):e67-72.
3. Boghani Z, Husain Q, Kanumuri VV, Khan MN, Sangvhi S, Liu JK, et al. Juvenile nasopharyngeal angiofibroma: a systematic review and comparison of endoscopic, endoscopic-assisted, and open resection in 1047 cases. *Laryngoscope.* 2013;123(4):859-69.
4. Yeo N, Wang JH, Chung Y, Jang YJ, Lee B. Contributing Factors to Prevent Prolonged Epiphora After Maxillectomy. *Arch Otolaryngol Head Neck Surg.* 2010;136(3):229-33.
5. Bernard PJ, Lawson W, Biller HF, LeBenger J. Complications following rhinotomy: Review of 148 patients. *Ann Otol Rhinol Laryngol.* 1989;98(9):684-92.
6. Imola MJ, Schramm Jr VL. Orbital preservation in surgical management of sinonasal malignancy. *Laryngoscope.* 2002;112(8):1357-65.
7. Habib RHar-El G Management of the lacrimal system during maxillectomy. *Am J Rhinol.* 2004;18(6):367-70.
8. Glatt HJ, Chan AC. Lacrimal obstruction after medial maxillectomy. *Ophthal Surg Lasers Imag Retina.* 1991;22(12):757-8.

**Cite this article as:** Munjal M, Arora P, Rishi P, Sidhu H, Munjal S, Talwar S, et al. Late dacrocystitis in post endoscopic angiofibroma excision: a case report. *Int J Otorhinolaryngol Head Neck Surg* 2021;7:189-91.