

## Original Research Article

# Study of clinical profile, complications and management of acquired cholesteatoma in pediatric age group: a retrospective study

Rajneesh, Shradha Pawar\*, Dinesh Valse, Anil Kumar Doddamani

Department of Otorhinolaryngology, ESIC Medical College, Kalaburagi, Karnataka, India

**Received:** 01 November 2020

**Revised:** 12 December 2020

**Accepted:** 14 December 2020

### \*Correspondence:

Dr. Shradha Pawar,  
E-mail: [shrazy.1@gmail.com](mailto:shrazy.1@gmail.com)

**Copyright:** © the author(s), publisher and licensee Medip Academy. This is an open-access article distributed under the terms of the Creative Commons Attribution Non-Commercial License, which permits unrestricted non-commercial use, distribution, and reproduction in any medium, provided the original work is properly cited.

## ABSTRACT

**Background:** Chronic suppurative otitis media when delayed of early treatment results in complications. And the present study is conducted to evaluate the complications and management of acquired cholesteatoma in pediatric age group. Aim of the study was to highlight important aspects and paradigms of clinical profile of pediatric cholesteatoma, its complications and management

**Methods:** A retrospective audit of total 15 cases of acquired paediatric cholesteatoma with complications were studied aged 4-14 years, for a period of 2 years from January 2018 to 2020, at a tertiary referral Centre and teaching hospital. An analysis was made about the clinical profile of pediatric acquired cholesteatoma, its complications and the overall management.

**Results:** The male to female ratio was found to be 2:3. The most common presenting feature was foul smelling otorrhea, decreased hearing and earache with headache, fever in complicated cases. 9 cases among 15 (60%) had complications both intracranial and extra cranial. Surgery was the main modality of management of these conditions. Intraoperatively the major findings were cholesteatoma and granulation in the attic and mesotympanum with erosion of scutum.

**Conclusions:** Acquired cholesteatoma in children is more aggressive than adults, and likely to present with advanced disease with ossicular chain involvement. Patients with unreliable follow up and limited access to operating theatre, Canal Wall Down mastoidectomy is an optimal management for complete exposure and removal of cholesteatoma.

**Keywords:** Chronic suppurative otitis media, Acquired cholesteatoma, Canal wall down mastoidectomy

## INTRODUCTION

Cholesteatoma in children is characterized by a more extensive disease causing greater ossicular chain pathology, has higher recurrence rates and is more difficult to eradicate.<sup>1</sup> The most frequently encountered symptoms include otorrhea, decreased hearing and earache with post auricular swelling, headache and fever in case of complications. Surgical management aims at eradication of disease and its complete removal, rehabilitation of hearing, and creating a dry ear.

Pediatric cholesteatoma is managed surgically with either canal wall up or canal wall down procedure depending upon the individual case and extent of cholesteatoma.<sup>2,3</sup> The aim of the study was to highlight important aspects and paradigms of clinical profile of pediatric cholesteatoma, its complications and management.

## METHODS

A retrospective audit of total 15 cases of acquired paediatric cholesteatoma with complications were studied aged 4-14 years, for a period of 2 years from January 2018 to 2020 at a tertiary referral Centre and teaching

hospital in the department of ENT, ESIC Medical college & Hospital, Gulbarga. The study was approved by the Institutional Ethics Committee. Informed written consent taken from patient’s guardian or attender before the surgical procedure explaining regarding the outcome and complications. Results were tabulated using Microsoft excel version 2016. Statistical tool used is percentage represented in the form of pie chart and bar graph.

**Inclusion criteria**

Inclusion criteria were pediatric age group (1-15 years) having chronic suppurative otitis media atticofacial disease with or without complications willing to consent for surgical management were included in the study.

**Exclusion criteria**

Exclusion criteria were patients refusing to undergo relevant investigations and surgical management were excluded from the study

Data was audited including age, gender, complete history, examination which includes otoscopic examination, Examination under microscope to confirm otoscopic findings, evaluate the extent of the disease or retraction pocket and ossicular status. All the patients underwent Pure tone audiometry except for 2 children, 4 years old with Chronic Suppurative Otitis Media Atticofacial disease with complication underwent BERA.

Complete blood investigations including the HIV status and radiological investigation High resolution CT Temporal bone was done preoperatively. In case of complications relevant ophthalmology and neurological consultation taken.

After thorough evaluation of the patient and considering the anatomical factors, extent of disease, its intra and extracranial spread, the type of adequate surgical technique was decided. Either they underwent canal wall up or canal wall down based on individual case. However, patients with unreliable follow up and limited access to operating theatre, canal wall down mastoidectomy is an optimal management for complete exposure and removal.

**RESULTS**

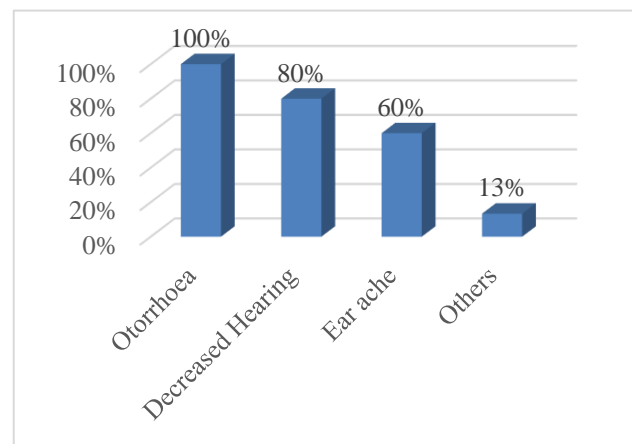
Fifteen patients met our inclusion criteria. 6 (40%) of them were male and 9 (60%) were female, with a female predominance (male: female ratio 2:3). The mean age was 9 years with a range of 4-14 years. All children were from a lower socioeconomic group with 77% of families having an annual household income of 10000 (Table 1).

The most common presenting feature was otorrhea (100%), followed by decreased hearing (80%), and earache (60%) (Figure 1).

And nine out of fifteen children had associated complications either intra or extra cranial complications, the most common presentation were mastoid abscess (55.6%), aural polyp (11.11%), facial nerve weakness (11.11%), mastoid abscess with labyrinthitis (11.11%), sigmoid sinus thrombosis (11.11%) with headache, blurring of vision and vomiting (Figure 2).

**Table 1: Distribution of children according to age and sex.**

Age group (in years)	Male	Female	Total
	Number (%)	Number (%)	Number (%)
4-10	4 (26.6)	6 (40)	10 (66.6)
11-15	2 (13.3)	3 (20)	5 (33.3)

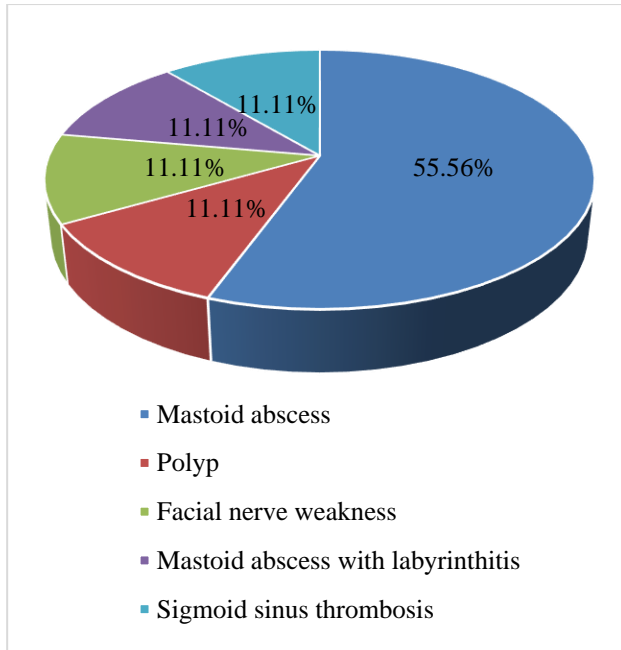


**Figure 1: Distribution of cases (%) according to the frequency of presenting complaints.**

The otoscopic findings were as follows – out of the 15 cases, 4 cases (26.66%) had retraction pocket in pars flaccida, 5 cases (33.33%) had retraction pocket in postero-superior quadrant, 1 case (6.6%) had Perforation of pars flaccida, 2 cases (13.33%) had Perforation of pars tensa, 3 cases (20%) had Scutum erosion (Table 2).

**Table 2: Distribution of cases according to otoscopy findings.**

Otoscopy findings	Number	Percentage (%)
Retraction pocket in pars flaccida	4	26.66
Retraction pocket in postero-superior quadrant	5	33.33
Perforation of pars flaccida	1	6.66
Perforation of pars tensa	2	13.33
Scutum erosion	3	20



**Figure 2: Distribution of cases (%) according to the frequency of complications.**

All the patients underwent canal wall down mastoidectomy, of which single stage operation was done in 14 patients (93.3%) and 1 patient (6.6%) underwent two stage operation, with combined approach typanoplasty with grade 3 retraction pocket in the attic (sades classification) as the first stage procedure following which the patient came back with complaints of ear discharge after 3 months. The patient had cholesteatoma in the attic, sinus tympani, erosion of all the ossicles and the dural plate erosion with meningeal protrusion, a canal wall down approach was done as second stage procedure as it was not controllable with a combined approach canal wall down allows better exposure and complete removal of the cholesteatoma

Canal wall down mastoidectomy was the preferred operation in our center as it advocates the following findings of extension of cholesteatoma into the attic (13 cases), to the sinus tympani (5 cases), dural erosion (1 case), sinus plate erosion (1 case), erosion of lateral semicircular canal with fistula (1 case).

Ossicular reconstruction was possible in 10% of the cases. Head of the malleus and incus were removed in 25% of the cases. Reconstruction was done with autologous conchal cartilage, tragal cartilage or autologous ossicles.

In all the cases with canal wall down mastoid cavity healed with epithelization within 6-8 weeks, except one case where combined approach was done at first stage presented with otorrhea at a later date where antibiotic ear drops were given and second stage canal wall down done. None of cases developed sensorineural hearing loss or facial nerve injury post operatively.

## DISCUSSION

Most common cause of acquired cholesteatoma in children is retraction pocket of the tympanic membrane, resulting from Eustachian tube dysfunction.<sup>4</sup> These pockets usually develop in pars flaccida or upper posterior region of the pars tensa.<sup>4,5</sup>

The mean age in our study was 9 years with a range of 4-14 years. Similar findings were seen in studies conducted by Schraff et al and Brown et al where the mean age at onset varies between 9 and 13 years.<sup>6,7</sup>

The most common presenting symptom in our study is otorrhea, followed by decreased hearing and ear ache. Similar findings were seen in study conducted by Wetmore et al.<sup>8</sup> On examination, findings associated with cholesteatoma include abnormal appearance of the tympanic membrane, cholesteatoma flakes, aural polyp, and hearing loss as assessed with tuning fork and pure tone audiometry. Further evaluation required to confirm the diagnosis include an otoscopic examination and visualization of the ear with a binocular microscope. Other investigations include PTA, HRCT bilateral temporal bone, Routine blood investigations as part of pre anesthetic evaluation.

A child presenting with symptoms of ear discharge and the following associated findings of crust overlying the posterior superior quadrant of the tympanic membrane should raise the suspicion of underlying cholesteatoma. Presence of pearly white squamous debris with defect in the tympanic membrane (i.e., perforation or retraction) is diagnostic of secondary or acquired cholesteatoma; however, the physical findings may be more subtle, with a bland retraction pocket or aural polyp. Shallow retraction pockets are pathologic and should be followed carefully.<sup>9</sup>

In all children with cholesteatoma hearing assessment should be performed which should be age-appropriate audiologic evaluation. Ideally, ear-specific air and bone conduction thresholds should be obtained.<sup>9</sup>

High-resolution CT scans of bilateral temporal bone, in both the axial and coronal projections, helps to delineate the extension of cholesteatoma specially into the hidden areas like sinus tympani and facial recess, explores complications and provide anatomic information regarding the status of the ossicles, involvement of the labyrinth, low lying dura or anteriorly placed sigmoid sinus, course of the facial nerve, and size of the mass.<sup>10</sup>

Nevertheless, cholesterol granuloma, frequently associated with cholesteatoma, cannot be differentiated on CT.<sup>10</sup>

CT scan is preferably done in dry ear or after the medical management of acute infection as fluid is not distinguishable from soft tissue. One of the characteristic

radiological changes associated with acquired cholesteatoma is erosion of the scutum -lateral attic wall of the middle ear space, which is best seen in the coronal view. This finding, when present, is highly suggestive of cholesteatoma. MRI is indicated for initial assessment of extension, in case of meningeal contact and also during follow up when CT scan is in doubt.<sup>10</sup>

The use of otoendoscopy is of great value in pediatric middle ear surgery.<sup>5</sup> It has advantages of visualization of hidden areas such as: sinus tympani, facial recess, anterior epitympanic space, attic, hypotympanum, medial epitympanum and retrotympanum.<sup>5,11-14</sup> For some authors, if the disease is limited to the middle ear and entirely accessible through the ear canal, it can be removed via an endoscopic permeatal attic antrostomy, thus avoiding the disadvantage to the child of an external incision.<sup>5,13,15,16</sup>

The primary goal in the management of Pediatric cholesteatoma is the total eradication of the disease and prevention of recurrence with the optimal hearing restoration. In our study canal wall down was preferred over canal wall up procedure as it ensures complete removal of cholesteatoma due to better exposure and thereby decreasing the chances of recurrence, however canal wall down has its own drawback of doctor dependency for periodic cleaning of cavity. The failure of canal wall up procedure is most common because of extension of the epithelium into the sinus tympani and facial recess.

Therefore, most of the authors prefer second look operations.<sup>17,18</sup>

Operating on an only-hearing ear, child having anesthetic risk, or a child in whom follow-up is problematic becomes a pre-operative criterion which warrants a canal wall down procedure.<sup>19</sup>

All the patients in our study underwent canal wall down mastoidectomy, of which single stage operation was done in 14 patients (93.3%) and 1 patient (6.6%) underwent two stage operation, with combined approach tympanoplasty with grade 3 retraction pocket in the attic (sades classification) as the first stage procedure following which the patient came back with complaints of ear discharge after 3 months. A canal wall down approach was done as second stage, which revealed cholesteatoma in the attic, sinus tympani, erosion of all the ossicles and the dural plate erosion with meningeal protrusion. Canal wall down allows better exposure and complete removal of the cholesteatoma.

### **Limitations**

Limitations are 1) the results cannot be generalized due to a very small sample size 2) patients could not be followed up post operatively as this was a retrospective study and

hence the incidence of recurrence and residual cholesteatoma in children cannot be commented.

### **CONCLUSION**

Acquired cholesteatoma in children is more aggressive than in adults, and likely to present with advanced disease with ossicular chain erosion as it is a dynamic process and undergoes a progressive growth with bone eroding properties. Cholesteatoma is diagnosed clinically and treatment is surgical, but the choice of surgical approach depends on the extent of the disease, erosion of the ossicles, dura or sinus plate, reliability of follow up or access to operating theatre. However, canal wall down mastoidectomy is preferred in our institution as an optimal management for complete exposure and removal of cholesteatoma.

### **ACKNOWLEDGEMENTS**

Author would like to thank all the senior colleague for their guidance and support and junior colleagues for helping complete this article.

*Funding: No funding sources*

*Conflict of interest: None declared*

*Ethical approval: The study was approved by the Institutional Ethics Committee*

### **REFERENCES**

1. McGuire JK, Wasl H, Harris T, Copley GJ, Fagan JJ. Management of pediatric cholesteatoma based on presentations, complications, and outcomes. *Int J Pediatr Otorhinolaryngol.* 2016;80:69-73.
2. Morita Y, Yamamoto Y, Oshima S, Takahashi K, Takahashi S. Acquired cholesteatoma in children: clinical features and surgical outcome. *Auris Nasus Larynx.* 2014;41:417-21.
3. Gocmen H, Kilic R, Ozdek A, Kizilkaya Z, Safak M, Samim E. Surgical treatment of cholesteatoma in children. *Int J Paediatr Otorhinolaryngol.* 2003;67:867-72.
4. De Corso E, Marchese MR, Scarano E, Paludetti G. Aural acquired cholesteatoma in children: surgical findings, recurrence and functional results. *Int J Paediatr Otorhinolaryngol.* 2006;7:1269-73.
5. Adrian JL. Endoscopic middle ear surgery in children. *Otolaryngol Clin North Am.* 2013;46:233-44.
6. Schraff S, Strasnick B. Pediatric cholesteatoma: a retrospective review. *Int J Pediatr Otorhinolaryngol.* 2006;70:385-93.
7. Brown JS. A ten-year statistical follow-up of 1142 consecutive cases of cholesteatoma: the closed vs. the open technique. *Laryngoscope.* 1982;92:390-6.
8. Wetmore RF, Konkle DF, Potsic WP, Handler SD. Cholesteatoma in the pediatric patient. *Int J Pediatr Otorhinolaryngol.* 1987;14:101-12.

9. Kathleen CY. *Pediatric clinics of North America.* 1996;43:1245-52.
10. Nevoux J, Lenoir M, Roger G, Denoyelle F, DucouLePointe H, Garabedian N. Childhood cholesteatoma. *Eur Ann Otorhinolaryngol Head Neck Dis.* 2010;127:143-50.
11. Diom ES, Cisse Z, Tall A, Ndiaye M, Pegbessou E, Ndiaye IC, et al. Management of acquired cholesteatoma in children: a 15-year review in ENT service of CHNU de FANN Dakar. *Int J Pediatr Otorhinolaryngol.* 2013;77:1998-2003.
12. Dodson EE, Hashisaki GT, Hobgood TC, Lambert PR. Intact canal wall mastoidectomy with tympanoplasty for cholesteatoma in children. *Laryngoscope.* 1998;108(7):977-83.
13. Presutti I, Gioacchini F, Alicandri-ciuffelli M, Villari D, Marchioni D. Results of endoscopic middle ear surgery for cholesteatoma treatment: a systematic review. *Acta Otorhinolaryngol Ital.* 2014;34(3):153-7.
14. Osborn AJ, Papsin BC, James AL. Clinical indication for canal wall-down mastoidectomy in a pediatric population. *Otolaryngol Head Neck Surg.* 2012;147:316-22.
15. Tarabichi M. Transcanal endoscopic management of cholesteatoma. *Otol Neurotol.* 2010;31(4):580-8.
16. Migirov L, Shapira Y, Horowitz Z, Wolf M. Exclusive endoscopic ear surgery for acquired cholesteatoma: preliminary results. *Otol Neurotol.* 2011;32:433-6.
17. Glasscock ME, Shambaugh GE. *Surgery of the Ear, 4th ed.,* W.B. Saunders Company, Philadelphia. 1990:28-47.
18. Harner SG, McDonald TJ. *Surgery of temporal bone air cell system: mastoid and petrosa.* *Otolaryngology Head and Neck Surgery,* 2nd ed., Mosby Year Book, St. Louis. 1992:2989A.
19. Dodson EE, Hashisaki GT, Hobgood TC, Lambert PR. Intact canal wall mastoidectomy with tympanoplasty for cholesteatoma in children. *Laryngoscope.* 1998;108(7):977-83.

**Cite this article as:** Rajneesh, Pawar S, Valse D, Doddamani AK. Study of clinical profile, complications and management of acquired cholesteatoma in pediatric age group: a retrospective study. *Int J Otorhinolaryngol Head Neck Surg* 2021;7:107-11.