

Original Research Article

Accuracy of FNAC in diagnosing thyroid swelling: a retrospective study

Hamsa Shetty*, Sridhar S., Gangadhar K. S.

Dept of ENT, Shimoga Institute of Medical Sciences, Shimoga, Karnataka, India

Received: 11 December 2016

Revised: 01 March 2017

Accepted: 06 March 2017

*Correspondence:

Dr. Hamsa Shetty,

E-mail: hamsa.shetty@rediffmail.com

Copyright: © the author(s), publisher and licensee Medip Academy. This is an open-access article distributed under the terms of the Creative Commons Attribution Non-Commercial License, which permits unrestricted non-commercial use, distribution, and reproduction in any medium, provided the original work is properly cited.

ABSTRACT

Background: Aim of the study was to determine the accuracy of FNAC in diagnosing thyroid swellings.

Methods: A Retrospective study was conducted over a period of one year (September 2014 to September 2015), which included 54 patients, who presented with thyroid swelling to the ENT outpatient department. All the above patients were subjected to FNAC, and were operated for the swelling, their histopathological report were correlated with the pre-operative FNAC report to determine the accuracy of FNAC in correctly diagnosing the thyroid swelling. The data in this study was analysed using statistics analysis system (SAS) software.

Results: Majority of the patients was in 3rd decade and females were more than males. The accuracy of FNAC in diagnosing thyroid swelling in the present study was found to be 77.78%.

Conclusions: FNAC is a safe, quick and inexpensive technique in diagnosing thyroid swelling with high degree of accuracy.

Keywords: Fine needle aspiration cytology, Thyroid, Accuracy

INTRODUCTION

Fine needle aspiration cytology is a simple and cost effective method to sample superficial masses found in the region of head and neck.¹ The technique is performed in the outpatient department and causes minimal trauma to the patient and carries virtually no risk of complications. Swellings located in the head and neck region including thyroid can be readily diagnosed using this technique.^{2,3}

FNAC is particularly important in planning the further treatment of the neck swelling as it helps in differentiating between benign and malignant disease. There is no evidence that tumour spreads through the skin tract created by fine hypodermic needle used in this technique.⁴ FNAC does not give same architectural detail as histology but it can provide cells from the entire

lesion, as many passes through the lesion can be made while aspirating.⁵

METHODS

A retrospective study of 96 patients who presented with thyroid swelling to the ENT outpatient department over a period of one year (September 2014 to September 2015) in our institute was done. After taking a detailed case history and completing the clinical examination, all the above patients were subjected to FNAC. FNAC was done using 22-23 gauge, 3-5 cms long needle with 10 ml syringe.

54 out of 96 patients who underwent surgical excision for the thyroid swelling were included in our study. The histopathological report of the excised specimen post-operatively was obtained in these 54 patients.

Inclusion criteria: All patients both male and females in the age group between 11 yrs to 70 yrs who presented with thyroid swelling and consented for both FNAC and subsequent surgery were included in the study.

Exclusion criteria: Patients not willing for surgical intervention. Those with severe comorbidities.

Young children less than 11 yrs and elderly patients more than 70 yrs.

The pre-operative FNAC report was compared with the histopathology report to determine the accuracy of FNAC in establishing a correct diagnosis.

Statistical analysis system (SAS) software was used for analysis of the data in this study.

RESULTS

The present study included 54 patients in the age group of 11 to 70 yrs, with maximum incidence amongst those in their 3rd decade of life. Majority were females 45 patients and males 9 patients.

On clinical examination, out of the 54 patients only 4 patients had tenderness over the swelling (Table 1) and consistency varied amongst different swellings (Table 2).

Table 1: Swelling with or without tenderness.

Tenderness	Number	Percentage
Present	4	7.41%
Absent	50	92.50
Total	54	100.00%

Table 2: Consistency of the swelling.

Consistency	Number	Percentage
Firm	43	79.63%
Hard	3	5.56%
Variable	8	14.81%
Total	54	100.00%

In cases where the FNAC features of swelling were similar to HPE report –these were considered as positive.

Table 4: Diagnostic accuracy of FNAC of thyroid swellings.

Type of thyroid swelling	Number of cases histologically proved	Number of cases proved positive by FNAC	Percentage
Follicular Adenoma	20	15	75.00%
Nodular goitre	14	11	78.57%
Hashimoto's	10	8	80.00%
Malignancy	10	8	80.00%
Total	54	42	77.78

In cases where cytological features were suspicious of a lesion which was confirmed by histopathology–these were considered as doubtful or inconclusive. In our study out of 54 patients with thyroid swelling who underwent surgery, 4 of them had a doubtful FNAC, 2 of these were reported as suspicious of malignancy and the other 2 as suspicious of hashimoto’s thyroiditis on FNAC. Since clinically diagnosis seemed more in favour of multinodular goitre, all these 4 cases underwent total thyroidectomy.

In cases where the cytological features did not correlate with histopathological features –these were considered as negative.

Table 3: Classification of FNAC report.

Neck swelling	Number of cases operated and also pre-op FNAC done	Positive	Doubtful	Negative
Thyroid	54	42 (77.78%)	4 (7.41%)	8 (14.81%)

Out of 54 patients who underwent surgery the histopathology proved 20 cases as follicular adenoma, 14 nodular goitre, 10 hashimoto’s thyroiditis and 10 as malignancy. Interestingly the 10 cases proved as hashimoto’s thyroiditis by histopathology, during pre-operative clinical examination the clinical diagnosis did not go in favour of cytological diagnosis and therefore in view of clinical diagnosis of nodular goitre in 4 patients, adenoma in 3 patients and suspected malignancy in another 3 patients all the 10 patients were operated and histopathology proved hashimoto’s in all the 10 patients thereby proving that 8 out of 10 cases was accurately diagnosed by FNAC.

Thus the overall accuracy of FNAC in thyroid swelling was found to be 77.78% in our study with 42 cases out of 54 proved positive by FNAC.

Table 5: Diagnostic accuracy of follicular adenoma thyroid.

Type of follicular Adenoma	Number of cases histologically proved	Number of cases proved positive by FNAC	Percentage
Without cystic change	14	12	85.71%
With cystic change	6	3	50.00%
Total	20	15	75.00%

Table 6: Diagnostic accuracy of malignant thyroid swellings.

Type of malignant thyroid swelling	Number of cases histologically proved	Number of cases proved positive by FNAC	Percentage
Papillary carcinoma	5	3	60.00%
Anaplastic carcinoma	3	3	100.00%
Follicular carcinoma	1	1	100.00%
Medullary carcinoma	1	1	100.00%
Total	10	8	80

Table 7: False negative results.

Type of swelling	Number of cases histologically proved	Number of cases proved false negative by FNAC	Percentage
Thyroid	54	5	9.26%

Amongst 20 cases of follicular adenoma (Figure 1) 14 were without cystic change and 6 were with cystic change. Diagnostic accuracy of aspiration cytology of follicular adenoma without cystic change was 85.71% with 12 cases proved by FNAC, in cases with cystic change the diagnostic accuracy was 50% with only 3 cases proved positive by FNAC (Table 5).

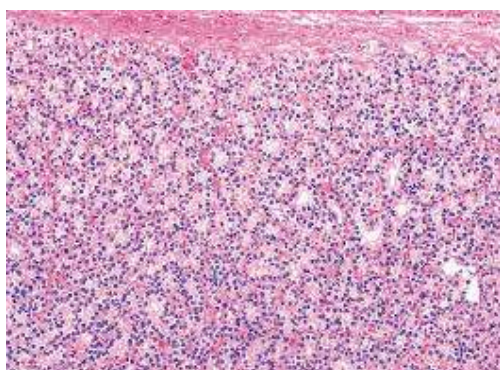


Figure 1: Follicular adenoma (microscopically production of gland acini in various size and number is the characteristic feature).

Amongst malignant thyroid swellings there were 5 papillary carcinoma (Figure 2), 3 anaplastic carcinoma (Figure 3) and 1 medullary carcinoma (Figure 4) proved histologically. The diagnostic accuracy of aspiration cytology for papillary carcinoma was 60% with 3 out of 5 cases proved positive by FNAC. The diagnostic accuracy for other types of thyroid malignancies was 100% with

all cases proved positive by FNAC in each group (Table 6).

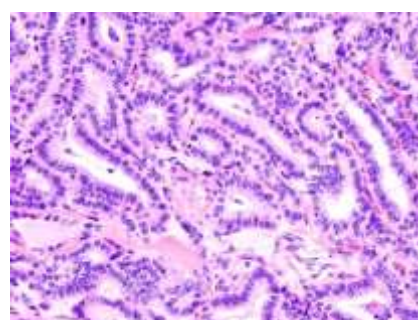


Figure 2: Papillary carcinoma thyroid (microscopically shows branching tree like pattern sharply outlined by papilliform axial fibrovascular stroma).

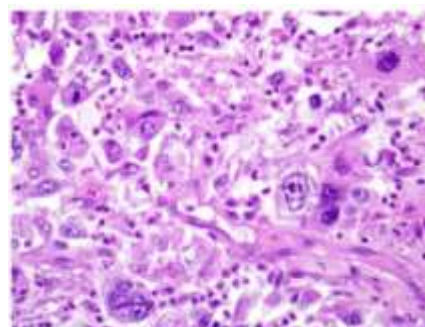


Figure 3: Anaplastic carcinoma (smear shows bizarre large malignant cells macrophage like appearance).

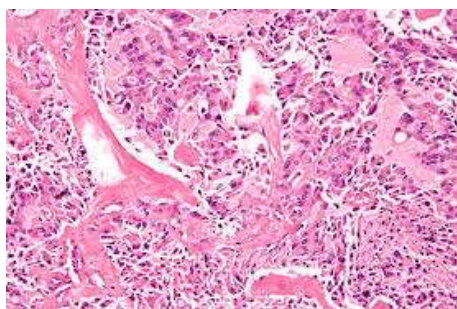


Figure 4: Medullary carcinoma (dispersed cell pattern either cuboidal or spindle shaped in a background of amorphous pink violet amyloid material).

In our study out of 54 thyroid swellings who underwent surgery, FNAC in 5 cases showed false negative results (Table 7). i.e. pre-operative cytology in 2 cases was negative for malignancy but post operatively histopathology proved papillary carcinoma. In yet another 2 cases FNAC was suggestive of colloid nodular goitre but histopathologically proved as hashimoto's thyroiditis. In another patient cytology did not suggest of follicular adenoma but clinically and post operative histopathology proved the above diagnosis.

Inadequate smear

Smears in which only blood or clear fluid without any cells was seen even after repeated aspiration were considered as inadequate smears.

In the present study, out of 54 thyroid swellings 3 were reported as inadequate smears.

DISCUSSION

The use of needle aspiration in the diagnosis of neck swellings was reported by Greig and Gray in 1904 when they aspirated lymph nodes for the identification of trypanosomes.⁶ But it was popularised in 1930's by Martin et al.⁷ Since then several reports on cytodagnosis of neck swellings have been published from different parts of the world.

The advantages of aspiration biopsy are that it is simple, rapid and economical procedure. It may clear up a questionable diagnosis or provide histological material in an obvious case without need for hospitalisation. It can easily distinguish inflammatory lesion from neoplastic lesion. It frequently eliminates a more formidable open biopsy procedure with its attendant hazards of non healing and other operative complications.

The usefulness of FNAC has been questioned through many studies in cases of small, non palpable masses (<1.5 cm).⁸⁻¹¹

In our study, the accuracy of FNAC in diagnosing thyroid swelling is encouraging, the overall accuracy rate in our

study is 77.78%, which is comparable to the findings in earlier studies, Jens Thomsen et al (1973) had 75% accuracy in their 17 aspirates from thyroid gland.¹² Hamming JF et al reported 75% accuracy in 169 cases.¹³

CONCLUSION

Fine needle aspiration cytology is a simple, quick, economical and least traumatic procedure that can be easily carried out in out patient department or at bedside with high degree of accuracy in diagnosing thyroid swellings. However the small percentage of false negative results can also be overcome if the pathologist work more closely with the clinician and correlate the clinical findings while reporting the cytological slides as well as to determine the best possible sites of aspirates from swelling.

Funding: No funding sources

Conflict of interest: None declared

Ethical approval: The study was approved by the Institutional Ethics Committee

REFERENCES

1. Svante R. Orell. Manual and Atlas of FNAC, Second edition, 1995.
2. Celeste NP, Williams JF. Fine needle aspiration biopsy of the head and neck. USA: Butterworth Heinemann; 1996: 1–13.
3. Gamba PG, Messineo A, Antonello LM, Boccato P, Blandamura S, Cecchetto G, et al. A simple exam to screen superficial masses: fine-needle aspiration cytology. *Med Pediatr Oncol.* 1995;24(2):97-9.
4. Russel RCG, William NS, Bulstrode CJK. Bailey and Love's short practice of surgery. 24th edition. London: Arnold; 2004
5. Kirk RM, Ribbans WJ. Clinical Surgery in General. 4th ed. Edinburgh: Elsevier; 2004.
6. Grieg EDW, Gray ACH. Note on the lymphatic glands in sleeping sickness. *Br Med J.* 1904;1:1252.
7. Costas A, Castro P, Martin –Granizo R, Monje F, Marron C, Amigo A. Fine needle aspiration biopsy(FNAB) for lesions of the salivary glands. *Br J Oral Maxillofa Surg* 2000;38:539-42
8. Khurana KK, Kichard VC, Izequierdo P, Rubend D, Mesonetop C. The role of untrasonographic guided fine neele aspiraton biopsy in the manamgne tof no palpable and plapbale thyroid nodule. *Thyroid.* 1998;8:511-4
9. McDonald I, Yazdi HM. Non - diagonistic fine needle aspirtion biopsy of thyorid gland. A diagnostic dilemma. *Acta Cyt.* 1996;10: 423-8
10. Mc.Henry CR, Walfish PG, Roen IB. Nondiagonitic fine needle aspiration biopsy: a dilemma in management of nodular thyroid disease. *Am Surg.* 1993;59:415-9
11. Schmidt T, Riggs MW, Speights VO. Significance of non diagonistic fine needle aspiration of the thyorid *South Med J.* 1997;90;1183-6

12. Thomson NW, Olsen WR, Hoffman GL. The continuing development of the technique of thyroidectomy. *Surgery.* 1973;73(6):913-27
13. Hamming JF, Goslings BM, Van Steenis GJ, Van Ravenswaaye H, Harmans J, Van de Velde CJH. The value of fine needle aspiration biopsy in patients with nodular thyroid disease divided into

groups of suspicion of malignant neoplasms on clinical grounds. *Arch Intern Med.* 1990;150:113-6.

Cite this article as: Shetty H, Sridhar S, Gangadhar KS. Accuracy of FNAC in diagnosing thyroid swelling: a retrospective study. *Int J Otorhinolaryngol Head Neck Surg* 2017;3:280-4.