

Case Report

Rhinofacial entomophthoromycosis: a case report

Adil Ummer, Sandeep Sreedhar*, Anwar Sadath Choolakparambu Aboobakker,
Nalakath Kunjhimon Bashir

Department of Otorhinolaryngology, MES Medical College, Malappuram, Kerala, India

Received: 26 October 2020

Revised: 27 December 2020

Accepted: 28 December 2020

***Correspondence:**

Dr. Sandeep Sreedhar,

E-mail: sreedhar.sandeep@gmail.com

Copyright: © the author(s), publisher and licensee Medip Academy. This is an open-access article distributed under the terms of the Creative Commons Attribution Non-Commercial License, which permits unrestricted non-commercial use, distribution, and reproduction in any medium, provided the original work is properly cited.

ABSTRACT

Rhinofacial entomophthoromycosis or conidiobolomycosis is a rare subcutaneous mycosis seen in immunocompetent people and shows significant male preponderance. It is caused by a saprophytic fungus 'conidiobolus coronatus' or rarely conidiobolus incongruus. The mode of transmission is probably inhalation of fungal spores, which implant in nasal mucosa and cause an orofacial granulomatosis. It is reported mainly in tropical and subtropical countries. The infection is frequently underreported since it requires high level of clinical suspicion. Histopathology and fungal culture are the diagnostic modalities. No single antifungal drug has been found to give consistent results against this infection. Here we present a case of rhinofacial entomophthoromycosis (conidiobolomycosis) in an adult male with a disfiguring lesion over the dorsum of nose. The patient was started on itraconazole initially. Following no response to the treatment, he was administered potassium iodide solution. The patient was observed to have symptomatic improvement, but was lost to follow up.

Keywords: Conidiobolomycosis, Entomophthoromycosis, Rhinofacial

INTRODUCTION

Entomophthoromycosis is a chronic, inflammatory or granulomatous fungal disease that is generally restricted to subcutaneous or submucosal nasal tissue. It consists of two entities: basidiobolomycosis caused by *basidiobolus ranarum*, and conidiobolomycosis caused by *conidiobolus coronatus* or rarely *conidiobolus incongruus*. Though histologically indistinct, the two are mycologically and clinically separate entities. Conidiobolomycosis is usually seen in immunocompetent people and affects their nasal submucosa and paranasal sinuses with gradual involvement of nasal skin, glabella, cheek, upper lip, and pharynx. Clinical presentation, histopathologic examination and culture of biopsied tissues combined aids in the diagnosis of conidiobolomycosis. Although not life threatening, the disease may cause facial disfigurement.^{1,2}

CASE REPORT

A 26-year-old male presented with nasal obstruction of 3 years duration in addition to swelling and ulceration of dorsum of nose for the past 6 months. He complained of pain over left cheek for 6 months and swelling of upper lip since 3 months. On examination, ulcerative lesion infested with maggots, over the dorsum of nose was seen (Figure 1). Thick crusts were observed in both nasal cavities.

A diagnostic nasal endoscopy revealed septal perforation, thick crust in bilateral middle meatus, and bilateral inferior turbinate hypertrophy (Figure 2).

CT paranasal sinus showed soft tissue thickening in nose, bilateral premaxillary, periorbital frontal regions with erosion of nasal bone on left. It also showed the presence

of mucosal opacification in left maxillary sinus and left nasal cavity with hyperdense contents in the centre (Figure 3).

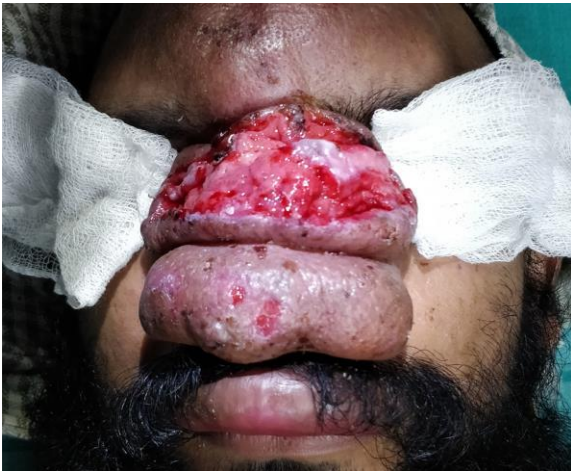

Figure 1: Rhinofacial ulcerative lesion.

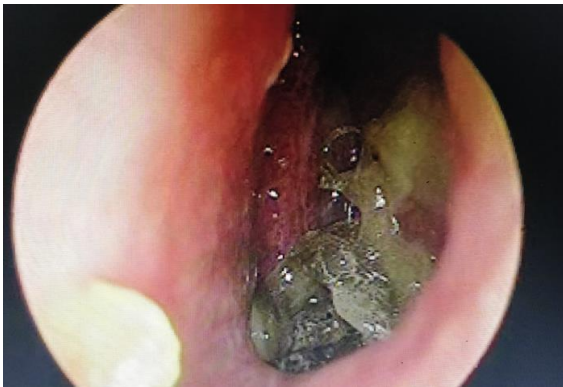

Figure 2: Diagnostic nasal endoscopy showing thick crust in nasal cavity.

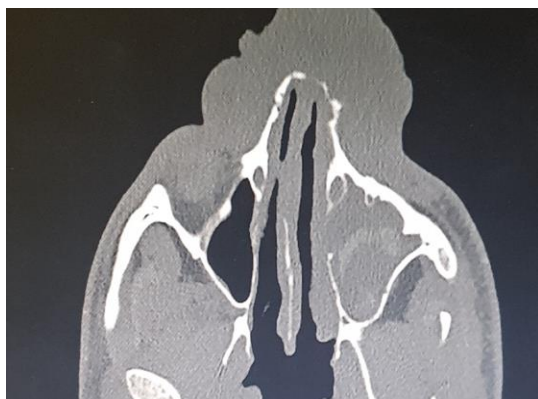

Figure 3: CT paranasal sinus showing opacification of left maxillary sinus with hyperdense contents and soft tissue thickening in bilateral premaxillary area.

Histopathological examination revealed broad pauciseptate hyphae, right angled branching, granulomatous inflammation in the dermis and subcutis,

foreign body giant cells, histiocytes, lymphocytes, epithelioid cells, eosinophils, plasma cells and eosinophil microabscess (Figure 4).

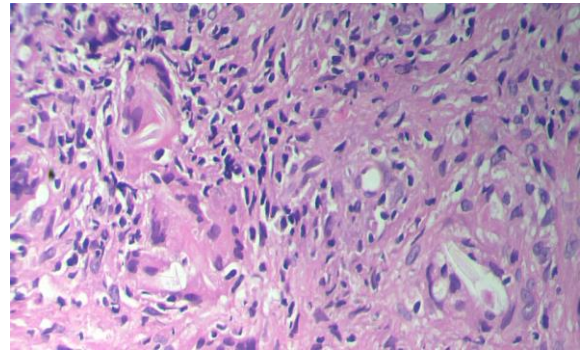


Figure 4: Histopathology showing pauciseptate hyphae and foreign body giant cells.

The maggots were removed and nasal douching and cleansing was done. The patient was started on oral itraconazole 200 mg twice daily for 2 months. Following no response to itraconazole, the patient was given supersaturated solution of potassium iodide. It was administered as oral drops dissolved in milk, starting with 5 drops gradually increased to 16 drops. The patient was observed to have symptomatic improvement, but was lost to follow up.

DISCUSSION

Entomophthoromycosis is a rare disease, with few cases reported in the tropical and subtropical areas of Africa, Asia and Americas.³ The first human infection was reported by Joe in Indonesia in 1960.⁴ A systematic review done by Gupta et al in 2019 mentions that a total of 75 cases have been reported from the Indian subcontinent over 50 years span.⁵

The case presented here conforms to the clinical picture characteristic of *Conidiobolus coronata* infection aided by confirmatory investigation reports. The infection commonly affects males in the age group 20-50 years and agricultural workers are particularly prone for this infection. The disease presents as a submucosal granuloma in the region of the inferior turbinate, spreads to involve the nasal sinuses, upper lip, forehead and cheek and may produce extensive facial deformity.⁶ Bones are usually spared but it can spread to adjacent paranasal sinuses, facial soft tissues and the orbit.^{2,7}

Diagnosis is mainly by biopsy and fungal culture. Histologically, entomophthorales are characterised by a chronic granulomatous inflammatory reaction comprising lymphocytes, eosinophils, histiocytes and foreign body type of multinucleated giant cells. The central portion comprises few broad septate hyphae ensheathed by amorphous eosinophilic material called the Splendore-Hoeppli phenomenon characteristic of entomophthorales.²

The choice of treatment for conidiobolomycosis including dosage and duration remains unclear. Different antifungals like itraconazole, cotrimoxazole, ketoconazole, amphotericin B, and terbinafine are being used with varying success rates. Combination of azoles and potassium iodide has been known to provide long lasting results. Surgical resection is usually not recommended for fear of spread of infection but the effectiveness of surgical debridement of paranasal sinuses followed by antifungal agents has been mentioned in some case reports. Relapses are common even after successful treatment. Hence the importance of regular follow up.^{8,9}

CONCLUSION

Conidiobolomycosis is a rare fungal infection which does not respond well to the conventional anti-fungal therapy. However, early recognition of the disease and prompt treatment with potassium iodide along with various antifungal agents positively alter the course of the disease with minimal cosmetic deformities. But patient compliance to the treatment and prolonged follow up may impose challenges to the treating physician, if the patient is not co-operative. The role of surgical debridement is limited to reducing cosmetic deformities in the later stages of the disease.

Funding: No funding sources

Conflict of interest: None declared

Ethical approval: Not required

REFERENCES

1. Chowdhary A, Randhawa HS, Khan ZU, Ahmad S, Khanna G, Gupta R, et al. Rhinoentomophthoromycosis due to Conidiobolus coronatus. A case report and an overview of the disease in India. *Sabouraudia*. 2010;48(6):870-9.
 2. Menon S, Pujary K, Kudva R, Ramaswamy B. Rhinofacialentomophthoromycosis. *Case Rep*. 2018;2018.
 3. Shaikh N, Hussain KA, Petraitiene R, Schuetz AN, Walsh TJ. Entomophthoromycosis: a neglected tropical mycosis. *Clinic Microbiol Infect*. 2016;22(8):688-94.
 4. Nathan MD, Keller Jr AP, Lerner CJ, Davis JC. Entomophthorales infection of the maxillofacial region. *Laryngoscope*. 1982;92(7):767-9.
 5. Gupta N, So Neja M. Diagnosis and Treatment of Conidiobolomycosis: A Review of 75 Cases from the Indian Subcontinent. *J Clinic Diagnost Res*. 2019 Mar 1;13(3).
 6. Nayak DR, Pillai S, Rao L. Rhinofacial zygomycosis caused by Conidiobolus coronatus. *Ind J Otolaryngol Head Neck Surg*. 2004;56(3):225-7.
 7. Souza JM, Sproesser Junior AJ, Felippu Neto A, Fuks FB, Oliveira CA. Rhino facial zygomycosis: case report. *Einstein*. 2014;12(3):347-50.
 8. Sigera LS, Janappriya GH, Lakshan MT, Pitigalage NJ, Jayasekera PI, Dayasena RP, et al. Rhinofacial Conidiobolomycosis: A Case Series and Review of the Literature. *Ear Nose Throat J*. 2020:0145561319892475.
 9. Thomas MM, Bai SM, Jayaprakash C, Jose P, Ebenezer R. Rhinoentomophthoromycosis. *Ind J Dermatol Venereol Leprol*. 2006;72(4):296.
1. Chowdhary A, Randhawa HS, Khan ZU, Ahmad S, Khanna G, Gupta R, et al. Rhinoentomophthoromycosis due to Conidiobolus coronatus. A

Cite this article as: Ummer A, Sreedhar S, Aboobakker ASC, Bashir NK. Rhinofacial entomophthoromycosis: a case report. *Int J Otorhinolaryngol Head Neck Surg* 2021;7:382-4.