

Original Research Article

Prevalence of Gerlach tonsil: a mucosa associated lymphoid tissue aggregation in the nasopharynx

Ramesh Varadharajan*, Sonee Thingujam

Department of Otorhinolaryngology and Head and Neck Surgery, Aarupadai Veedu Medical College and Hospital, Kirumampakkam, Puduchery, India

Received: 24 October 2020

Accepted: 26 November 2020

***Correspondence:**

Dr. Ramesh Varadharajan,

E-mail: rameshent@gmail.com

Copyright: © the author(s), publisher and licensee Medip Academy. This is an open-access article distributed under the terms of the Creative Commons Attribution Non-Commercial License, which permits unrestricted non-commercial use, distribution, and reproduction in any medium, provided the original work is properly cited.

ABSTRACT

Background: The major aggregate of mucosa associated lymphoid tissue located in the nasopharynx is the adenoid. The minor aggregate located in the nasopharynx is the Gerlach tonsils or tubal tonsils. The Gerlach tonsils are well described in the text books. But unlike the adenoids they are rarely visualized during routine endoscopic examination. Several studies conducted in children for recurrence of adenoids or serous otitis media after surgery; have reported tubal tonsil hypertrophy widely. This study in adults aims to see the prevalence of Gerlach or tubal tonsils visible during nasal endoscopy.

Methods: The case records of 155 adult patients, aged between 18-50 years, who underwent pre-operative diagnostic nasal endoscopy for the management of septal deviations, chronic Sinusitis, nasal polyposis or eustachian dysfunction between Jan. 2019 to March 2020 are retrospectively reviewed and the endoscopy findings analyzed and presented.

Results: Gerlach tonsil hypertrophy is reported to be more prevalent in children than in adults. When hypertrophied, the Gerlach tonsils can cause symptoms in adults also and can be visualized during nasal endoscopy. In this adult study, we report a 0.6% incidence of Gerlach tonsil hypertrophy.

Conclusions: The possibility of a Gerlach tonsil hypertrophy is to be remembered during nasal endoscopy in adult patients presenting with symptoms of eustachian dysfunction and past history of allergic rhinitis and adeno tonsillectomy. Comparing the size of the contra lateral torus tubaris and the eustachian tube opening during the act of swallowing is helpful in diagnosis.

Keywords: Tubal tonsil, Gerlach tonsil, Mucosa-associated lymphoid tissue

INTRODUCTION

In humans the mucosa associated lymphoid tissue (MALT) is located all over the mucosa and are divided into inductive and effector sites.¹ Those located in the nasal and oral mucosa play an important role, being the first inductive sites for sampling the antigens or organisms entering the nose and mouth and initiating the immune response.

The term Gerlach tonsil was coined by Gerlach Joseph (1820-1896) a German anatomist. They are located in the lateral wall of the nasopharynx adjacent to the torus tubaris and commonly known as the tubal tonsils.

At birth the nasal MALT is not well developed. In children the tonsils and adenoid play an important role in the development of immunity as the other organs responsible for development of immunity are not yet fully developed.²

During early childhood due to the exposure to various antigens, the cellularity of the nasal MALT increases and the adenoids become more prominent; and are commonly known as the “physiological hypertrophy”. Children with mold allergy have an increased risk of developing adenoid hypertrophy.³

Allergic rhinitis or chronic inflammation has been quoted as an important factor in oral MALT hypertrophy especially the lingual tonsils and for the increased activity of nasal MALT and Adeno tonsillar hypertrophy in children.⁴⁻⁶

When the major MALT aggregates such as the Tonsils and Adenoid are removed by surgery at a younger age, the remaining minor MALT aggregates undergo a reactive hyperplasia to continue the immune responses as there is a continued antigen challenge.⁷

Clinically this hyperplasia manifests as adenoid recurrence or granular pharyngitis, lingual tonsil hypertrophy or tubal tonsil hypertrophy.

Gerlach or tubal tonsil hypertrophy (TTH) is reported to be more prevalent in children. Many studies conducted in children for recurrence of adenoid or serous otitis media after surgery have identified TTH as one of the causative factors. To our knowledge the prevalence of TTH in adults has not been studied.

This study was done in adult patients with history of allergic rhinitis and conditions like nasal polyps or chronic sinusitis, to assess whether a continued allergen challenge or a chronic inflammation could trigger a nasal MALT hyperplasia and TTH in adults also and could such hypertrophy be identified endoscopically.

METHODS

The case records of 155 adult patients aged 18-50 years who attended the Department of Otorhinolaryngology and Head & Neck Surgery of Aarupadai Veedu Medical College Hospital, Puduchery, between Jan. 2019 to March 2020 for treatment of various conditions like DNS, nasal polyps, chronic sinusitis, allergic rhinitis, eustachian dysfunction were selected. All the patients had a pre-operative nasal endoscopy and the endoscopic findings were analyzed.

Patients with symptoms such as nasal obstruction, nasal discharge, head ache, post nasal drip, ear fullness or tinnitus were included in the study.

Children and patients below 18 years of age and those exposed to chemical fumes, working in hot furnaces and those with history of smoking or co morbidities like diabetes were excluded from the study.

After a detailed history, a complete ENT examination was done. Complete blood count, screening for diabetes, absolute eosinophil count and total IgE estimation were done. X-ray and CT of the PNS were done. Additional investigations like audiogram and tympanogram were done for patients presenting with ear symptoms.

After an informed consent and a xylocaine sensitivity test; patients were taken up for diagnostic nasal

endoscopy under local anesthesia. Both the nasal cavities were packed with 2.5 cm wide ribbon gauze strips soaked in a mixture of 10 ml of 4% topical xylocaine and 0.01% decongestant nasal drops for 10 minutes.

Karl Storz 0* rigid adult nasal endoscope with camera and monitor attachment was used. After patient positioning, the packs were removed and classical 3 pass endoscopy was done. Any abnormalities related to the nasal cavities, adenoids, torus tubaris or fossa of Rosenmuller were documented and analyzed.

Treatment plans were explained to the patients and they underwent appropriate surgical treatments such as endoscopic septoplasty or polypectomy or FESS with good post-operative care and follow up.

RESULTS

There was a total of 155 patients who had undergone preoperative endoscopies. There was a total of 84 males 54% and 71 females 46%. The age group of the patients varied from 18 to 50 years and the age wise distribution of the patients is shown in (Figure 1).

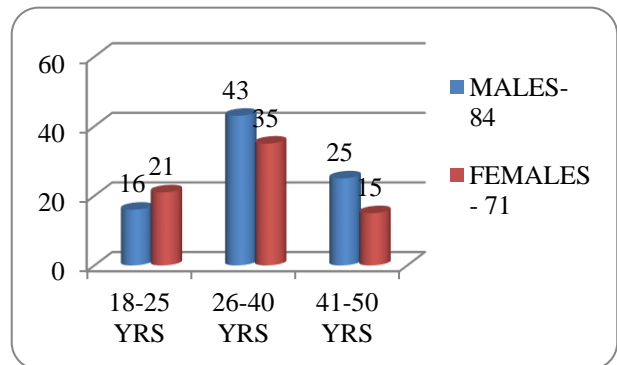


Figure 1: Age wise distribution of patients.

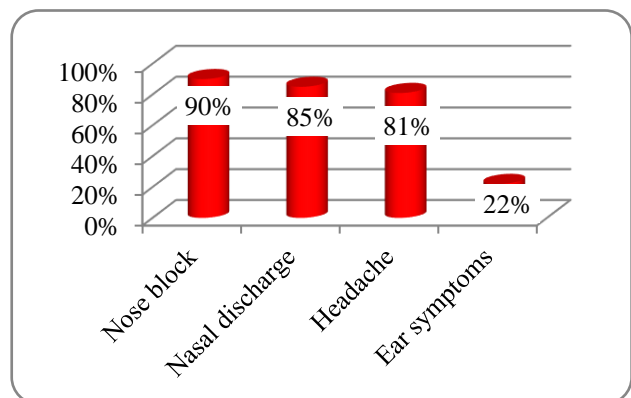


Figure 2: The distribution of symptom (many patients had multiple symptoms).

The presenting symptoms included nasal obstruction, nasal discharge, facial pain or headache, blocking sensation in the ears, tinnitus and ear pain. The symptom

wise distribution is shown in Figure 2. Many patients had multiple symptoms.

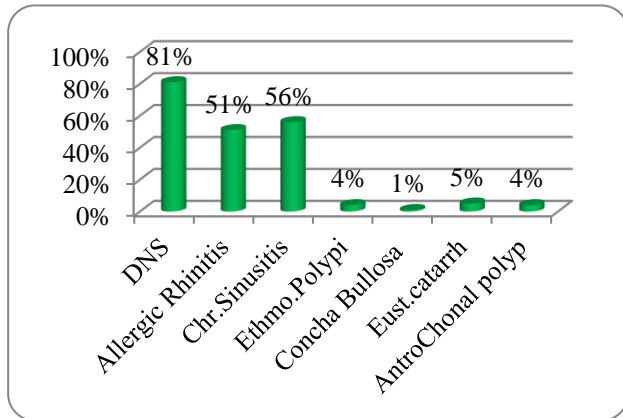


Figure 3: Various diagnoses (many patients had multiple diagnoses).

The distribution of diagnoses was deviated nasal septum 81%, allergic rhinitis 51%, chronic sinusitis 56%, ethmoidal polypi 4%, antrochonal polyp 4%, concha bullosa 1%, and eustachian dysfunction 5% which is shown in Figure 3. Many patients had multiple diagnoses.

In 154 (99.4%) patients, the Gerlach tonsils were not identified during endoscopy. The nasopharynx was normal but for the presence of adenoid remnants (Figure 4).

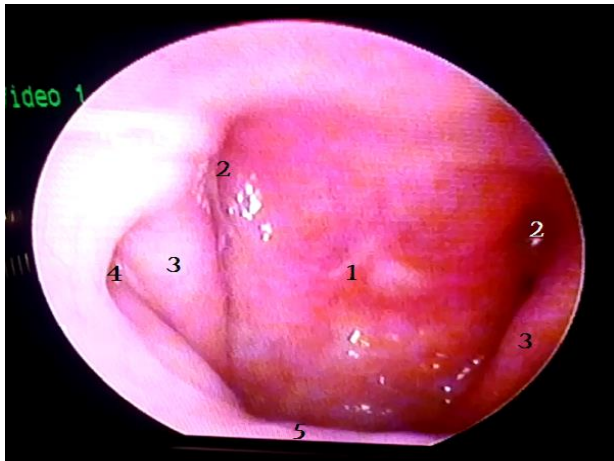


Figure 4: The endoscopic view of the normal nasopharynx.

- 1) Adenoid remnants 2) Fossa of rosenmuller 3) Torus tubaris
- 4) Eustachian tube opening 5) Soft palate.

But in 1 (0.6%) patient who had symptoms of Rt. ear fullness and tinnitus, during endoscopy, the Gerlach tonsil was identified on the Rt. side (Figure 5). The torus tubaris on the Rt. side was bulky with fullness of the fossa of rosenmüller and partial obstruction of the Eustachian opening on the Rt. side. The nasopharyngeal mucosa was intact and normal. Adenoid remnants were

also seen. The Lt. side of the nasopharynx was normal (Figure 6).

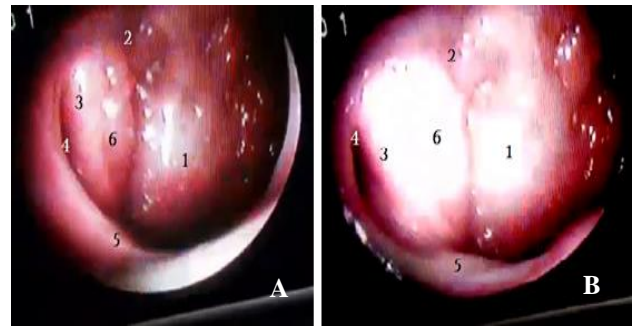


Figure 5: The endoscopic view of the rt. side of the nasopharynx and Gerlach tonsil (A) normal view (B) during swallowing.

- 1) Adenoid remnants 2) Fossa of rosenmuller 3) Torus tubaris
- 4) Eustachian tube opening 5) Soft palate 6) Gerlach tonsil.

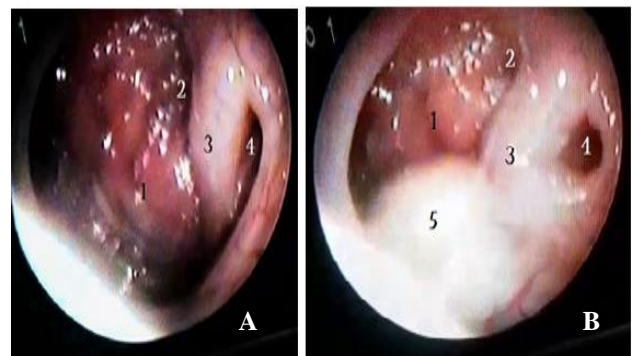


Figure 6: The endoscopic view of the lt. side of nasopharynx (A) normal (B) during swallowing.

- 1) Adenoid remnants 2) Fossa of Rosenmuller 3) Torus Tubaris
- 4) Eustachian tube opening 5) Soft palate

DISCUSSION

Waldeyer's ring is an aggregation of MALT in the nasopharynx and oropharynx. In children, due to an active role in the development of cell mediated and humoral immunity the adenoid and tonsils often hypertrophy, which usually regress during adolescence. Masieri, Simonetta, et al in their study have observed that in children with allergic rhinitis, the hypertrophied adenoids show specific allergen response.⁸

With surgical removal of the adenoids and tonsils at a younger age and with continued exposure to allergens or infections, the remaining MALT aggregates in the Waldeyer's ring go in for a hyperplasia and hypertrophy to take up the role of immune responses.

Depending on the location of such hypertrophy, one might develop conditions such as adenoid recurrence, lingual tonsil hypertrophy (LTH), granular pharyngitis, or Gerlach tonsil hypertrophy (GTH). Such lymphoid hyperplasia is more prevalent in children than adults.

Whereas granular Pharyngitis or LTH is easier to diagnose, due to the lower incidence and hidden location, a GTH is difficult to diagnose on routine clinical examination. Normally the Gerlach tonsils are not visible during routine endoscopic examination.

GTH can cause Eustachian tube dysfunction and affect the middle ear ventilation. Schilder et al in their consensus statement have stated that aural fullness, reduced hearing, tinnitus and otalgia are classical symptoms to diagnose eustachian dysfunction.⁹

In our study, the patient with GTH was a male aged 20 years, had a deviated nasal septum to the Rt. Side also. There was a history of adeno tonsillectomy at the age of 8 and history of allergic rhinitis and post nasal discharge. He had recurrent Rt. ear fullness and tinnitus. X-ray of the para nasal sinuses showed minimal mucosal thickening of Rt. maxillary sinus and the rest of the sinuses were normal. The total IgE level was 1000 IU/ml and absolute eosinophil count was also elevated.

His tympanogram showed type 'C' curve on the Rt. side and type 'A' curve on the Lt. side. pure tone audiogram showed a mild conductive hearing loss on the Rt. side [PTA 25 dB] and Lt. side hearing was normal.

Adeno tonsillectomy during childhood, continued allergen challenge and chronic inflammation probably triggered a GTH in this patient. The location of GTH adjacent to the Eustachian tube opening could have resulted in Eustachian dysfunction, affecting the middle ear ventilation and causing symptoms of ear fullness and tinnitus.

The patient was prescribed 2 weeks course of oral broad-spectrum antibiotics, intranasal steroids and oral antihistamines and advised to undergo an MRI study of the nasopharynx and attend review for Septoplasty, but lost for follow-up.

Nasal endoscopy has been quoted by Emerick et al as a better diagnostic tool than radiology for diagnosing TTH. In their study, they have concluded that TTH can significantly mimic symptoms of adenoid hypertrophy and nasal endoscopy is a better diagnostic tool and suction cautery ablation is an effective treatment for the TTH.¹⁰

Monroy et al in their retrospective study in children posted for revision adenoidectomy have reported that out of 72 cases posted for revision surgery, 15 cases (21%) were found to be having TTH, which was causing the symptoms.¹¹

Honda et al who examined ears of 177 children for recurrence of serous otitis media 1.5-2 years following adenoidectomy reported that out of 177 ears examined, 17% had otitis media with effusion. During endoscopic evaluation of those children, TTH was marked in 51% of

cases and adenoid hypertrophy was seen in 33% of cases. They have further recommended that endoscopic evaluation of nasopharynx is important in such cases.¹²

Hazem et al in their study on TTH and recurrent Otitis media with effusion in children have stated that TTH was seen in 41.7% of their cases and nasal endoscopy is a better diagnostic tool compared to routine radiological evaluation of TTH.¹³

The incidence of TTH after adenoidectomy or adeno tonsillectomy varies. Tubal tonsil hypertrophy is reported to be more prevalent in children than in adults. Most of the published studies were conducted in children, for recurrence of adenoid or serous otitis media after surgery and TTH has been identified as a cause in many cases.

The active immune responses seen in childhood could be a reason for the higher incidence of TTH that has been observed. To our knowledge the incidence of TTH in adults has not been reported so far and in our study, we report an incidence of 0.6%.

Mild cases of Gerlach tonsil hypertrophy can be conservatively managed, by treating the underlying allergy or infection with appropriate antibiotics, intranasal steroids nasal spray and oral antihistamines and regular follow up. Surgical procedures like septoplasty or FESS can also be performed in selected cases.

Studies have suggested the use of CO2 laser, electro cautery or radio frequency surgery for ablation of the more severe cases of TTH. Hong et al have reported a case refractory sleep apnea due TTH, which was treated with radiofrequency ablation.¹⁴

The possibility of a deep thermal injury to the eustachian tube cartilage, subsequent necrosis, fibrosis and scarring, resulting in a permanent blocking of the eustachian tube opening has to be kept in mind while performing any surgical procedures.

CONCLUSION

The possibility of a Gerlach tonsil hypertrophy has to be kept in mind while performing a nasal endoscopy; especially in patients presenting with symptoms of eustachian dysfunction and allergic rhinitis and a past history of Adeno tonsillectomy. Comparing the size of the contra lateral torus tubaris and the eustachian tube opening during the act of swallowing is helpful in diagnosis.

ACKNOWLEDGEMENTS

We wish to thank our Management, Dean, Medical Superintendent, Professor and H.O.D of the ENT department, for their permission and the Medical Records Officer and his staff for their kind cooperation in conducting this study.

Funding: No funding sources

Conflict of interest: None declared

Ethical approval: Not required

REFERENCES

1. Cesta MF. Normal structure, function, and histology of mucosa-associated lymphoid tissue. *Toxicol Pathol.* 2006;34(5):599-608.
2. Dai ZY, Huang DY, Zhou CY. Effects of partial tonsillectomy on the immune functions of children with obstructive sleep apnea-hypopnea syndrome at early stage. *Genet Mol Res* 2014;13:3895-902.
3. Huang SW, Giannoni C. The risk of adenoid hypertrophy in children with allergic rhinitis. *Ann Allergy Asthma Immunol.* 2001;87(4):350-5.
4. Zhang, X, Sun, B, Li, S, Jin, H, Zhong, N, Zeng, G. Local atopy is more relevant than serum sIgE in reflecting allergy in childhood Adeno tonsillar hypertrophy. *Pediatr Allergy Immunol.* 2013;24:422-6.
5. Acar GÖ, Cansz H, Duman C, Öz B, Çiğercioğullar E. Excessive reactive lymphoid hyperplasia in a child with persistent obstructive sleep apnea despite previous tonsillectomy and adenoidectomy. *J Craniofac Surg.* 2011;22(4):1413-5.
6. Çoban K, Köycü A, Aydın E. Lingual Tonsil Hypertrophy in Patients With Allergic Rhinitis. *Am J Rhinol Aller.* 2020; 34(1):87-92.
7. Moneret-Vautrin DA. Le MALT nasal. *Rev Aller Clin Immunol.* 1994;34(2):165-70.
8. Masieri S, Trabattoni D, Incorvaia C, De Luca MC, Dell'Albani I, Leo G, Frati F. A role for Waldeyer's ring in immunological response to allergens. *Curr Medic Res Opin.* 2014;30(2):203-5.
9. Schilder AG, Bhutta MF, Butler CC, Holy C, Levine LH, Kvaerner KJ, et al. Eustachian tube dysfunction: consensus statement on definition, types, clinical presentation and diagnosis. *Clinic Otolaryngol.* 2015;40(5):407.
10. Emerick KS, Cunningham MJ. Tubal tonsil hypertrophy: a cause of recurrent symptoms after adenoidectomy. *Arch Otolaryngol Head Neck Surg.* 2006;132(2):153-6.
11. Monroy A, Behar P, Brodsky L. Revision adenoidectomy--a retrospective study. *Int J Pediatr Otorhinolaryngol.* 2008;72(5):565-70.
12. Honda K, Tanke M, Kumazawa T. Otitis media with effusion and tubal tonsil (video). *Acta Otolaryngologica.* 1988;105(sup454):218-21.
13. Hazem A. Tubal tonsil hypertrophy: a cause of recurrent otitis media with effusion. *Egypt J Otolaryngol.* 2010;26.
14. Hong SC, Min HJ, Kim KS. Refractory sleep apnea caused by tubal tonsillar hypertrophy. *Int J Pediatr Otorhinolaryngol.* 2017;95:84-6.

Cite this article as: Varadharajan R, Thingujam S. Prevalence of gerlach tonsil: a mucosa associated lymphoid tissue aggregation in the nasopharynx. *Int J Otorhinolaryngol Head Neck Surg* 2021;7:39-43.