

Case Series

Isolated middle ear anomalies: unfamiliar causes of conductive hearing loss: a case series

Honnurappa Vijayendra, Somashekhar Abhilasha*, Vinay Vijayendra, Nilesh Mahajan

Department of ENT, Vijaya ENT Care Centre, Super Speciality Otolaryngology Centre, Bangalore, Karnataka, India

Received: 17 October 2020

Revised: 03 December 2020

Accepted: 03 December 2020

*Correspondence:

Dr. Somashekhar Abhilasha,

E-mail: dr.s.abhilasha@gmail.com

Copyright: © the author(s), publisher and licensee Medip Academy. This is an open-access article distributed under the terms of the Creative Commons Attribution Non-Commercial License, which permits unrestricted non-commercial use, distribution, and reproduction in any medium, provided the original work is properly cited.

ABSTRACT

In this paper, we highlighted on the various types of isolated congenital middle ear ossicular anomalies we had seen and managed. This is significant as these are rare and go undiagnosed for long period of time. The mainstay of managing these conditions includes proper and timely diagnosis and correction of conducting hearing loss. This was a retrospective case series study done over period of 3 years from July 2016 to June 2019 at a tertiary referral otology centre. The study comprised of 9 patients diagnosed with isolated middle ear anomalies and in total 11 operated ears for the same as two patients underwent bilateral treatment. Each case was handled differently according to the intra operative middle ear findings. We found that in all of our cases the HRCT findings were in correlation with our intra operative findings. All cases had excellent post-operative hearing outcomes. Isolated middle ear deformity even though rare to identify, with recent advancement it is possible to diagnose and treat it on time and hence reduce the disability experienced by the patient. Whatever the type of abnormalities, most of them could be corrected with appropriate ossicular reconstruction by preserving the normal existing anatomy and bypassing the anomalous part.

Keywords: Isolated middle ear deformity, Congenital middle ear anomalies, Ossicular reconstruction, Development of middle ear ossicles

INTRODUCTION

The conductive hearing loss in paediatric group is most commonly caused by acquired causes like acute otitis media, otitis media with effusion and chronic otitis media.¹ However some cases turn out to be congenital in nature which is rare and their diagnosis is invariably delayed until their adulthood especially when they are unilateral in presentation. These congenital middle ear anomalies could be a part of syndromic presentation or can occur individually.² Overall, 50% of the malformation noticed in Otorhinolaryngology affects the ear ranging 1 per 15000 new-born. Isolated congenital middle ear malformations accounts for even lesser prevalence.³

Broadly the congenital anomalies of middle ear are classified into major and minor. They are considered to be major when they involve tympanic membrane or /and external auditory canal or else as minor. This presentation even though is rare, is possible due to the fact that they have different embryological origin.^{2,4,5}

Many authors have tried to classify these anomalies in order to determine the prediction of disease progression and for its surgical management. Teunissen and Cremers in 1993 divided the minor ear anomalies into four groups and further subgroups.⁶ Funasaka et al proposed formal classification system to cases of isolated ossicular abnormality. The ossicular anomalies can be accompanied by non ossicular ear deformities like an

anomalous course of facial nerve, persistence of stapedia artery, high jugular bulb, aberrant internal carotid artery, absence of round window or oval window.⁷

One quarter of these congenital ear anomalies are associated with syndromic presentations such as branchio-oto-renal (BOR) syndrome, Crouzon syndrome, Klippel-Feil syndrome, Pfeiffer syndrome, osteogenesis imperfect or Treacher Collins syndrome.^{2,8}

On other hand, in non-syndromic cases the clinical history plays an important role to diagnose them. They mainly present with conducting hearing loss with no history of trauma or infection with intact tympanic membrane. The tympanometry and pure tone audiometry are particularly useful as they present with normal pressure with a possible reduced compliance due to ossicular abnormalities.^{2,4,5,9}

The mainstay of managing these conditions includes proper and timely diagnosis and correction of conducting hearing loss either by hearing aids or by surgical intervention depending on the scenario.²

This study is a case series of such different scenarios and their managements and outcomes.

CASE SERIES

This was a retrospective study done over period of 3 years from July 2016 to June 2019 at a tertiary referral otology centre. The study comprised of 9 patients diagnosed with isolated middle ear anomalies (11 operated as 2 were bilateral). All the cases discussed below had come to our centre with complaints of difficulty hearing since childhood and had no other symptoms. They were examined in OPD, where they were found to have normal external ear without any obvious deformities. They were subjected to audiological evaluation [pure tone audiometry (PTA) and tympanometry] to know the type and degree of hearing loss. High-resolution CT (HRCT) scan of temporal bone was done.

Patients were prepared for exploratory tympanotomy. Each case was handled differently according to the intra operative middle ear findings. They were subjected to audiological evaluation post operatively to know the improvement. We found that in all our cases the HRCT findings were in correlation with our intra operative findings.

Cases involving all 3 ossicles of middle ear

Case 1 and 2

16 years old female presented with bilateral hard of hearing. On examination bilateral tympanic membrane was intact with myringosclerotic patches and absent head of malleus. Her Pre op PTA showed bilateral moderate

mixed hearing loss (R: 53.3 dB HL; L: 45 dB HL). Her HRCT showed identical anomalies in bilateral ear with dysplastic stapes, abnormally long handle of malleus and hypoplastic incus (Figure 1(A)). On right exploratory tympanotomy following findings were noted (Figure 2 (A) and (B)).

Malleus: Absence of head with abnormally long handle
Incus: Abnormal with thin long process
Stapes: Large stapes head with small crura with normal footplate.

Stapedial reflex was seen with normal round window reflex. IS joint was disarticulated carefully, adhesions around the stapes was cleared and dehiscent horizontal part of facial nerve was noted. There was a defect in attic due to hypoplastic incus and hence the defect was obliterated with auto conchal cartilage. Septal spur cartilage was sculptured to engage the large head of stapes and stapedial tendon. Myringostapedopexy was done. On left exploratory tympanotomy same findings were noted, hence the same procedure was done. Her post operative audiometry showed an good hearing improvement of R: 20 dB HL; L:21 dB HL (Table 1).

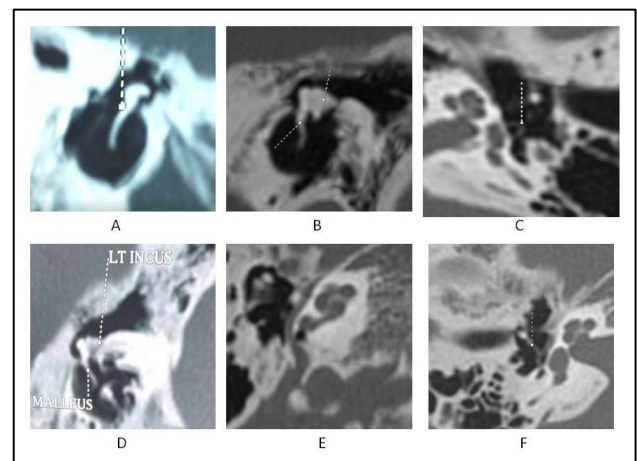


Figure 1: HRCT images of various cases with middle ear ossicular anomalies. (A) Case 1 showing abnormally long handle of malleus on right side; (B) and (C) case 7 showing right normal malleus, stapes crura with absent long process of incus and stapes head; (D) case 10 showing left abnormally large incus with widened long process and fixed with facial canal; (E) and (F) case 11 showing right abnormal course of facial nerve with wide vestibule and part of footplate hanging with rest of ossicular chain.

Case 3 and 4

15yrs old female patient with bilateral hard of hearing and had intact looking tympanic membrane on both the sides with altered regular landmarks over it. Her pre operative PTA showed R: 65 DB HL moderately severe mixed hearing loss; L: 81 DB HL severe mixed hearing loss. HRCT revealed abnormally long handle of malleus

with hypoplastic head, dysplastic incus and abnormal stapes suprastructure. On right exploratory tympanotomy following findings were noted (Figure 2(C) and (D)).

Malleus: Abnormally long handle with hypoplastic head.
Incus: Abnormal hypoplastic.
Stapes: abnormal suprastructure attached to dehiscence facial canal.

Table 1: Intra-operative findings, the procedure pre operative and post operative audiological assessment of the cases.

Case no.	Side	Malleus	Incus	Stapes	Facial nerve	Procedure	Pre op PTA	Post op PTA
1	Right	Absence of head with abnormally long handle	Abnormal with thin long process	Large stapes head with small crura and normal footplate	Dehiscent horizontal segment	Right myringostapedopexy	53.3	20
2	Left	Absence of head with abnormally long handle	Abnormal with thin long process	Large stapes head with small crura and normal footplate	Dehiscent horizontal segment	Left myringostapedopexy	45	21
3	Right	Hypoplastic head with Abnormal with long handle	Abnormal hypoplastic	Abnormal supra structure	Dehiscent horizontal segment	Right myringoplatinopexy	65	26
4	Left	Hypoplastic head with Abnormal with long handle	Abnormal hypoplastic	Abnormal supra structure	Dehiscent horizontal segment	myringo-cruro-platinopexy	81	40
5	Left	Normal	Abnormal long process	Abnormal stapes suprastructure	Normal	Left myringostapedopexy	48	31
6	Left	Normal	Absent long process	Absent stapes head Arched crura Stapedial tendon present	Normal	Left myringocruroplexy	83	30
7	Left	Normal	Absent long process	Absent crura with normal stapedial tendon	Normal	Left myringoplatinopexy	71	21.6
8	Right	Normal	Absent long process	Absent stapes head and stapedial tendon, crura present	Normal	Right myringoplatinopexy	76.6	30
9	Left	Normal	Absent long process	Absent suprastructure	Normal	Left myringoplatinopexy	61.6	20
10	Left	Normal	Abnormal incus fixed to facial canal	Normal	Normal	Left myringostapedopexy	63.3	25
11	Right	Normal	Normal	Abnormal suprastructure.	Anomalous covering the round window	abandoned	70	-

Horizontal part of facial nerve was dehiscent with large blood vessel running over it. Footplate was mobile and hence dysplastic suprastructure bypassed and myringoplastinoplexy done. Left exploratory tympanotomy was performed and same ossicular findings were noted. Footplate was mobile and myringo-cruro-platinoplexy was done. Her post-operative PTA showed bilateral good hearing improvement of 26.6 dB HL in right ear and 40 dB HL in left ear (Table 1).

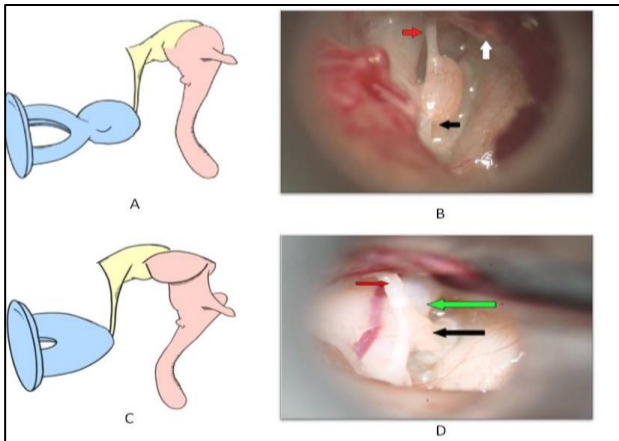


Figure 2: Schematic and intra operative findings of cases involving all 3 ossicles of middle ear. (A) Right ossicular pathology of case 1. (B) Intra operative findings of case 1. (C) Right ossicular pathology of case 3. (D) Intra operative findings of case 3. Abnormal hypoplastic incus (Red arrow); abnormal stapes suprastructure (Black arrow); Malleus lifted along with the TM flap (White arrow); Dehiscent facial nerve (Green arrow).

Cases involving 2 ossicles of the middle ear

Case 5

17yrs old female patient with bilateral hard of hearing and had normal looking tympanic membrane. Her pre-operative PTA showed R:75 dB HL, severe mixed hearing loss; L:48 dB HL, Moderate mixed hearing loss. Her HRCT showed inner ear anomaly on right side. On left side it showed thinned out long process of incus and dysplastic stapes. Due to inner ear malformation on right side it was decided to do the exploratory tympanotomy only of left side and following findings were noted.

Malleus: Normal

Incus: Abnormal long process

Stapes: Abnormal stapes suprastructure.

Normal round window reflex was seen. IS joint was disarticulated as it was noted that thinned out long process of incus was still in contact with the dysplastic stapes. Septal spur cartilage was sculptured to fit the stapes suprastructure and Myringostapedopexy was

done. Her post operative PTA showed very good hearing improvement of 31 dB HL (Table 1).

Case 6

21 years old female with complaints of left sided hard of hearing. Tympanic membrane was intact. Her Pre op PTA showed R:66 dB HL, moderately severe mixed hearing loss; L:83 dB HL, severe mixed hearing loss and Tympanogram showed B/L Ad curve. HRCT findings revealed normal malleus with absent of long process of incus and stapes head. However stapes crura were seen. On left exploratory tympanotomy following findings were noted (Figure 3(A) and (B)).

Malleus: Normal

Incus: Absent long process

Stapes: Absent stapes head with Arched crura, Stapedial tendon present.

Malleus was freely mobile, foot plate was normal and round window reflex was elicited. The septal spur cartilage was sculptured to fit into the arched crura and stapedial tendon. Myringocruroplexy done. Her post operative PTA showed good hearing improvement of 30 dB HL (Table 1).

Case 7

35 years old male patient with left side hard of hearing and had normal looking tympanic membrane. His pre-operative PTA showed R:10 DB HL, Normal; L:71 DB HL, severe mixed hearing loss. His HRCT revealed absence of long process of incus and stapes crura (Figure 1(B) and (C)). On left exploratory tympanotomy following findings were noted (Figure 3(C) and (D)).

Malleus: Normal

Incus: Absent long process

Stapes: Absent crura with normal head, Stapedial tendon and foot plate.

Malleus was freely mobile, foot plate was normal and round window reflex was elicited. Stapedial tendon was cut and stapes head removed. Septal Spur cartilage was sculptured and myringoplastinoplexy was done. His post-operative PTA was seen to be 21.1 dB HL (Table 1).

Case 8

35 years old female patient with bilateral hard of hearing and had normal looking tympanic membrane. Her pre-operative PTA showed R:76.6 dB HL severe mixed hearing loss; L:40 DB HL, mild SNHL. HRCT showed right sided absent long process of incus and stapes head, stapes crura were present. On right exploratory tympanotomy following findings were noted (Figure 3 (E) and (F)).

Malleus: Normal

Incus: Absent long process.

Stapes: Absent stapes head, neck and stapedia tendon, crura were present.

Malleus was freely mobile, foot plate was normal and round window reflex was elicited. Septal spur cartilage was sculptured and myringoplasty was done. Her postoperative PTA was showed very good hearing improvement of 30 dB HL (Table 1).

Case 9

27 years old female patient with bilateral hard of hearing and had intact looking tympanic membrane. Her pre-operative PTA showed R: R: 51.6 DB HL, mod mixed HL; L:61.6 DB HL, mod to severe mixed hearing loss. HRCT revealed absent long process of incus and absent stapes suprastructure on left side. On left exploratory tympanotomy following findings were noted (Figure 3 (G) and (H)).

Malleus: Normal

Incus: Absent long process

Stapes: Absent suprastructure.

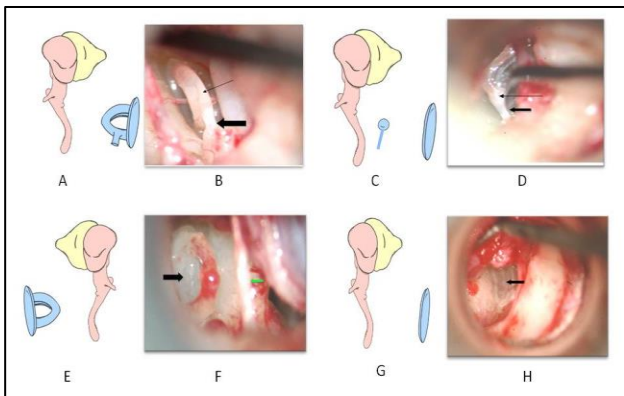


Figure 3: Schematic and intra operative findings of cases with incudostapedial involvement with normal malleus. (A) Left ossicular pathology of case 6; (B) Intra operative findings of case 6 left ear showing stapedial tendon (Thick black arrow); arched crura (thin black arrow);(C) left ossicular pathology of case 7;(D) Intra operative findings of Case 7 showing stapedial tendon (Thick black arrow); stapes head (thin black arrow); note the absence of long process of incus and absence of crura; (E) Right ossicular pathology of case 8;(F) Intra operative findings of Case 8 showing stapes crura with footplate (Thick black arrow). Note the absence of stapes head, neck and stapedia tendon ; chorda tympani nerve (Green arrow);(G)Left ossicular pathology of case 9;(H) Intra operative findings of Case 9 showing foot plate area (black arrow). Note the absence of stapes suprastructure and long process of incus.

Malleus was freely mobile, foot plate was normal and round window reflex was elicited. Septal spur cartilage was sculptured and myringoplasty was done. Her post-operative PTA was seen to be 20 dB HL (Table 1).

Cases involving only one ossicle of middle ear:

Case 10

19 years old male patient with left sided hard of hearing had normal looking tympanic membrane. His pre-operative PTA showed R:18.3dB HL; L:63.3 dB HL mod to severe mixed hearing loss. His HRCT revealed abnormally large incus with widened long process and was fixed with facial canal (Figure 1(D)). On left exploratory tympanotomy following findings were noted (Figure 4 (A) and (B)).

Malleus: Normal

Incus: Abnormal incus fixed to facial canal

Stapes: normal.

Malleus was freely mobile, foot plate was normal and round window reflex was elicited. IS joint was dislocated and abnormal incus was carefully drilled to create space for reconstruction and myringostapedotomy done using spur cartilage. His post-operative PTA was seen to be 25 dB HL (Table 1).

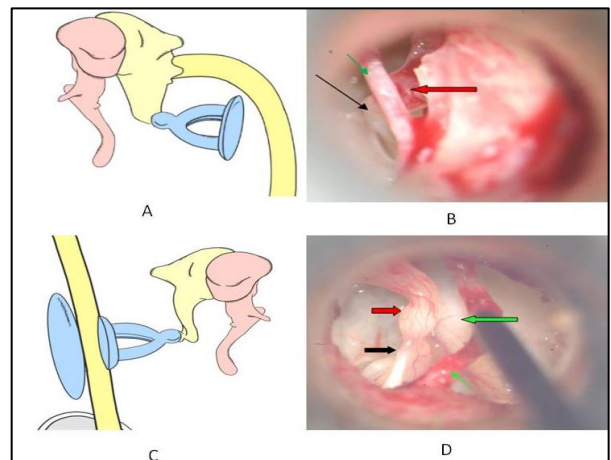


Figure 4: Schematic and intra operative findings of cases involving only one ossicle of middle ear. (A) Left ossicular pathology of case 10; (B) Intra operative findings of Case 10 showing IS joint (black arrow); chorda tympani nerve (Green arrow) and incus (red arrow); (C) Right ossicular pathology of case 11; (D): Intra operative findings of Case 11 showing abnormal stapes suprastructure (black arrow); incus (red arrow);; chorda tympani nerve (thin Green arrow); anomalous facial nerve (thick green arrow).

Case 11

20 years old male patient with right sided hard of hearing had normal looking tympanic membrane. His pre

operative PTA showed R:70 db hl; L:10dB HL mod to severe mixed hearing loss. HRCT showed abnormal course of Facial Nerve with wide vestibule and part of footplate hanging with rest of ossicular chain (Figure 1(E) and (F)).

Right sided exploratory tympanotomy was done (Figure 4 (C) and (D)). Malleus and incus was normal. Stapes had abnormal suprastructure. Here stapes footplate dual origin was seen clearly as the part which arises from 2nd arch was hanging separately along with rest of the ossicular chain and the part of footplate which was derived from otic capsule was seen to be very wide and thick. Due to anomaly of otic capsule, the procedure was abandoned.

DISCUSSION

Isolated middle ear deformity had been considered as a rare identity as many failed to diagnose them. However recently they are coming into limelight due to usage of HRCT and increased number of exploratory tympanotomy done for cases who presents with conductive hearing loss. Henner and Buckingham classified the congenital ossicular anomalies for the very first time in 1956 as two types. Isolated type which was further subdivided into 8 subtypes and combined type which was associated with other anomalies.¹⁰ House also classified it into 5 types and Funasaka into 3 types cases which were type I (malleus or incus fixation), type II (incudo stapedia disconnection), and type III (stapes fixation). The above-mentioned presentations can be accompanied by non ossicular ear deformities like an anomalous course of facial nerve, persistence of stapedia artery, high jugular bulb and aberrant internal carotid artery, absence of round window or oval window.⁷

However the most widely used classification is by Teunissen and Cremers were they analysed 144 cases of congenital ear abnormalities which presented with conductive hearing loss.⁶ Our results reveal that all 9 cases presented to us with conductive hearing loss with no prior history of infection or trauma. Swartz JD in their study which included 21 patients with congenital deformities found isolated ossicular deformity in 8 who were adults with same presenting features as in our study.¹¹

Kojima et al showed predominantly the incudostapedial anomaly which was in concurrence with our findings.¹² The incudostapedial anomaly would be expected to occur owing to the fact that the embryological origin of long process of the incus, lenticular process and the stapes suprastructure is from second brachial arch.¹² Kuhn et al mentioned that around 1/3rd of cases will have stapes anomalies in association with long process of incus deformity.¹³

Swartz et al found most common ossicle to be involved in isolated congenital ossicular deformity to be stapes.¹¹ In

our study only 1 case had normal stapes and rest all presented with one or other type of deformities like, large head with small crura, absent or arched crura, absent head, over all abnormal suprastructure and in one case absent suprastructure of stapes was seen. The basis for abnormal stapes suprastructure may be due to its developmental relation with stapedia artery. During the embryogenesis of stapes, it forms a ring around the stapedia artery; which once the artery disappears gives its characteristic appearance of stirrup. Failure of stapedia artery formation or abnormality can explain these presentations. Park et al agrees with Tuenissen et al for poor audiological outcome in cases with stapes superstructure anomaly, which we contradict as all our cases had good hearing outcomes post operatively.⁹ However due to less sample size, further studies with more number of cases can prove our results definitively.

Current study found incus to be involved in all the cases with either abnormal long process or absent of long process. Four cases presented with absent of long process of incus and four had abnormal long process of incus and in one case it was ankylosing with facial canal in which malleus and stapes were normal in their anatomy. Swartz et al also found similar findings where the long process of incus was either hypoplasia or absent or attic fixation of incus.¹¹ Their study also claimed the least involved ossicle was malleus. Park et al also found fewer malleolar anomalies as they explained that upper ossicular chain is in close relation to first arch and the other half with second arch and hence marked stapedia anomalies was seen in conjunction with lower half of ossicular chain.⁴ These results are in consistent with our findings too. Bartell et al also mentioned that malleus tend to have less involvement with either as deformed or hypoplasia of head and the manubrium, fixation to epitympanum or might even be absent.³ In our study only 2 cases which were both bilateral had malleus deformities, where one had absent head with abnormal handle of malleus and other had hypoplastic head of malleus with long handle of malleus.

Bartell et al found that the most common findings of aberrant facial nerve to be dehiscence of inferior displacement of horizontal part of facial nerve and in few, it was coursing across middle portion of promontory inferior to oval window.³ We saw one case was anomalous facial nerve covering the round window and 2 cases both bilateral in presentation to have dehiscence of horizontal part of facial nerve.

All the cases except one, had mobile footplate of stapes without any deformity. This can be explained by the origin of stapes. It has dual origin where the head, crura and tympanic surface of footplate takes origin from 2nd arch where as the medial and annular ligament from otic capsule. These two develop independent of one another which later fuses at around 11th to 12th week of gestation. In one case, a part of stapes footplate which seems to have derived from otic capsule was seen to be

very wide and fixed. This was not in contact with the other part of the footplate which would have derived from 2nd arch and this was hanging along with abnormal stapes superstructure. Facial nerve also have same origin as that of stapes; otic capsule and 2nd arch and also its bony canal has its origin fully or partly from 2nd arch. Thus any malformation in 2nd arch development results in anomalous facial nerve and facial nerve canal.^{3,11,13-15}

All these presentations have to be timely diagnosed as the hearing can be restored in majority of the cases. Abnormality of malleus on otoscopic examination in such cases gives clue for the presence of other ossicular anomalies. Meticulous examination of ear and other systems to rule out co existing syndromes is of much importance. Audiological evaluations help in the process and image modalities like HRCT plays very important tool to guide a surgeon and prepare accordingly. All our cases had undergone HRCT temporal bone and their findings are in consistence with that seen intra operatively. Whatever the type of abnormalities, most of them could be corrected with appropriate ossicular reconstruction. Even though various methods are present it depends on surgeon's choice and preferences. At our centre we believe in our time tested ossicular reconstruction with septal spur cartilage keeping in mind to preserve the normal existing anatomy and to bypass the anomalous part.

CONCLUSION

Isolated middle ear deformity had been considered as a rare identity as many failed to diagnose them, with recent advancement it is possible to diagnose and treat it on time and hence reduce the disability experienced by the patient. In this study we could also appreciate the various isolated middle ear anomalies seen in co-ordination with their embryological development. Whatever the type of abnormalities, most of them could be corrected with appropriate ossicular reconstruction by preserving the normal existing anatomy and bypassing the anomalous part.

Funding: No funding sources

Conflict of interest: None declared

Ethical approval: Not required

REFERENCES

1. Zeifer B, Sabini P, Sonne J. Congenital absence of the oval window: radiologic diagnosis and associated anomalies. *Am J Neuroradiol.* 2000;21(2):322-7.
2. Esteves SD, Silva AP, Coutinho MB, Abrunhosa JM. Congenital defects of the middle ear-uncommon cause of pediatric hearing loss. *Brazilian J Otorhinolaryngology.* 2014;80(3):251-6.
3. Friedrich BS, Wulke C. Classification and diagnosis of ear malformations. *Otorhinolaryngology Head Neck Surg.* 2007;6:43-9.
4. Park K, Choung YH. Isolated congenital ossicular anomalies. *Acta Otolaryngologica.* 2009;129(4):419-22.
5. Rahbar R, Neault MW, Kenna MA. Congenital absence of the incus bilaterally without other otologic anomalies: a new case report. *Ear Nose Throat J.* 2002;81(4):274-8.
6. Teunissen E. Major and minor congenital anomalies of the ear: classification and surgical results. [SI: sn]; 1992.
7. Funasaka S, Abe H, Tozuk G, Tokumasu K. Anomalies of the ossicles without malformation of the external ear. *Otologia.* 1997;17:250-7.
8. Thomeer HG, Kunst HP, Cremers CW. Congenital ossicular chain anomalies associated with a mobile stapes footplate: surgical results for 23 ears. *Ann Otol Rhinol Laryngol.* 2012;121:275-81.
9. Park HY, Han DH, Lee JB, Han NS, Choung YH, Park K. Congenital stapes anomalies with normal eardrum. *Clin Experiment Otorhinolaryngology.* 2009;2(1):33.
10. Henner R, Buckingham RA. The recognition and surgical treatment of congenital ossicular defects. *Laryngoscope.* 1956;66:526-39.
11. Swartz JD, Faerber EN. Congenital malformations of the external and middle ear: high-resolution CT findings of surgical import. *Am J Roentgenol.* 1985;144(3):501-6.
12. Kojima H, Miyazaki H, Tanaka Y, Moriyama H. 72 cases of the auditory ossicle malformations but with normal findings in the tympanic membrane. *Nippon Jibiinkoka Kaiho.* 1998;101:1373-9.
13. Kuhn JJ, Lassen LF. Congenital incudostapedial anomalies in adult stapes surgery: a case-series review. *Am J Otolaryngology.* 2011;32(6):477-84.
14. Amarnath C, Sathyan G, Soniya R, Periakaruppan AL, Shankar KS. Evaluation of embryological sequences of ear anomalies and its radiological relevance. *Indian J Otol.* 2016;22(4):248.
15. Rodriguez K, Shah RK, Kenna M. Anomalies of the middle and inner ear. *Otolaryngol Clin North Am.* 2007;40(1):81-96.

Cite this article as: Vijayendra H, Abhilasha S, Vijayendra V, Mahajan N. Isolated middle ear anomalies: unfamiliar causes of conductive hearing loss: a case series. *Int J Otorhinolaryngol Head Neck Surg* 2021;7:130-6.