

Case Report

Lemierre's disease: a typical presentation in two diabetic patients

Bushra Hamdan Al Kalbani, Amar Singh*, Salma Mohd Al Sheibani

Department of ENT Head and Neck Surgery, Al Nahdha Hospital, Muscat, Oman

Received: 11 October 2020

Accepted: 26 October 2020

***Correspondence:**

Dr. Amar Singh,

E-mail: amar1953@gmail.com

Copyright: © the author(s), publisher and licensee Medip Academy. This is an open-access article distributed under the terms of the Creative Commons Attribution Non-Commercial License, which permits unrestricted non-commercial use, distribution, and reproduction in any medium, provided the original work is properly cited.

ABSTRACT

Lemierre disease (LD) is a rare but potentially life-threatening condition, characterized internal jugular vein suppurative thrombophlebitis and disseminated septic emboli following a recent oropharyngeal infection. It is seen commonly in healthy young adolescents or adults, caused by gram negative anaerobic *Fusiform necropharum*. Lack of awareness of this condition delays treatment and worsens prognosis. We present two interesting cases of LD in diabetic patients, caused by *Klebsiella pneumonia* and *Haemophilus influenza* organisms at our hospital. Both patients had atypical presentations. Diagnosis of such atypical cases poses diagnostic and therapeutic challenges.

Keywords: LD, IJV thrombosis, Clivus osteomyelitis, Hyperbaric oxygen therapy

INTRODUCTION

Lemierre disease (LD) or postanginal syndrome, was initially reported by Courmont and Cade in 1900 and best described by French microbiologist Andre Lemierre in 1936, hence the name.^{1,2} Typically, the disease is of young immunocompetent persons in the age group 15-25 years. The condition carried high morbidity and mortality due to metastatic systemic infection, lung being the most typical site. With introduction of antibiotics, the overall mortality has decreased to less than 2%.^{1,3} In recent times many cases of LD have been reported in the middle aged and elderly group of patients.⁴⁻⁶

The possible causes include increase in comorbidities such as diabetes, use of immunosuppressive drugs and prevalence of drug resistance bacteria.⁷

In this article, we present two such interesting cases of LD in diabetic patients with atypical presentations with a review of the literature. In one such case, clivus involvement with lower cranial nerve paralysis and mass nasopharynx mimicked nasopharyngeal malignancy.

Clival osteomyelitis has rarely been reported in the LD. The delayed presentation posed a diagnostic and therapeutic challenge.

CASE REPORT

Case 1

A 64-year-old male diabetic (type II NIDDM), and hypertensive presented to the ENT outpatient clinic with gradually increasing history of throat pain, fever, odynophagia and right otalgia of two weeks duration. He had no past history of recurrent sore throat. On clinical examination, he looked dehydrated, febrile; (38.50 °C), blood pressure of 160/90 and pulse rate of 80/minute. On examination, he had mild trismus, right tonsil congested and pushed medially with supratonsillar bulge. He was diagnosed as right peritonsillar abscess. Neck examination revealed small tender jugulodigastric lymph node on right side (level II). Ear examination revealed normal ear canal and tympanic membrane. Rest of examination was normal. His random blood sugar (RBS) recorded as 17.2 mmol/L. Incision and drainage of

abscess was performed and pus swab sent for culture and sensitivity. He was treated with IV fluids, intravenous amoxiclav 1.2 gm thrice daily, analgesics and chlorhexidine mouth gargle. Blood sugar controlled with insulin injection-isophane (N)-30 IU split doses to control his blood sugar. He was started on antihypertensive medication lisinopril 10 mg OD. Blood investigations revealed leukocytosis WBC 17,900 cells/ μ L (4-11), Hb-11.9 g/L, with neutrophil-83%, lymphocytes-12%, monocytes-2% and atypical lymphocytes 3%. Peripheral smear showed neutrophilic leukocytosis with leukocytes showing toxic granulations. Renal function showed Na-138.8 mmol/L (137-148), K-4.49 mmol/L (3.6-5), chloride-97.3 (101-111), urea 8.5 mmol/L (2.5-7.5) and serum creatinine 70.28 μ mol/L (60-120). Urine examination was negative for ketone bodies, hemoglobin A1C-9.8 reflecting poor glycemic control. Pus culture sensitivity revealed moderate growth of *Klebsiella pneumoniae* sensitive to gentamycin, amoxiclav, cephradine, ceftazidime.

He showed progressive clinical improvement in next 24-48 hours with the resolution of trismus and local findings. He was continued on intravenous amoxiclav for 5 days and discharged on oral amoxiclav for next seven days. He had complete resolution of signs and symptoms with no fever, neck pain/swelling. He was further advised further follow up with his primary care physician for diabetic management.

Two months later he was again referred for right otalgia, headache, pain right upper neck and tinnitus, heaviness in tongue and difficulty in swallowing liquids for 1 month. There was no history of fever, neck trauma, aspiration or symptoms suggestive of cerebrovascular accident. On clinical examination, he was conscious, fully oriented. Local ENT examination revealed tongue deviated to the right side (right XII paresis), absent gag reflex and absent right palatal movement (IX nerve involvement). Both tonsils looked healthy. Flexible fiberoptic examination revealed a bulge in the posterior wall of right-side nasopharynx with fullness and obliteration of right fossa of Rosenmuller. The nasopharyngeal mucosa looked intact with no ulcerative lesion. Clinically a suspicion of nasopharyngeal malignancy was made. Both true vocal folds were mobile and normal with no pooling of secretions in both pyriform fossae. Left ear examination was the normal. Right ear examination revealed wide canal, dull tympanic membrane which was suggestive of otitis media with effusion. Neck examination revealed generalized fullness and tenderness in right side level II and III with no definite lump palpable. Rest of cranial nerves were intact and normal.

He was initially suspected to have nasopharyngeal malignancy. High resolution CT scan (HTCT) of nasopharynx and neck revealed thrombosis of right internal jugular vein (IJV) and asymmetrical bulge in right nasopharynx with obliteration of fossa of Rosenmuller.

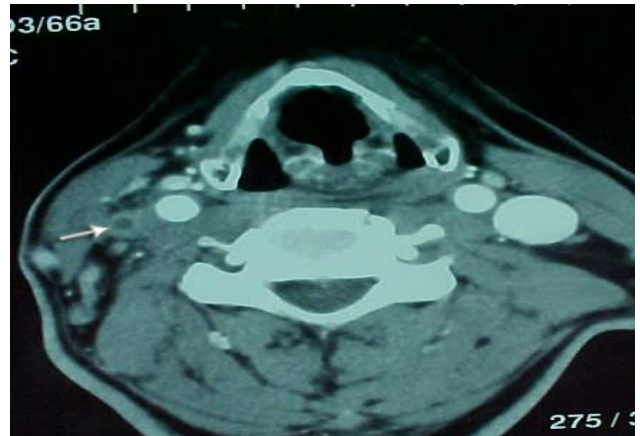


Figure 1: Intraluminal filling defect with surrounding enhancement indicating thrombophlebitis of right IJV and dilated IJV on contralateral side.

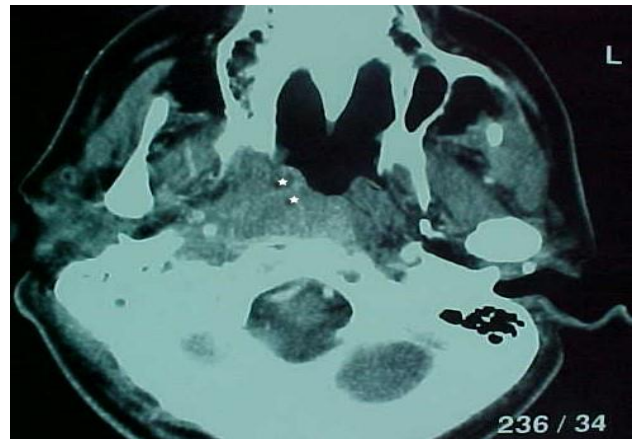


Figure 2: Obliteration of right-side fossa of Rosenmuller and smooth asymmetrical bulge right side nasopharynx with increased prevertebral soft tissue infiltration due to inflammatory pathology.

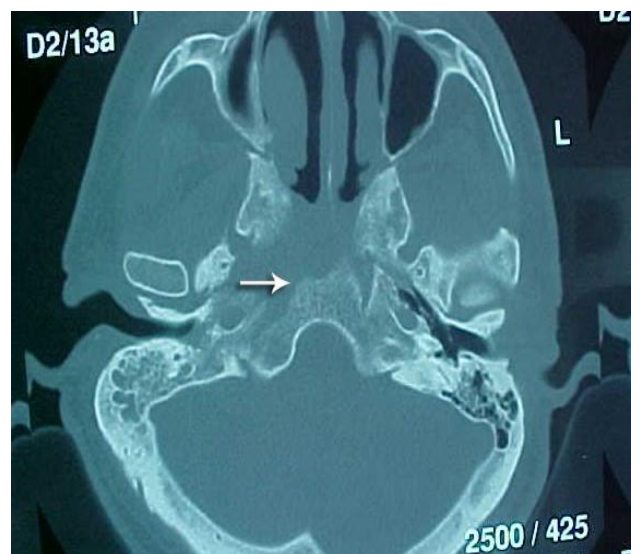

Figure 3: Erosion of clivus on right side.

There was evidence of significant erosion of right side clivus with increased prevertebral soft tissue edema (Figure 3).

No cervical lymphadenopathy. MRI reported high signal intensity in T2W1 flair in right mastoid air cells (fluid) with obliteration of right fossa of Rosenmuller and right internal IJV, right parapharyngeal space and erosion of right side clivus. He underwent EUA of nasopharynx, biopsy and myringotomy grommet insertion right ear under general anesthesia. Histopathological examination of nasopharyngeal tissue revealed inflammatory tissue with no evidence of malignancy. ESR (112 mm/hr) and C-reactive protein (68 mg/L) were raised. Bone scan (Tc99 scintigraphy) and Gallium 67 scintigraphy also showed increased radiotracer uptake in right temporal bone. X-ray chest was normal. These findings confirmed the diagnosis of right skull base-clivus osteomyelitis with IX and XII cranial nerve involvement.

He was treated with triple antibiotics intravenously; ceftazidime (1 gm twice daily (33days) amikacin 500 mg twice daily (25 days) and tazocin (piperacillin and tazobactam) 4.5 gm thrice daily (33 days) and control of blood sugar with insulin. He was regularly monitored for nephrotoxicity and ototoxicity. Amikacin trough and peak serum level were also measured periodically. He was also treated with 24 sessions of hyperbaric oxygen therapy (HBOT).

He was discharged after 33 days of antimicrobial therapy and placed on oral ciprofloxacin 750 mg BID for next 12 weeks. At three month and one-year follow-up, he showed complete recovery of IX and XII cranial nerve paralysis. Gallium 67 scintigraphy was normal. Inflammatory markers, ESR reduced serially from 122, 118, 70, 49 to 16 mm/hr and CRP value from 68 mg/L to 2 mg/L.

Case 2

A 68 years old retired gentleman, diabetic and hypertensive on medications, was referred to ENT clinic from the emergency department with a history of headache, neck pain and fever for more than one-week duration. One day later, he complained of left-sided upper neck pain with no restriction of movements. The headache started over both temporal regions, more on the left side, severe and associated with nausea. He had no history of head injury or convulsions. No photophobia, phonophobia, or alteration of mental status, or vision abnormalities was recorded.

The patient also gave history of sore throat and runny nose two weeks before the present complaints which had resolved.

On examination, he was febrile (38°C), conscious and alert. Vitals were normal. The pharynx was mildly congested with neck tenderness over the left upper neck

side behind angle of the mandible. There was no neck swelling.

Nasal endoscopy and fibro-optic laryngoscopy showed normal nasal mucosa with no discharge but congested pharyngeal mucosa. Blood count showed marked leukocytosis-WBC count of 21, 100 cells/ μ L (neutrophils of 19,100 cells/ μ L), C-reactive protein of 234 mg/L, and normal electrolytes. Chest X-ray was normal. Computed tomography (CT) brain and sinus revealed no evidence of intracranial pathology but reported incidental finding of opacification of right maxillary sinus with hyperdense shadow suggestive of fungal ball. The rest of sinuses were normal.

He was started on intravenous ceftriaxone for two days. With no significant improvement in headache and neck pain, subsequent CT neck with contrast revealed extensive thrombosis of left IJV, jugular bulb and sigmoid sinus, along with bilateral lymphadenopathy (Figure 4 and 5).

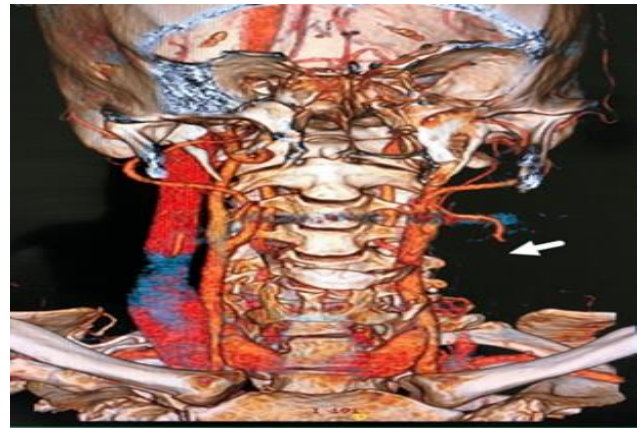


Figure 4: CT neck angiography with 3D reconstructed coronal image; arrow demonstrating extensive thrombosis of IJV, jugular bulb and sigmoid sinus on left side.

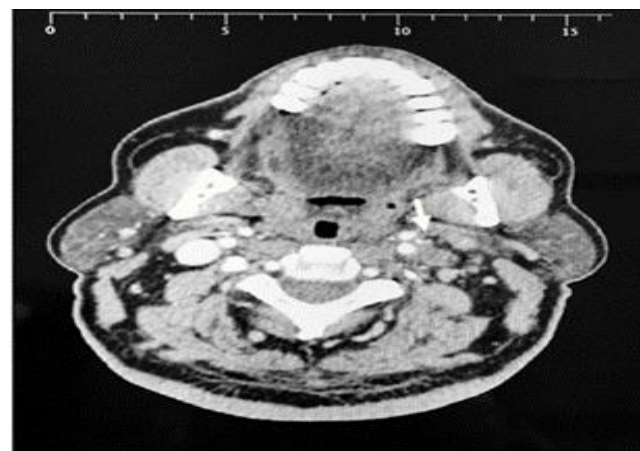

Figure 5: IJV thrombosis as luminal filling defect on left side.

He was diagnosed as LD. After consultation with infectious diseases team, intravenous tazocin 4.3 gm, clindamycin 200 mg 8 hourly and anticoagulants including warfarin and low molecular weight heparin (LMWH) at dosage of 1mg/kg body weight was started. By the 4th-day blood culture grew *Haemophilus influenzae*, sensitive to ampicillin, thus tazocin was replaced by ampicillin 1 gm 6 hrly. He responded to treatment by 3rd day with no more headache or neck pain and no fever. Intravenous amoxiclav continued for 2 weeks. He was carefully monitored for his general condition and any evidence of spread of disease and septic emboli. His chest remained normal both clinically and radiologically. He was discharged from hospital after two weeks and advised to continue oral amoxiclav 375 mg thrice daily for a total of 4 weeks. Warfarin was also continued for three months with monitoring of his INR and diabetic treatment at local health center. There was no evidence of systemic disease after three months of follow up. He was advised to undergo functional endoscopic sinus surgery (FESS) for right maxillary sinus lesion.

DISCUSSION

LD is characterized by septic thrombophlebitis of IJV commonly from the oropharyngeal source of infection often due to *Fusobacterium necropharum*.² Still, anaerobic septicemia can originate from other diverse sources such as gastrointestinal and genitourinary tract.⁹ The causative organisms in our cases were identified as *Klebsiella pneumoniae* and *Haemophilus influenzae*, and the latter has not been reported so far in the LD.

In recent times many cases have been reported in the middle age and elderly individuals with pre-existing immunocompromised conditions such as diabetes mellitus, cancer etc.^{5,6} The lung is considered to be the most common site of septic emboli followed by other organs such as liver, spleen, joints, heart and central nervous system.¹⁰⁻¹⁷ Involvement of clivus and cranial nerves in LD is infrequent. In the review of the literature, we could find 8 reported cases (including our case) of clivus osteomyelitis in LD with varied neurological involvement (Table1).

Cranial nerve involvement with clivus osteomyelitis may not always be present. In only two instances, typical "clival syndrome" with VI, XII cranial nerve involvement has been reported.^{18,19} In three cases, no lower cranial nerve involvement has been reported.²⁰⁻²² In contrast, isolated XII cranial nerve involvement is found in two patients.^{23,24} However clival osteomyelitis has also been associated with extensive thrombosis of the cavernous sinus, transverse sinus including internal carotid and vertebral artery. Extension of disease into cavernous sinus thrombosis has been reported to be accompanied by higher intracranial complications such as meningitis, brain abscess and subdural empyema, possibly as a result of spread from the same primary focus of infection.²⁵

Our case of clival osteomyelitis with IX, XII cranial nerve involvement mimicking nasopharyngeal malignancy is a very unusual presentation in LD. The ipsilateral bulge in nasopharynx both clinically and radiologically with otitis media with effusion further raised suspicion of nasopharyngeal malignancy. The pathogenesis in our case is likely to be due to the retrograde spread of septic emboli through the IJV and spread of inflammation to parapharyngeal space, prevertebral soft tissue and skull base producing smooth bulge in nasopharynx and misinterpreted as nasopharyngeal malignancy initially. This was further compounded with involvement with lower cranial nerve IX and XII. However, nasopharyngeal examination and biopsy is essential to rule out malignancy.

The atypical and rare display of clival osteomyelitis with lower cranial nerves involvement IX and XII, sparing X and XI in the jugular foramen is also unusual. Osteomyelitis of clivus with the involvement of IX and XII cranial nerve should be considered as "clival syndrome" and a feature of LD. Similar atypical clinical presentation has also been reported in skull base osteomyelitis (SBO).²⁶ Our patient did not have any otogenic or sinogenic source of infection to explain the clival osteomyelitis.

This case was also unusual, as he did not have postanginal pyrexia during the first month and had complete clinical recovery after treatment of peritonsillar abscess drainage and antibiotics. However, he complained of persistent mild neck pain at a local hospital, which was probably missed. This is to highlight the importance of a high clinical index of suspicion of underlying internal jugular thrombophlebitis. Underlying diabetes also perhaps modified the clinical presentation.

The course of the disease varies. A high index of clinical suspicion, early diagnosis of IJV thrombophlebitis and management would perhaps help in the prevention of metastatic septic emboli/abscess. A high leukocytosis and raised CRP value, absence of any neurological signs, persistent pyrexia and tenderness over neck should further raise clinical suspicion of IJV thrombophlebitis. Our second case reflects the importance of the early diagnosis and appropriate management of the condition. Isolation of *Haemophilus influenzae* in blood culture as a causative organism in LD was unusual in this case, extremely rare and not reported in the literature so far. Early diagnosis of the condition and appropriate antimicrobial therapy helped to prevent septic emboli and resolution of the disease. Riordan et al also emphasized the red flag symptoms of pyrexia, headache, unilateral neck pain/swelling along with sternocleidomastoid muscle indicative thrombosis of IJV in 26-45% cases before significant metastatic spread has occurred.¹⁷

Table 1: Clival osteomyelitis in LD.

Author	Age (Year) and sex	Primary source of infection	Co morbidity	Thrombosis clival osteomyelitis	Organism grown	Neurological findings	Treatment	Outcome
Fallahian et al ²⁰	9 F	Retroadenoidal and retropharyngeal abscess	None	Yes	<i>Fusobacterium necrophorum</i>	Nil	Antibiotics for 68 days I and D abscess	Cured
Mohamed et al ¹⁹	14 M	Acute tonsillitis with otitis media	None	Rt. IJV, Sigmoid sinus and clival osteomyelitis	<i>Fusobacterium Necrophorum, EB virus</i>	VI, XII CR	ceftriaxone and metronidazole with clindamycin for 6 weeks	Cured
He et al ²³	17 M	Sore throat/ pharyngitis	None	LtIJV, sigmoid and cavernous sinus with Lt ICA and verbral artery thrombosis and patchy consolidation lungs	<i>Fusobacterium necrophorum</i>	XII N palsy	meropenem and metronidazole with warfarin	Cured
Smyth et al ²⁴	-	Sore throat/suppurative otitis media	Anxiety/ depression	Lt IJV with sigmoid and transverse sinus, LICA thrombosis	<i>Fusobacterium necrophorum</i>	Bil XII N palsy	meropenem and metronidazole with anticoagulant	Treated
Kosuke et al ²¹	70 F	Dental extraction	Hyperetnsion	Cavernous sinus thrombosis with clivus osteomyelitis	<i>Fusobacterium nucleatum</i> and <i>Campylobacter rectus,</i>	Nil	meropenem and metronidazole	NA
Jacob et al ¹⁸	2 M	Ac mastoiditis left with perforated drum	-	Lt IJV, Sigmoid thrombosis and ICA (otogenic LS)	<i>Peptostreptococcus spp.</i>	Left VI, XII Cr nerve	Cortical mastoidectomy, amicillin, Metranidazole and anticaogulant	Resolved
Takahashi et al ²²	73 M	Headache, fever	-	Mass in cavernous sinus-suprasellar region-granuloma	<i>Fusobacterium nucleatum</i>	-	Antibiotics and steroids.	Cured
Our case	64 M	Rt peritonsillar abscess	Diabetes mellitus	Rt IJV and rt retropharyngeal swelling	<i>Klesiella pneumoniae</i>	Rt IX, XII	Antibiotics and HBOT	Cured

The management of the condition is multidisciplinary. While giving antibiotic therapy, close observation for the signs of continued sepsis, propagation of thrombus and septic emboli is vital.²⁷ The role of anticoagulants is controversial and reserved for a select group of patients not responding to antibiotics or if there is a progression of the thrombus to cavernous sinus Moore et al reported addition of anticoagulants proved to be beneficial in clinical improvement in 11 out of 41 cases of extensive thrombosis of IJV in LD.²⁸⁻³⁰ In our second case, anticoagulants were used effectively for extensive thrombosis of IJV and sigmoid sinus.

HBOT has been used successfully in treating the skull base osteomyelitis as an adjuvant to antimicrobial therapy.³¹ The beneficial effect of HBOT therapy is improvement of tissue oxygenation and amplification of oxygen gradient along the periphery of ischemic wounds created due to diabetic microangiopathy. This enhances the penetration of antimicrobial agent and phagocytic activity of macrophages, neovascularization and enhances wound healing.^{32,33} In using HBOT with antimicrobials, we could treat clival osteomyelitis successfully with recovery of IX and XII cranial nerve weakness.

CONCLUSION

LD can occur in middle age though young adults are commonly affected.

Diabetes mellitus, a global health problem should be considered as a predisposing factor for LD in modern clinical practice. A high index of suspicion is needed by the clinician as primary oropharyngeal infection could have resolved by the time the patient presents. CT neck, with contrast, is confirmatory. Early diagnosis and appropriate antibiotics help to prevent the dissemination of septic emboli. clivus osteomyelitis with neurological complications secondary to septic thrombophlebitis poses a diagnostic and therapeutic challenge.

Funding: No funding sources

Conflict of interest: None declared

Ethical approval: Not required

REFERENCES

- Courmont P, Cade A. Sur une septic-pyohemie de l'homme stimulant la peste et cause par un streptobacille anaerobie. *Arc Med Exp et d'Anat Path.* 1900;4.
- Lemierre A. On certain septicemias due to anaerobic organisms. *Lancet.* 1936;227:701-03.
- Johannesen KM, Bodtger U. Lemierre's syndrome: current perspectives on diagnosis and management: a systematic review. *Dove Press J.* 2016.
- Chuncharunee A, Khawcharoenporn T. Lemierre's syndrome caused by *Klebsiella pneumoniae* in a diabetic patient: a case report and review. *Hawai J J Med Public Health.* 2015;74(8):260-6.
- Siddique MK, Chang G, Lagmay V, Shih M. Lemierre's syndrome caused by *Streptococcus pyogenes* in an elderly woman. *J Vasc Surg Cases and Innovative Tech.* 2020;6(1):31-3.
- Pokharel A, Basnet P, Sharma B, Thapa K. Lemierre Syndrome. A Forgotten Disease. Case Report and Review of Literature. *Int Med Case Reports J.* 2019;12:367-71.
- Kristensen HL, Prag J. Lemierre's syndrome and other disseminated *Fusobacterium necrophorum* infections in Denmark: a prospective epidemiological and clinical survey. *Eur J Clin Microbiol Infect Dis.* 2008;27:779-89.
- Riordan T, Wilson M. Lemierre's syndrome: more than a historical curiosa. *Postgrad Med J.* 2004;80(944):328-34.
- Schubert AD, Hotz MA, Caversaccio MD, Arnold A. Septic thrombosis of the internal jugular vein: Lemierre's syndrome revisited. *Laryngoscope.* 2015;125(4):863-8.
- Righini CA, Karkas A, Tourniaire R, N'Gouan JM, Schmerber S, Reyt E et al. Lemierre syndrome: study of 11 cases and literature review. *Head Neck.* 2014;36(7):1044-51.
- Kim BY, Yoon DY, Kim HC, Kim ES, Baek S, Lim KJ et al. Thrombophlebitis of the internal jugular vein (Lemierre syndrome): clinical and CT findings. *Acta Radiol.* 2013;54(6):622-7.
- Iwasaki T, Yamamoto T, Inoue K, Takaku K. A case of Lemierre's syndrome in association with liver abscess without any other metastatic lesions. *Intern Med.* 2012;51(11):1419-23.
- Kieran I, Lyttle M, Leroi M. Successful antibiotic stewardship: are we a victim of our own success? *ANZ J Surg.* 2011;81(6):488-9.
- Chow BJ, Tupesis JP. Disseminated Lemierre syndrome presenting as septic arthritis. *J Emerg Med.* 2012;42(5):573-5.
- Lin HY, Liao KH, Jean SS, Ou TY, Chen FU, Lee WS et al. Lemierre syndrome with cervical spondylodiscitis and epidural abscess associated with direct injection of heroin into the jugular vein. *J Microbiol Immunol Infect.* 2015;48(2):238-9.
- Ratnasingham Y, Kristensen LH, Gammelgaard L, Balslev T. Arterial ischemic stroke as a complication to disseminated infection with *Fusobacterium necrophorum*. *Neuropediatrics.* 2014;45(2):120-22.
- Riordan T. Human Infection with *Fusobacterium necrophorum* (Necrobacillosis), with a focus on Lemierre's syndrome. *Clin Microbiol Rev.* 2007;20(4):622-59.
- Jacob R, Ravid S, Kassis I, Gordin A, Meyouhas Y. Clival syndrome secondary to anaerobic mastoiditis in 2-year old child. *Pediatr Infect Dis J.* 2015;34(9):1034-6.
- Mohamed PB, Carr L. Neurological complications in two children with Lemierre syndrome. *Dev Med Child Neurol.* 2010;52:779-81.
- Fallahian A, Desai N, Jackson MA, Decarrie JC, Rivard DC. Osteomyelitis of the clivus due to

- Fusobacterium necrophorum. *Int J Case Rep Images.* 2011;2:17-20.
21. Kosuke O, Yasuhiro N, Yosuke S, Tomo M, Kazuki SHO, Masaya W et al. Clival Osteomyelitis with Cavernous Sinus Thrombosis Due to Fusobacterium nucleatum and Campylobacter rectus Induced by Tooth Extraction. *Intern Med.* 2018;57:3325-8.
 22. Takahashi S, Ito S, Tagashira S, Yasui K, Watanabe Y, Nakashima K. A case of corticosteroid-responsive Lemierre syndrome with clivus osteomyelitis and a mass in the cavernous sinus-suprasellar region. *Rinsho Shinkeigaku (Clin Neurol).* 2015;55:327-32.
 23. He J, Lam JCL, Adlan T. Clival osteomyelitis and hypoglossal nerve palsy--rare complications of Lemierre's syndrome. *BMJ Case Rep.* 2015;2015:bcr2015209777.
 24. Smyth D, Mowat J, Rigby M. A case of Lemierres Disease complicated by bilateral hypoglossal nerve paralysis. *J Med Microbiol Infect dis Canada.* 2018;3(3):141-5.
 25. Ebright JR, Pace MT, Niazi AF. Septic thrombosis of the cavernous sinuses. *Arch Intern Med.* 2001;161:2671-6.
 26. Subburaman N, Chaurasia Mk. Skull base osteomyelitis interpreted as malignancy. *J Laryngol Otol.* 1999;113:775-8.
 27. Sinave CP, Hardy GJ, Fardy PW. The Lemierre syndrome: suppurative thrombophlebitis of the internal jugular vein secondary to oropharyngeal infection. *Medicine (Baltimore).* 1989;68(2):85-94.
 28. Lu MD, Vasavada Z, Tanner C. Lemierre syndrome following oropharyngeal infection: a case series. *J Am Board Fam Med.* 2009;22(1):79-83.
 29. Ramirez S, Hild TG, Rudolph CN, Sty JR, Kehl SC, Havens P et al. Increased diagnosis of Lemierre syndrome and other Fusobacterium necrophorum infections at a children's hospital. *Pediatrics.* 2003;112:380.
 30. Moore BA, Dekle C, Werkhaven J. Bilateral Lemierre's syndrome: a case report and literature review. *Ear Nose Throat J.* 2002;81:234-6.
 31. Mader JT, Love JT. Malignant external otitis: cure with adjunctive hyperbaric oxygen. *Arch Otolaryngol.* 1982;108(1):38-40.
 32. Amaro CE, Espiney R, Radu L, Guerreiro F. Malignant (necrotizing) externa otitis: the experience of a single hyperbaric centre. *Eur Arch Otorhinolaryngol.* 2019;276(7):1881-7.
 33. Davis JC, Gates GA, Lerner C, Davis Jr MG, Mader JT, A Dinesman. Adjuvant hyperbaric oxygen in malignant external otitis. *Arch Otolaryngol Head Neck Surg.* 1992;118(1):89-93.

Cite this article as: Kalbani BHA, Singh A, Sheibani SMA. Lemierre's disease: a typical presentation in two diabetic patients. *Int J Otorhinolaryngol Head Neck Surg* 2020;6:2279-85.