

## Case Report

# A large malignant oncocytoma of parotid gland: a case report

Nidhi Mohan Sreedevi<sup>1</sup>, Sunita S. Vernekar<sup>2</sup>, Mohammed M. Abdus Samee<sup>2</sup>,  
Manjunath Dandinarsaiah<sup>1\*</sup>

<sup>1</sup>Department of ENT, Karnataka Institute of Medical Sciences, Hubballi, Karnataka, India

<sup>2</sup>Department of Pathology, Karnataka institute of Medical Sciences, Hubballi, Karnataka, India

**Received:** 09 October 2020

**Accepted:** 11 November 2020

### \*Correspondence:

Dr. Manjunath Dandinarsaiah,  
E-mail: drmanjud@gmail.com

**Copyright:** © the author(s), publisher and licensee Medip Academy. This is an open-access article distributed under the terms of the Creative Commons Attribution Non-Commercial License, which permits unrestricted non-commercial use, distribution, and reproduction in any medium, provided the original work is properly cited.

## ABSTRACT

Malignant oncocytoma is an extremely rare neoplasm of the salivary gland accounting for 0.5% of epithelial salivary gland malignancies and 0.18% of epithelial salivary gland tumors. We report a case of malignant oncocytoma of left parotid gland in a 61-year old female patient. Patient presented with a 6-year history of painless swelling in the left parotid region. Fine needle aspiration cytology of the swelling was suggestive of pleomorphic adenoma. A computed tomography scan performed did not reveal any features suggestive of malignancy. Patient underwent left superficial parotidectomy. However, histopathological examination of the specimen turned out to be malignant oncocytoma. Malignant oncocytoma of salivary glands have rare incidence and may have similar morphologic features with other neoplasms. Despite the tumor being large and malignant in this case, there was no facial palsy preoperatively. As histopathology is often diagnostic, the possibility of malignancy always must be kept in mind preoperatively even when there is no facial palsy or fine needle aspiration cytology not showing up malignancy.

**Keywords:** Malignant oncocytoma, Salivary gland, Tumor

## INTRODUCTION

Malignant oncocytoma (MO) is a rare malignant tumor of salivary gland. MO is characterized by oncocytes that show histologic features similar to adenocarcinoma, metastasis, or both.<sup>1-3</sup> The terms oncocytic carcinoma, oncocytic adenocarcinoma, malignant oncocytoma and malignant oxyphilic adenoma are synonymously used. Its malignant nature is distinguished from oncocytoma by abnormal morphological features and infiltrative growth.<sup>2</sup> Necrosis, peri-neural spread, pleomorphism, intravascular invasion, and distant metastasis to the cervical lymph nodes, kidneys, lungs, and mediastinum are the main features of this high-grade malignant tumor.<sup>4,5</sup>

This tumor represents 5% of all oncocytic salivary gland neoplasms and less than 1% of all salivary gland tumors. MO may occur in other sites such as nose and thoracic cavities, ovary, kidney, thyroid gland, breast and parathyroid. Parotid glands are common site of MO

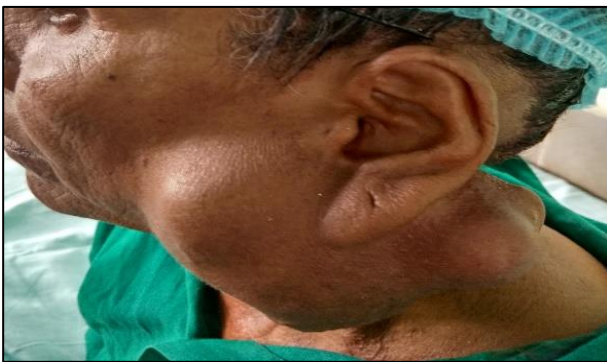compared to other salivary glands. But MO of submandibular glands and minor salivary glands have also been described.<sup>6-9</sup>

The presence of inflammatory symptoms and facial asymmetry are characteristics that strongly suggest a malignant lesion.<sup>9</sup> We report a rare case of a large MO of parotid gland measuring 7×7 cm in an elderly female patient with an intact facial nerve preoperatively. Possibility of malignancy must always be kept in mind in a large tumor even when the facial nerve is not involved and fine needle aspiration cytology (FNAC) and Computed tomography (CT) not showing any evidence of malignancy. The latter features could mislead one to go ahead with the superficial parotidectomy.

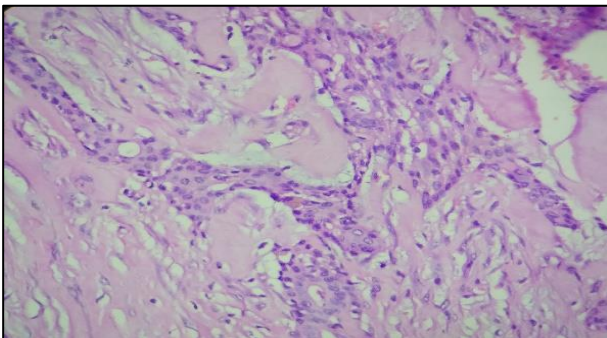
## CASE REPORT

A 61-year-old female presented with 6-year history of painless swelling in the left parotid region with gradual

increase in size. On examination a 7×7 cm swelling was noted in the left parotid region extending horizontally 4 cm lateral to angle of mouth to mastoid process and vertically from tragus to 4 cm below the angle of mandible. On palpation, the swelling was multi nodular with a large nodule and two relatively small nodules. There were dilated vessels over the swelling (Figure 1). The swelling was non-tender with variable consistency; mobile horizontally but restricted vertically. Skin over the swelling was pinchable. There was no facial palsy or regional lymphadenopathy. CT revealed a 71×56×68 mm multi-lobulated large heterogeneously enhancing mixed solid and cystic soft tissue mass involving superficial lobe of left parotid gland with no significant cervical lymphadenopathy (Figure 2). FNAC showed features of pleomorphic adenoma.



**Figure 1: Patient with left parotid swelling.**

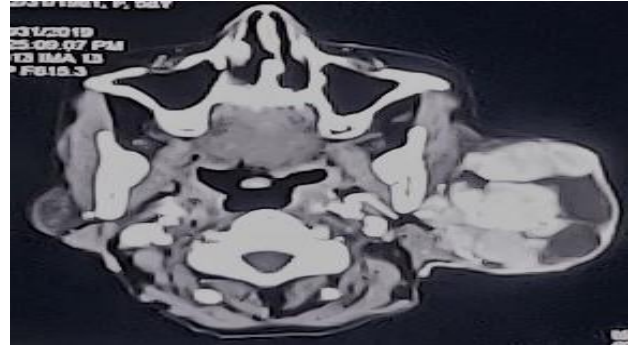


**Figure 2: Histopathology showing capsular invasion.**

This patient underwent left superficial parotidectomy and specimen was sent for histopathological examination. Marginal mandibular nerve could not be saved as it was difficult to identify nerve due to the large size of tumor. Macroscopically, the tumor was gray-brown, firm to cystic consistency with external nodular appearance. Cystic and congested cut surface showed multiple well circumscribed and capsulated gray-brown lobulated firm solid areas with focal areas of hemorrhage. Cysts were filled with either serosanguinous fluid or mucoid material.

Microscopic examination revealed oncocytes with abundant eosinophilic granular cytoplasm (due to increased cytoplasmic mitochondria). The tumor was

arranged in sheets of large round to oval cells with abundant granular eosinophilic cytoplasm. The nuclei were centrally located, round to oval with vesicular chromatin and prominent nucleoli and increased mitotic activity. There were areas of proliferating blood vessels within the tumor with areas of capsular invasion (Figure 3).



**Figure 3: CT showing multi-lobulated large heterogeneously enhancing mixed solid and cystic soft tissue mass involving superficial lobe of left parotid gland.**

## DISCUSSION

MO is an extremely rare malignancy of salivary glands. MO occurs more among elderly population than young ones.<sup>2,7</sup> Ellis et al, reported 72% of these tumors in the parotid gland.<sup>10</sup> Criteria for the diagnosis of malignancy in salivary oncocytic tumors include: distant metastasis; local lymph node metastasis; perineural, intravascular or lymphatic invasion; and frequent mitoses and cellular pleomorphism with extensive invasion and destruction of adjacent structures.<sup>11</sup> FNAC is less sensitive for oncocytic neoplasms, perhaps due to the rarity of these tumors and diagnostic pitfalls previously associated with it.<sup>2</sup> Since most of these criteria cannot be assessed on cytologic examination alone, histology is required for a definitive diagnosis.<sup>12</sup> In the present case diagnosis of MO was made only after histopathology report .

Approximately one-third of patients with MO of the parotid present with a painful mass or experience facial paralysis.<sup>13</sup> In the present case, patient had painless swelling in the parotid region without facial palsy. There were no regional or distant lymph node metastases clinically or radiologically. Preoperative facial nerve palsy is a manifestation of malignant infiltration and so far, the only preoperative indicator for planning total parotidectomy with nerve resection and facial reanimation.<sup>9,14</sup> Wierzbicka et al, found facial nerve impairment to correlate with larger tumors and a higher histologic grade of malignancy.<sup>14</sup> When the facial nerve function is intact, early involvement with tumor cannot be definitively ruled out. In the present case, despite being a large tumor there was no facial nerve palsy preoperatively and clinically no evidence suggestive of malignancy was noted. Hence, superficial parotidectomy was performed.

As with other high-grade salivary gland neoplasms, aggressive surgical intervention is indicated in the management of MO of parotid gland which consists of total parotidectomy with preservation of the facial nerve whenever possible. The efficacy of radiotherapy is unclear.<sup>5</sup> Prophylactic neck dissection may be indicated for tumors larger than 2 cm in diameter. This likely indicates a worse prognosis and due to its low incidence, many reports on prognosis are not available.<sup>2</sup> Patients with MO appear to have good short-term survival, but poor long-term survival. The average survival period has been estimated at 3.8 years with metastasizing tumors.<sup>13</sup>

Patient returned to the hospital with histopathology report after nearly 2 months. A CT scan done at the same time revealed a focal lesion measuring 9×6 mm which was either a recurrence or a residual lesion. Patient underwent ultrasound abdomen and chest X-ray which did not show any metastases. Due to the prevailing COVID situation, patient did not undergo total parotidectomy.

## CONCLUSION

MO of salivary glands have rare incidence and may have similar morphologic features with other neoplasms. Despite the tumor being large and malignant in this case, there was no facial palsy preoperatively. As histopathology is often diagnostic, the possibility of malignancy always must be kept in mind preoperatively even when there is no facial palsy or FNAC not showing up malignancy.

## ACKNOWLEDGEMENTS

Our special thanks to the Department of Pathology and Department of Radiology, Karnataka institute of Medical Sciences, Hubli for providing all the required support to publish this paper.

*Funding: No funding sources*

*Conflict of interest: None declared*

*Ethical approval: Not required*

## REFERENCES

1. Ardekian L, Manor R, Peled M, Laufer D. Malignant oncocytoma of the parotid gland: case report and analysis of the literature. *J Oral Maxillofac Surg.* 1999;57:325-8.
2. Capone RB, Ha PK, Westra WH. Oncocytic neoplasms of the parotid gland: a 16-year institutional review. *Otolaryngology--head and neck surgery: official journal of American Academy of Otolaryngology-Head and Neck Surgery.* 2002;126:657-62.
3. Caloglu M, Yurut-Caloglu V, Altaner S. Oncocytic carcinoma of the parotid gland. *Onkologie.* 2006;29:388-90.
4. Lin CC, Tsai MH, Huang CC, Hua CH, Tseng HC, Huang ST. Parotid tumors: a 10-year experience. *American journal of otolaryngology.* 2008;29:94-100.
5. Leahy T, Sader C. Oncocytic carcinoma of the parotid gland with facial nerve invasion. *BMJ case reports.* 2011;2011.
6. Zhou CX, Gao Y. Oncocytoma of the salivary glands: a clinicopathologic and immunohistochemical study. *Oral Oncol.* 2009;45:e232-8.
7. Trenkić Božinović M, Krasić D, Katić V, Krstić M. A retrospective review of 139 major and minor salivary gland tumors. *Medicinski glasnik : official publication of the Medical Association of Zenica-Doboj Canton, Bosnia and Herzegovina.* 2015;12:73-8.
8. Seethala RR, Stenman G. Update from the 4th Edition of the World Health Organization Classification of Head and Neck Tumours: Tumors of the Salivary Gland. *Head and neck pathology.* 2017;11:55-67.
9. Nakagawa M, Sohma S, Watanabe K, Murakata H, Ishii K. [A case of malignant oncocytoma of the parotid gland]. *Nihon Jibiinkoka Gakkai Kaiho.* 1996;99:1-5.
10. Ellis G, Auclair P, Douglas R. *Surgical Pathology of the Salivary Glands.* Philadelphia: W.B. Saunders. 1991.
11. Gray SR, Cornog JL Jr, Seo IS. Oncocytic neoplasms of salivary glands: a report of fifteen cases including two malignant oncocytomas. *Cancer.* 1976;38:1306-17.
12. Kimura M, Furuta T, Hashimoto S, Takano T, Nagao K. Oncocytic carcinoma of the parotid gland. A case report. *Acta cytologica.* 2003;47:1099-102.
13. Brandwein MS, Huvos AG. Oncocytic tumors of major salivary glands. A study of 68 cases with follow-up of 44 patients. *Am J Surg Pathol.* 1991;15:514-528.
14. Wierzbicka M, Kopeć T, Szyfter W, Kereiakes T, Bem G. The presence of facial nerve weakness on diagnosis of a parotid gland malignant process. *Eur Arch Otorhinolaryngol.* 2012;269:1177-82.

**Cite this article as:** Sreedevi MN, Vernekar SS, Samee MMA, Dandinarasaiah M. A large malignant oncocytoma of parotid gland: a case report. *Int J Otorhinolaryngol Head Neck Surg* 2020;6:2307-9.