

Original Research Article

Partial stapedectomy versus stapedotomy: evaluation of functional outcomes

Amine En-nouali*, Abdelfattah Aljalil, Mohammed A. Hanine,
Youssef Darouassi, Haddou Ammar

Department of Otolaryngology, Head and Neck Surgery, Avicenna Military Hospital, Marrakesh, Morocco

Received: 06 October 2020

Revised: 15 November 2020

Accepted: 17 November 2020

*Correspondence:

Dr. Amine En-nouali,

E-mail: ennouali.amine@gmail.com

Copyright: © the author(s), publisher and licensee Medip Academy. This is an open-access article distributed under the terms of the Creative Commons Attribution Non-Commercial License, which permits unrestricted non-commercial use, distribution, and reproduction in any medium, provided the original work is properly cited.

ABSTRACT

Background: Surgery is the treatment of choice for otosclerosis, its technical aspects are codified but varied and its functional results are usually excellent. The aim of this study was to compare the audiometric results obtained after partial stapedectomy and stapedotomy.

Methods: A retrospective review of records of patients who underwent stapes surgery for otosclerosis at Avicenna Military Hospital in Marrakesh (Morocco) from January 2008 to December 2018 was conducted.

Results: Air conduction thresholds before (53.3 ± 9.8 dB) and after (25.1 ± 6.5) partial stapedectomy was statistically significant ($p < 0.05$) and with stapedotomy before (56.4 ± 7.2) and after (33.1 ± 9.5) surgery also statistically significant ($p < 0.05$). However, air conduction thresholds between the two groups was not statistically significant ($p = 0.592$). Preoperative air-bone gap (ABG) in partial stapedectomy cases was 28.7 ± 8.6 dB and postoperative ABG was 5.7 ± 2.6 dB ($p < 0.05$). Preoperative ABG in patients who underwent stapedotomy was 31.2 ± 6.4 dB and postoperative ABG was 7.5 ± 5.2 dB ($p < 0.05$). ABG improvement in each group was statistically significant, but between the two groups it was not statistically significant ($p = 0.434$). A greater ABG closure rate was observed after partial stapedectomy (81.4%) than after stapedotomy (74.4%), but the difference was not statistically significant ($p = 0.236$).

Conclusions: We can conclude that both techniques are effective and safe and that the decision of which technique to perform should depend on the experience and comfort level of the surgeon with either technique.

Keywords: Air conduction, Air-bone gap, Otosclerosis, Partial stapedectomy, Stapedotomy

INTRODUCTION

Otosclerosis, also known as otospongiosis, is a disease of the temporal bone that affects the inner and middle ear leading to conductive or mixed hearing loss. It is characterized by a pathological pleomorphic replacement of normal bone with spongiotic or sclerotic bone.^{1,2} Hearing loss is the main symptom but complaints of continuous tinnitus and eventual vertigo are also observed.^{3,4} The etiologic and pathophysiologic mechanisms have not been fully elucidated despite intensive research. Different theories have been

postulated; they include viral, endocrine, hormonal, and autoimmune factors.⁵ Surgery is the treatment of choice for otosclerosis, its technical aspects are codified but varied and its functional results are usually excellent. Technological advances including the introduction of precision surgical tools, better visualization with operating microscopes, and the use of lasers to create the stapedotomy allowed causing less damage to the inner ear. More important than innovations in techniques or technology, the experience of the surgeon may be the most important determinant of successful stapes surgery.⁶ The aim of this study was to review our 11 years

experience with surgery of otosclerosis at Avicenna Military Hospital in Marrakesh (Morocco), and to compare the results obtained in otosclerosis patients undergoing partial stapedectomy and stapedotomy.

METHODS

We reviewed data from 70 ears (63 patients) that underwent surgery between January 2008 and December 2018 at the Department of Otolaryngology, Avicenna Military Hospital (Marrakesh, Morocco). The cases were divided into two groups (partial stapedectomy and stapedotomy).

Inclusion criteria

The diagnosis of otosclerosis was based on a clinical history of progressive hearing loss with intact tympanic membrane, an audiogram showing conductive or mixed hearing loss with air-bone gap of more than 30 dB and subsequently confirmed by decreased mobility of ossicular chain intra-operatively.

Exclusion criteria

Patients with sensorineural hearing loss and revision stapes surgery cases were excluded from the study.

All selected patients had a preoperative workup comprising clinical examination, audiometric data review, impedance audiometry and computed tomographic (CT) scan of the temporal bone. The surgery was done under general anaesthesia, via an endaural approach. The stapes footplate was tested for fixation to confirm the diagnosis of otosclerosis. The removal of supra structure of stapes partial stapedectomy or stapedotomy was made and a Teflon piston prosthesis was used (Figure 1).

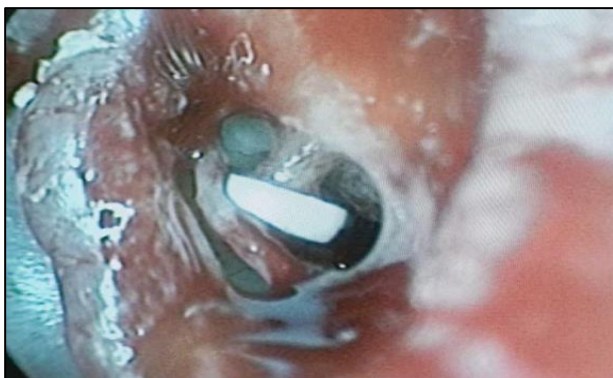

Figure 1: Intraoperative view showing the piston crimped over the long process of incus.

The oval window was sealed with temporalis fascia graft. The distance between the underside of the incus and surface of the footplate was measured, to assist in the selection of a prosthesis, which was 0.25 mm longer than

this measured distance. After testing the prosthesis position and mobility, the flap was returned to its position and secured by gel foam. Four surgeons performed surgeries.

Pure tone audiometry was performed in all patients one day preoperatively and 3 months postoperatively. Audiometric results were reported as recommended by the American Academy of Otolaryngology Committee on Hearing and Equilibrium except for thresholds at 3 kHz.⁷ The air conduction and bone conduction were evaluated at the frequencies of 0.5, 1, 2, and 4 kHz, and the preoperative and postoperative air-bone gap were calculated. Surgery was considered successful if the postoperative ABG was less than 10 dB.

Statistical analysis was done using Microsoft Office Excel 2016® software. Categorical variables were presented in terms of numbers and percentages. Numerical variables were presented in terms of mean and standard deviation. Differences were considered statistically significant if the p value < 0.05.

RESULTS

A total of 70 years of 63 patients underwent primary stapes surgery from January 2008 to December 2018. The mean age at time of surgery was 39.1 (± 9.5) years and ranged from 21 to 55 years. There were 34 (53.9%) females and 29 (46.1%) males, with a ratio of 1.17: 1. The family history for otosclerosis was positive in 14 (22%) patients and the average duration of the disease was 5.21 (± 3.9) years. Hearing loss was accompanied by tinnitus in 53 (75.7%) cases. Absent stapedial reflexes were notified in 65 (92.9%) cases and CT scan was performed for all patients, showing otosclerosis foci in 20 (31.8%) cases (Figure 2).

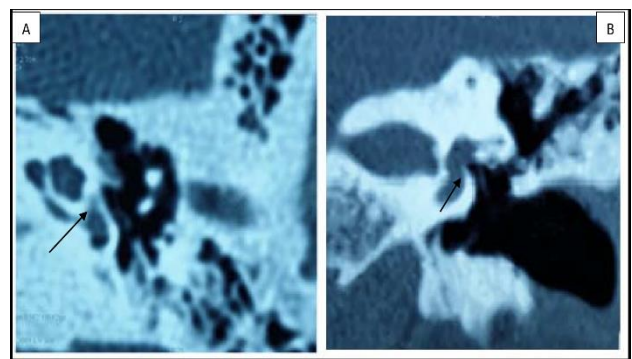


Figure 2: A (axial view) and B (coronal view) : CT scan showing hypodensity involving the vestibule.

Mean air-bone gap before and after surgery

Of the 70 cases, 27 (38.6%) were partial stapedectomies and 43 (61.4%) were stapedotomies. Complications that occurred either during or after surgery were detected in 12 (17.1%) cases (Table 1) and included 2 (2.8%) cases

with perforation of the tympanic membrane which was dealt with by grafting during surgery, 4 (5.7%) cases with chorda tympani damage, one (1.4%) case with floating footplate, 5 (7.1%) cases with vertigo lasting less than 7 days.

Table 1: Complications of stapes surgery.

Complications	Number (%)
Tympanic membrane perforation	2 (2.8)
Chorda tympani injury	4 (5.7)
Floating footplate	1 (1.4)
Vertigo lasting <7 days	5 (7.1)

Table 2: Air-bone gap closure rate.

Group	Number (%)	P value
Partial stapedectomy	22 (81.4)	0.236
Stapedotomy	32 (74.4)	

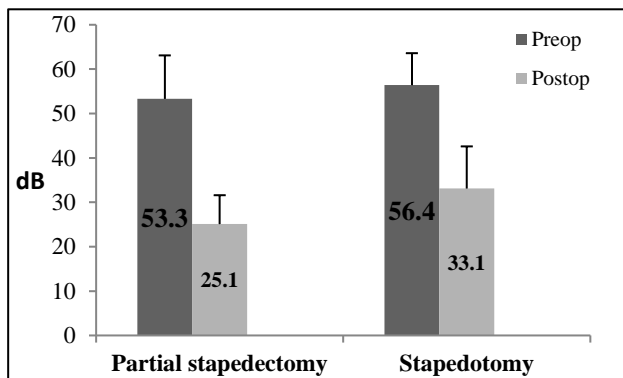


Figure 3: Mean air conduction thresholds before and after surgery.

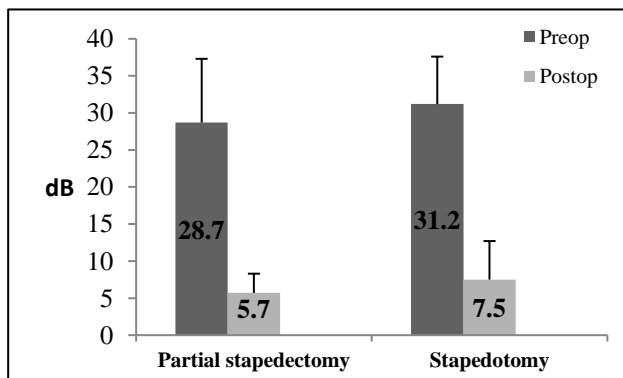


Figure 4: Preoperative and postoperative data analysis.

Air conduction thresholds before (53.3 ± 9.8 dB) and after (25.1 ± 6.5) partial stapedectomy was statistically significant ($p < 0.05$) and with stapedotomy before (56.4 ± 7.2) and after (33.1 ± 9.5) surgery also statistically significant ($p < 0.05$) (Figure 3). However, air conduction thresholds between the two groups was not statistically significant ($p = 0.592$). Preoperative air-bone gap (ABG)

in partial stapedectomy cases was 28.7 ± 8.6 dB and postoperative ABG was 5.7 ± 2.6 dB ($p < 0.05$). Preoperative ABG in patients who underwent stapedotomy was 31.2 ± 6.4 dB and postoperative ABG was 7.5 ± 5.2 dB ($p < 0.05$) (Figure 4). ABG improvement in each group was statistically significant, but between the two groups it was not statistically significant ($p = 0.434$).

Table 2 shows the rate of postoperative ABG complete closure ($ABG \leq 10$ dB). A greater closure rate was observed after partial stapedectomy (81.4%) than after stapedotomy (74.4%), but the difference was not statistically significant ($p = 0.236$).

DISCUSSION

Stapes surgery is an established treatment for conductive hearing loss in otosclerosis whose purpose is the closure of air-bone gap and producing the capability of hearing without amplification⁸. The aim of our study was to compare the hearing results of partial stapedectomy versus stapedotomy in patients operated for otosclerosis in our department. There was significant improvement in air conduction thresholds and air-bone gap in both groups. However, on comparison between partial stapedectomy and stapedotomy groups, there was no statistically significant difference. Similarly, we found no significant difference between the two techniques in term of air-bone gap closure.

The controversy of which surgical technique is more effective and safer in the treatment of hearing loss due to otosclerosis centers around three issues: first, which technique has fewer complications; second, which technique is the more effective in improving hearing; and third, which technique provides more stable long-term results in hearing improvement.⁶

Quaranta et al showed in their study that partial stapedectomy and stapedotomy obtained analogous results in term of air-bone gap closure and air conduction gain in the speech frequencies (0.5 to 3 kHz). A more detailed analysis showed that stapedotomy is associated with a significantly better air-bone gap closure at 4 kHz, air-bone gap gain at 2, 3, and 4 kHz and greater air conduction gain in the high frequencies (4 to 8 kHz) than partial stapedectomy. A similar study also showed that partial stapedectomy and stapedotomy on average gave equivalent results in term of postoperative air conduction gain at all frequencies.¹⁰ Persson et al showed that air-bone gap was smaller in partial stapedectomy compared with stapedotomy at all frequencies except 4 kHz.¹¹

On comparison of speech discrimination score, Balu et al found no statistically significant difference between the two techniques. However, the stapedotomy group showed a more significant improvement for the air-bone gap at 4 kHz than the stapedectomy after surgery.⁸

Several authors have noted that bone conduction thresholds are better in the postoperative than in the preoperative period and that the preoperative 2 kHz notch often disappears after surgery.¹²⁻¹⁴ Carhart et al first noted this phenomenon after the fenestration of the lateral semicircular canal.¹⁵ The fixation of the stapes footplate is responsible for the “Carhart effect.” In fact, bone conduction threshold not only depends on the direct transmission of the vibration to the inner ear fluids through the skull, but it is also related to the relative movement of the footplate in the oval window due to the different inertia of the ossicular chain and the otic capsule.¹⁶ Theoretically in otosclerosis surgery, bone conduction thresholds improvement should be greater if a larger portion of the footplate is restored. Cremers et al and Sedwick et al compared partial stapedectomy and stapedotomy and did not find any difference in the postoperative bone conduction threshold, whereas Persson et al showed that partial stapedectomy induced better postoperative bone conduction gain than stapedotomy at all frequencies except 4 kHz.^{10,11,17}

Although the complication of sensorineural hearing loss following stapes surgery is rare, it remains a serious side effect. Advocates of stapedotomy technique have suggested that it is a safer technique because it requires less manipulation of the footplate.^{6,18} In our study no patient suffered from sensorineural hearing loss or vertigo lasting more than 7 days.

CONCLUSION

Partial stapedectomy and stapedotomy represent the standard surgical procedures to address conductive hearing loss in otosclerosis. In our series, we did not find a statistically significant difference between the two techniques regarding the studied audiometric parameters, confirming results reported by other authors. Hence, we can conclude that both techniques are effective and safe and that the decision of which technique to perform should depend on the experience and comfort level of the surgeon with either technique.

Funding: No funding sources

Conflict of interest: None declared

Ethical approval: The study was approved by the Institutional Ethics Committee

REFERENCES

1. Chole RA, Kenna M. Pathophysiology of otosclerosis. *Otol Neurotol*. 2001;22:249-57.
2. Guan JGC, Beng YS. A retrospective study: good functional outcomes are independent of preoperative factors in stapes surgery for otosclerosis. *Research J Ear Nose Throat*. 2018;2(1):2.
3. Glasscock ME, Storper IS, Haynes DS, Bohrer PS. Twenty-five years of experience with stapedectomy. *Laryngoscope*. 1995;105(9):899-904.
4. Gilli RE, Grayeli BA, Boutin P. Otosclerosis surgical techniques and results in 150 patients. *Ann Otolaryngol Chir Cervicofac*. 2002;119(4):227-33.
5. Redfors D, Möller. Follow-up after surgery for otosclerosis. *Annals Otology Rhinol Laryngol*. 2011;20(9):608-14.
6. House HP, Hansen MR, Aziz A, Al Dakhail, John W. Stapedectomy versus stapedotomy. *Laryngoscope*. 2002;112:22-4.
7. Monsell EM, Balkany TA, Gates GA, Goldenberg RA, Meyerhoff WI, House JW. Committee on hearing and equilibrium guidelines for evaluation of results of treatment of conductive hearing loss. *Otolaryngol Head Neck Surg*. 1995;113(3):186-7.
8. Balu R, Kumar M, Nair PG. Small fenestra stapedotomy versus large fenestra stapedectomy in improving hearing ability in patients with otosclerosis: our 10 years experience. *Indian J Otolaryngol Head Neck Surg*. 2019;71:304-8.
9. Quaranta N, Besozzi G, Fallacara RA, Quaranta A. Air and bone conduction change after stapedotomy and partial stapedectomy for otosclerosis. *Otolaryngol Head Neck Surg*. 2005;133:116-20.
10. Cremers CW, Beusen JM, Huygen PL. Hearing gain after stapedotomy, partial stapedectomy, or total stapedectomy for otosclerosis. *Ann Otol Rhinol Laryngol*. 1991;100:959-61.
11. Persson P, Harder H, Magnuson B. Hearing results in otosclerosis surgery after partial stapedectomy, total stapedectomy and stapedotomy. *Acta Otolaryngol*. 1997;117:94-9.
12. Langman AW, Jackler RK, Sooy FA. Stapedectomy: long-term hearing results. *Laryngoscope*. 1991;101:810-4.
13. Berliner KI, Doyle KJ, Goldenberg RA. Reporting operative hearing results in stapes surgery: does choice of outcome measure make a difference? *Am J Otol*. 1996;17:521-8.
14. Dornhoffer JL, Bailey HAJ, Graham SS. Long-term hearing results following stapedotomy. *Am J Otol*. 1994;15:674-8.
15. Carhart R. Clinical application of bone conduction audiometry. *Arch Otolaryngol*. 1950;51:798-808.
16. Tonndorf J. Bone conduction hearing. In: Keidel WD, Neff WD, eds. *Handbook of sensory physiology*. Berlin: Springer; 1994.
17. Sedwick JD, Loudon CL, Shelton C. Stapedectomy vs stapedotomy. Do you really need a laser?. *Arch Otolaryngol Head Neck Surg*. 1997;123:177-80.
18. Kursten R, Schneider B, Zrunek M. Long-term results after stapedectomy versus stapedotomy. *Am J Otol*. 1994;15:804-6.

Cite this article as: En-nouali A, Aljalil A, Hanine MA, Darouassi Y, Ammar H. Partial stapedectomy versus stapedotomy: evaluation of functional outcomes. *Int J Otorhinolaryngol Head Neck Surg* 2021;7:18-21.