

Original Research Article

Styloidectomy: our experience with intraoral approach

Purigali S. Maradesha, Subash Chandrashekhar, Samatha K. Jayaramaiah*

Department of Otorhinolaryngology, Mysore Medical College and Research Institute, Mysore, Karnataka, India

Received: 05 October 2020

Revised: 17 October 2020

Accepted: 19 October 2020

***Correspondence:**

Dr. Samatha K. Jayaramaiah,

E-mail: samathakj@gmail.com

Copyright: © the author(s), publisher and licensee Medip Academy. This is an open-access article distributed under the terms of the Creative Commons Attribution Non-Commercial License, which permits unrestricted non-commercial use, distribution, and reproduction in any medium, provided the original work is properly cited.

ABSTRACT

Background: Eagle's syndrome is a symptom complex arising due to elongated styloid process or calcification of stylohyoid ligament. Surgical treatment is regarded as the foremost option. The study aims to put forth our experience with intraoral approach to styloidectomy in 17 subjects.

Methods: A retrospective study was conducted between January 2017 to December 2019. The study included 17 subjects with a diagnosis of elongated styloid process. All the subjects underwent styloidectomy by intraoral approach and were followed up.

Results: In our study, the median age of the study group was 33.76 and out of 17 subjects 13 were female and 4 male. The procedure was done under local anesthesia in 13 subjects and under general anesthesia in 4 subjects. Styloidectomy by intraoral approach was done in all subjects among which 15 were bilateral and 2 unilateral. 88% of the subjects were symptom free by third week.

Conclusions: The study suggests that styloidectomy by intraoral approach is minimally invasive and can be done under local anesthesia with an added advantage of quick recovery.

Keywords: Styloidectomy, Eagle's syndrome, Intraoral approach

INTRODUCTION

Eagle's syndrome is a condition related to elongation of styloid process or calcification stylohyoid ligament. The clinical features of the elongated styloid process were first described by Eagle.¹ Two distinct syndromes were identified with aberrant growth of the styloid process: the stylohyoid syndrome and the carotid artery syndrome.^{2,3} Styloidectomy can relieve pain in many patients and can be accomplished through both intraoral or extraoral approaches.

The styloid process is a narrow, bony projection from the inferior part of petrous temporal bone and is situated anteromedial to the mastoid process. It is positioned between the internal and external carotid arteries in the

neck, and lies lateral to the tonsillar fossa. In adults, the normal length of styloid process can vary between 20 and 25 millimeters.⁴ Styloid processes longer than 30 mm are called elongated styloid processes.⁵⁻⁷ Incidence of elongated styloid process is around 4-7% of which only 4% are symptomatic.⁸ The symptoms are throat pain, otalgia, foreign body sensation, dysphagia and facial pain radiating to the ear or along the mandible. Elongated styloid process is confirmed by digital palpation and radiographs. Styloidectomy remains the mainstay of treatment.

The aim of our study is to describe our experience of styloidectomy by an intraoral approach, performed under both general and local anesthesia.

METHODS

A retrospective study was conducted between January 2017 to December 2019 at Mysore medical college, Mysore. Ethical clearance was obtained from institutional ethics committee. Purposive sampling method was utilized to recruit 17 subjects who underwent styloidectomy by intraoral approach and fulfilling the inclusion and exclusion criteria.

Inclusion criteria

The subjects in the age group of 25-40 years, styloid process length of 30-38 mm and who have undergone styloidectomy by intraoral approach were included in the study.

Exclusion criteria

Subjects having symptoms of stylocarotid syndrome, neuralgia, unerupted third molar tooth and cervical arthritis were excluded.

A detailed note of all the symptoms was taken. All the subjects were examined clinically and the diagnosis was confirmed by digital palpation of tonsillar fossa and X-ray of towne’s view (Figure 1). In few subjects, dental opinion was taken to rule out unerupted third molar tooth. The procedure was performed by a single surgeon. Out of 17 subjects, 13 were performed under local anesthesia (LA) and 4 under general anesthesia (GA). All subjects underwent tonsillectomy and were followed by styloidectomy.

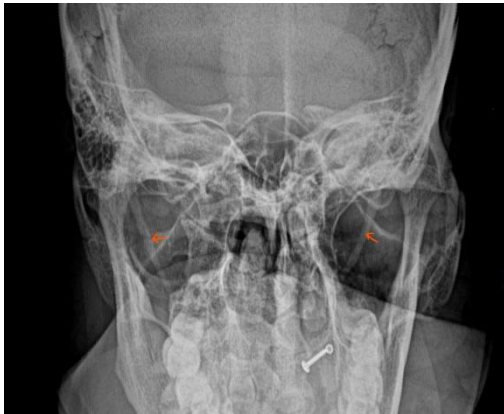

Figure 1: X-ray Towne’s view showing elongated styloid process.

In LA group, lignocaine spray of 10% was used 5 minutes before local infiltration. Local anesthetic used was 1:200000 lidocaine with adrenaline. Equal amount of anesthetic was infiltrated to the upper, middle and lower poles of the tonsils and posterior pillars on both sides. Tonsillectomy was performed by dissection and snare method. The styloid process was identified by digital palpation, superior constrictor divided, the styloid

ligament is dissected free from the calcified styloid process, and an incision is made through the periosteum of the styloid process and then excised as close to its base as possible using the straight artery forceps (Figure 2). In some cases, the styloid was held with negus artery forceps and excised using bone nibbler to avoid any inadvertent injury to internal carotid artery. The muscle bed was cleaned by povidone-iodine solution, and the muscle layer closed by 3-0 vicryl. The steps were repeated in the other fossa in bilateral cases. The postoperative protocol was as for tonsillectomy with oral antibiotics and anti-inflammatory drugs for 7 days at discharge. All the subjects were followed up at 1st week and third week.

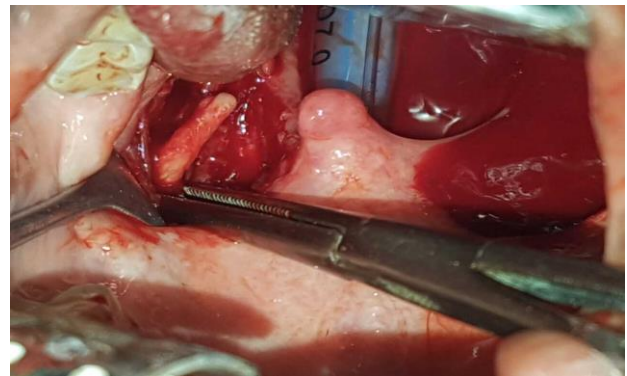


Figure 2: Intraoperative image showing elongated styloid process in left tonsillar fossa.

The parameters like age, styloid process length, duration of surgery and blood loss were recorded in all subjects and the data summarised were represented by mean and proportion.

RESULTS

The study comprised of 17 subjects with symptoms of throat pain, dysphagia, foreign body sensation in throat, otalgia and facial pain radiating to ear. The median age was 33.76 years. The mean length of the styloid process was 34 mm. Out of 17 subjects, 13 were females and 4 males. The procedure was done under local anesthesia in 13 (76.5%) subjects and under general anesthesia in 4 (23.5%) subjects. 15 subjects underwent bilateral styloidectomy while only 2 had unilateral styloidectomy. The parameters assessed were age, styloid process (SP) length, blood loss and duration of surgery (Table 1).

Table 1: Assessed parameters.

	Mean	Standard Deviation
Age (years)	33.76	4.855
SP length (mm)	34.06	2.487
Blood loss (ml)	42.59	8.412
Duration of surgery (minutes)	44.65	8.284

In current study, the mean blood loss was 42.5 ml and mean duration of surgery was 44 min. In LA group, 12 subjects were symptom free by third week. Only one subject complained of mild trismus which was relieved by 4th week. In GA group, one subject in fourth decade had temporomandibular joint (TMJ) arthritis which was relieved in 6 weeks while the other subjects were symptom free by third week. In our study, 88% of subjects were symptom free by third week.

DISCUSSION

Elongation of styloid process is an entity of unknown etiology. The length of the styloid process varies from person to person and also between the right and left styloid processes within the same individual.⁹ In addition, elongation is more commonly seen in women than in men.¹⁰

Steinmann proposed four theories for the causation of variance in ossification and elongation of the styloid process. The first theory is the theory of reactive hyperplasia which suggests that the styloid process reacts and proliferates causing elongation following pharyngeal trauma. The second theory is the theory of reactive metaplasia which suggests that the stylohyoid ligament undergoes metaplasia and partial ossification which in turn results in abnormal ossification. The theory of anatomic variance is the third theory which proposes that the ossification of the styloid process and the stylohyoid ligament is a normal occurrence depicting an anatomical variation. The fourth theory suggests that, retained embryologic tissue from Reichert's cartilage is the causative factor for elongation.¹¹ Though all the four theories give feasible explanations for the styloid process elongation, a universal agreement has not been instituted.^{12,13} Among the patients with anatomical variation, only 7.8-10.3% present with symptoms. Women are affected more often than men at a ratio of 3:1.¹⁴

Styloid elongation, as described by Correll, is classified into three types: type I represents uninterrupted elongated styloid process, type II represents a styloid process joined to the stylohyoid ligament by a single pseudo-articulation, while type III comprises of interrupted segments of the mineralized ligament, which has an appearance of multiple pseudo-articulations within the ligament. Additionally Langlai described four types of calcifications: type 1 is calcified outline, type 2 is partially calcified, type 3 is nodular complex and type 4 is complete calcification.¹⁵

A variety of symptoms manifest in accordance to length and width of styloid process. Furthermore, many of the symptoms are due to angulation where anterior angulation is more significant than medial angulation.¹⁶ Differential diagnosis for elongated styloid process include glossopharyngeal and trigeminal neuralgia,

temporal arteritis, migraine, cluster headache, cervical arthritis and impacted third molars.¹⁷

Surgical resection of styloid process is the most acceptable treatment option for Eagle's syndrome. The surgical approaches include an external (transcervical) and an internal (intraoral).

The advantages of intraoral approach observed in our study are; the procedure can be done under local anesthesia, there is no blind dissection as dissection is limited to the tip of the process, inadvertent exposure of the fossa is limited, minimal bleeding, due to the elasticity of the tonsillar bed, healing is faster, the chances of neck space infection is low, shorter operative time and postoperative complication and pain is reduced, faster recovery.

An extraoral surgical approach reduces the damage caused to the surrounding tissues and nerves that could occur during the intraoral route due to less anatomic exposure. The incision in the neck can give rise to a visible scar. Persistence of symptoms after adequate surgical excision is seen in 20% of cases, which is explained as glossopharyngeal nerve being entrapped in the fibrous tissue or the cut end of inadequately shortened styloid process irritating the overlying bed of the tonsillar fossa.¹⁸

In context of the above observations, our experience with the intraoral approach is promising and can be a desirable option in suitable patients.

Limitations

Although CT scan is the best supplement for x-ray, since it would have added to the financial burden for the subjects, it was not a mandatory investigation in our study.

CONCLUSION

Styloidectomy by intraoral approach is a minimally invasive procedure which can be done under local anesthesia. The intra-oral approach provides a shorter operative time and faster recovery. Although intraoral approach is disapproved due to its detrimental complication, if methodically planned & followed, results are satisfactory.

Funding: No funding sources

Conflict of interest: None declared

Ethical approval: The study was approved by the Institutional Ethics Committee

REFERENCES

1. Eagle W. Elongated styloid process: report of two cases. *Arch Otolaryngol.* 1937;25:584-6.

2. Baddour HM, McAnear JT, Tilson HB. Eagle's syndrome. Report of a case. *Oral Surg Oral Med Oral Pathol.* 1978;46:486-94.
3. Winkler S, Sammartino FJ Sr, Sammartino FJ Jr, Monari JH. Stylohyoid syndrome. Report of a case. *Oral Surg Oral Med Oral Pathol.* 1981;51:215-7.
4. Eagle WW. Elongated styloid process; further observations and a new syndrome. *Arch Otolaryngol.* 1948;47(5):630-40.
5. Prasad KC, Kamath MP, Reddy K JM, Raju K, Agarwal S. Elongated styloid process (Eagle's syndrome): a clinical study. *J Oral Maxillofac Surg.* 2002;60(2):171-5.
6. Ilguy M, Ilguy D, Guler N, Bayirli G. Incidence of the type and calcification patterns in patients with elongated styloid process. *J Int Med Res.* 2005;33(1):96-102.
7. Jung T, Tschernitschek H, Hippen H, Schneider B, Borchers L. Elongated styloid process: when is it really elongated? *Dentomaxillofac Radiol.* 2004;33(2):119-24.
8. Naik SM, Naik SS. Transoral transtonsillar styloidectomy: a minimally invasive technique for stylohyoid syndrome. *Int J Head Neck Surg.* 2020;11(2):23-5.
9. Custodio AL, Silva MR, Abreu MH, Araújo LR, de Oliveira LJ. Styloid process of the temporal bone: morphometric analysis and clinical implications. *Biomed Res Int.* 2016;2016:8792725.
10. Piagkou M, Anagnostopoulou S, Kouladouros K, Piagkos G. Eagle's syndrome: a review of the literature. *Clin Anat.* 2009;22(5):545-58.
11. Badhey A, Jategaonkar A, Anglin KAJ, Kadakia S, De Deyn PP, Ducic Y, et al. Eagle syndrome: a comprehensive review. *Clin Neurol Neurosurg.* 2017;159:34-8.
12. Steinmann EP. Styloid syndrome in absence of an elongated process. *Acta Otolaryngol.* 1968;66(4):347-56.
13. Steinmann EP. A new light on the pathogenesis of the styloid syndrome. *Arch Otolaryngol.* 1970;91(2):171-4.
14. Jalisi S, Jamal BT, Grillone GA. Surgical management of long-standing eagle's syndrome. *Ann Maxillofac Surg.* 2017;7:232-6.
15. Langlais RP, Miles DA, Van Dis ML. Elongated and mineralized stylohyoid ligament complex: a proposed classification and report of a case of Eagle's syndrome. *Oral Surg Oral Med Oral Pathol.* 1986;61:527-32.
16. Walli AK, Thorawade VP, Parelkar K, Nagle S, Kulsange KL. Intraoral styloidectomy in Eagle's syndrome-a risky and infrequently performed approach. *J Clin Diagn Res.* 2018;12(1):MD01-2.
17. Saccomanno S, Greco F, De Corso E, Lucidi D, Deli R, D'Addona A, et al. Eagle's syndrome, from clinical presentation to diagnosis and surgical treatment: a case report. *Acta Otorhinolaryngol Ital.* 2018;38(2):166-9.
18. Gosh LM, Dubey SP. The syndrome of elongated styloid process. *Auris Nasus Larynx.* 1999;26:169-75.

Cite this article as: Maradesha PS, Chandrashekhar S, Jayaramaiah SK. Styloidectomy: experience with intraoral approach. *Int J Otorhinolaryngol Head Neck Surg* 2020;6:2106-9.