

Case Report

Bimodal intervention in cystic lesions of the maxillary antrum

Manish Munjal*, Venus Tilavat, Porshia Rishi, Shubham Munjal,
Harjinder Sidhu, Salony Sharma, Jigisha Dosanjh

Department of ENT and HNS, Dayanand Medical College, Ludhiana, Punjab, India

Received: 30 September 2020

Revised: 06 November 2020

Accepted: 07 November 2020

***Correspondence:**

Dr. Manish Munjal,

E-mail: manishmunjal30@gmail.com

Copyright: © the author(s), publisher and licensee Medip Academy. This is an open-access article distributed under the terms of the Creative Commons Attribution Non-Commercial License, which permits unrestricted non-commercial use, distribution, and reproduction in any medium, provided the original work is properly cited.

ABSTRACT

Intrinsic or extrinsic cysts are common maxillary antral lesions as there is close proximity between the maxillary antrum and maxillary teeth. Main stay of treatment is complete surgical excision. Endoscopic trans nasal middle meatus corridor and the canine fossa approach facilitate 360-degree access, resection and removal of cystic lesions of the maxillary antrum. Bimodal technique to treat maxillary cysts that have expanded into the maxillary sinus is discussed here.

Keywords: Maxillary sinus, Endoscope, Excision, Cyst

INTRODUCTION

Cystic lesions of the maxilla with an expansile potential relative to the growth spurts, present as an enigma to the surgical interventionist. Recidivism aptly covers the "residual" or "recurrence", that is likely in these benign ballooning pathologies tethered onto the alveolar ridge. The molars and the premolars being the primary contributors. Cyst with a floating tooth and one based on root apices, captioned the dentigerous cyst and dental cyst respectively are accidentally detected on imaging studies i.e. plain radiography, computed tomography or magnetic resonance imaging being carried out for pathologies unrelated to the maxilla under consideration. A flattening or bulge of the canine fossa in young males is typical of such underlying pathology. The lesion involving the tooth or if the tooth is missing adjacent to the lesion suggests an odontogenic origin.¹ The common presenting symptoms are swelling or pain in the cheek and the bucco-gingival fold of the maxilla.² We describe a bimodal technique to treat maxillary cysts that have expanded into the, the maxillary sinus.

CASE REPORT

A 20-year young robust male presented with a bulge on the left cheek for 6 months (Figure 1). The colour and texture of the site matched the adjoining skin. There was no localised pain or tenderness. Ct scan showed a cystic lesion occupying the left maxilla (Figure 2).

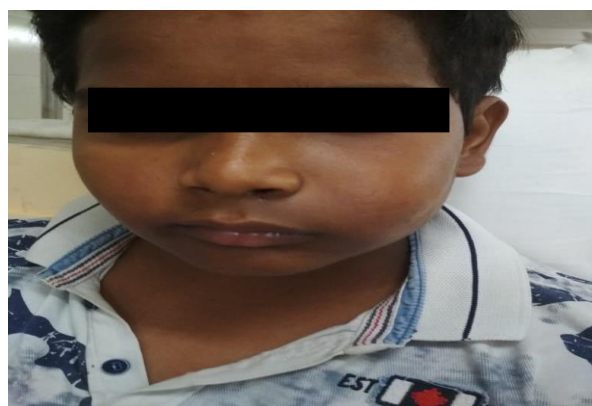

Figure 1: Left cheek swelling.

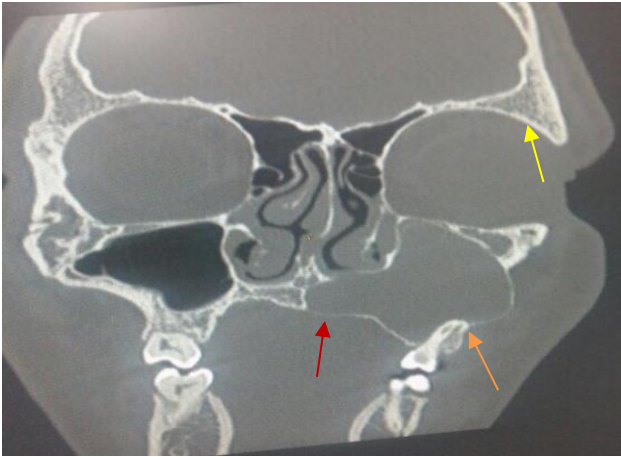


Figure 2: Cystic lesion left maxilla with extension till postero-lateral wall of the sinus (orange mark) orbital roof (blue mark), body of zygoma (yellow mark) and thinned out palatine bone (red mark).

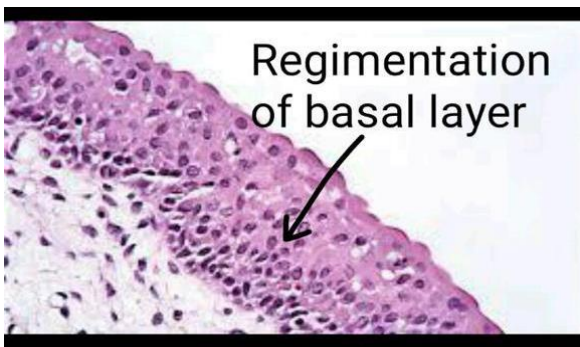


Figure 3: HPE showing regimentation of basal layer.

The cyst wall could be delineated with a plane of cleavage from orbital roof (red line), body of zygoma (yellow marking), maxillary floor and the anterior and posterior fontenellae of the medial wall. Under general anaesthesia, the medial wall of the maxillary sinus was visualised with a zero-degree endoscope and was nibbled off using back biting Kerrison ronguers. After delineating the medial edge of the cyst, it was meticulously peeled off from the underlying party wall of the orbit, the lateral zygomatic recesss and the postero-lateral wall of the sinus (orange marking). This clockwise navigation was facilitated by employing, 30, 45 and 70-degree, 4 mm nasal endoscopes.

To access the antero- infero-medial and posterior –infero-lateral crevices of the maxilla, a sublabial incision was made and the canine fossa exposed. The anterior wall antrotomy was circumferentially widened to expose the entire lining of the cyst . Endoscopic assisted "peeling" off, of the cyst wall was here undertaken in an anti-clockwise manner.

Due care was taken not to leave any cyst lining, particularly in the body of the zygoma and antero–infero-medial and posterior- infero lateral crevices of the

maxilla. A trans nasal middle meatus antrostomy completed the procedure.

Antibiotic smeared saline inflatable surgical sponges (merocel s) were retained in the maxillary sinus and the middle meatus to achieve tamponade haemostasis. Tissues, bony and soft were sent for histopathological examination.

Histopathological features were consistent with odontogenic keratocyst cyst from maxilla (Figure 3, 4).

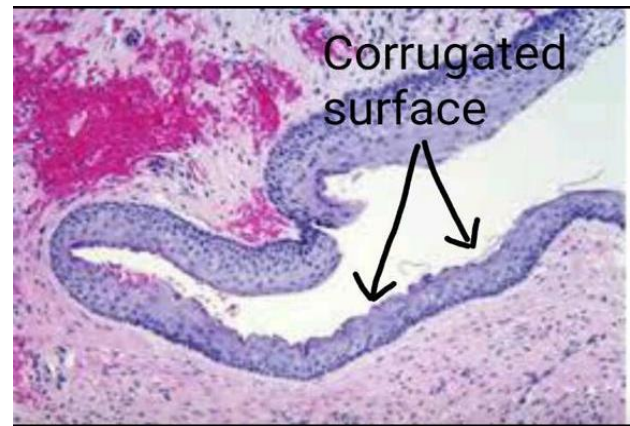


Figure 4: HPE examination showing corrugated surface.

DISCUSSION

Hirschman made the first attempts at dental socket antroscopy in 1901.³ The Trans-canine-fossa maxillary sinuscopy procedure was described by H Stammberger.⁴ Endoscopy first emerged as a diagnostic tool but became a surgical one on the way.

In the study by Ruprecht et al of 1685 patients, 44 (2.6%) had one or more mucous retention cysts in the maxillary sinuses.⁵ Radiographically, the lesions are either unilocular or multilocular with surgery being the main stay of treatment.²

A 4 mm 0°, 45° or 70° rigid nasal endoscope is used in most of the maxillary cysts to remove these through the natural sinus ostium as described in the study by Hadar et al.⁶

Endoscopy provides less invasive surgery and high definition direct view on the extent of the lesion as reported in literature.^{7,8}

Anterior inferior or medial inferior walls of the maxillary sinus are difficult to be visualized with the use of zero-degree endoscopes. Thus, Angled endoscopes (30°, 45°, 70°) play a vital role in removal of entire pathology from these difficult to assess areas of maxillary sinus.

In this case the cyst was extending medially beneath the floor of the nasal cavity with a thinned out palatine bone (red marking). The latter being a deterrent to adopting a purely transnasal endoscopic medial maxillectomy corridor lest there be a palatine breach at the antero-medial maxillary floor. Endoscopic access and

visualisation trans nasally utilizing 0-30 - 45-70-degree scopes leaves behind a "blind spot", (Figure 5) at the antero - infero - medial region which cannot be visualised and pathology, cyst lining in the present scenario may be left behind, which grows later to reline the sinus.

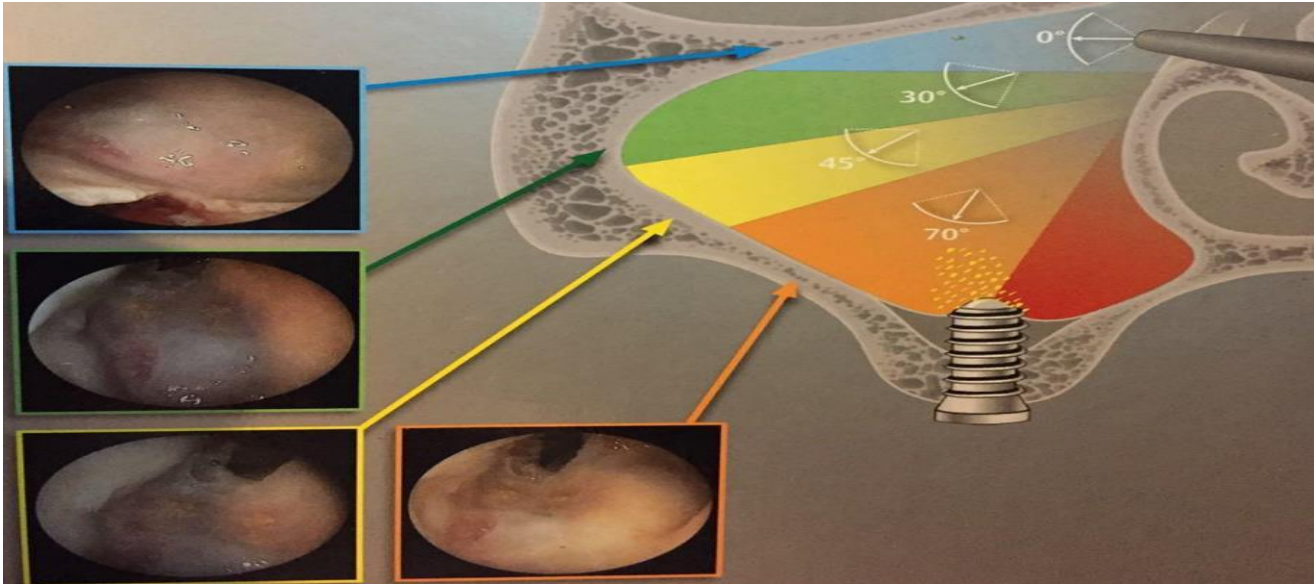


Figure 5: Intraoperative endoscopic view showing removal of left maxillary cyst.

Thereby one can undertake a conventional inferior meatal "tilley harpoon antrostomy" with endoscopic 45/70-degree visualisation while removal of the cyst wall with instrumentation through the middle meatal antrostomy. The other alternative being the endoscopic assisted sublabial canine fossa approach, whereby entire lining can be peeled off.

CONCLUSION

Utility of telescope with angulation facilitates visualization of entire maxillary sinus and thereby surgical intervention in areas hidden from straight eye view.

Funding: No funding sources

Conflict of interest: None declared

Ethical approval: Not required

REFERENCES

1. De Ustuner E, Fitoz S, Atasoy C, Erden I, Akyar S. Bilateral maxillary dentigerous cysts: a case report. *Or Surg, Or Medic, Or Pathol, Or Radiol Endodontol.* 2003;95(5):632-5.
2. Kaneshiro S, Nakajima T, Yoshikawa Y, Iwasaki H, Tokiwa N. The postoperative maxillary cyst: report of 71 cases. *J Or Surg.* 1981;39(3):191-8.

3. Pfliegerer AG, Croft CB, Lloyd GA. Antroscopy: its place in clinical practice. A comparison of antroscopic findings with radiographic appearances of the maxillary sinus. *Clinic Otolaryngol Alli Sci.* 1986;11(6):455-61.
4. Yanagisawa E, Klenoff JR. Trans-canine-fossa maxillary sinuscopy for biopsy via the Stammberger technique. *Ear Nose Thr J.* 2001;80(8):488-92.
5. Ruprecht A, Batniji S, El-Neweihi E. Mucous retention cyst of the maxillary sinus. *Ora Surg, Ora Medic, Or Pathol.* 1986;62(6):728-31.
6. Hadar T, Shvero J, Nageris BI, Yaniv E. Mucus retention cyst of the maxillary sinus: the endoscopic approach. *Brit J Ora Maxillofac Surg.* 2000;38(3):227-9.
7. Procacci P, Trevisiol L. A modified technique for endoscopic endonasal reduction of medial orbital wall fracture using an absorbable packing. *Oral Maxillofac Surg.* 2017;21:91-8.
8. Colletti G, Pipolo C, Lozza P, Felisati G, Allevi F, Biglioli F, et al. Orbital medial wall fractures: purely endoscopic endonasal repair with polyethylene implants. *Clin Otolaryngol.* 2016;43(1):396-8.

Cite this article as: Munjal M, Tilavat V, Rishi P, Munjal S, Sidhu H, Sharma S, et al. Bimodal intervention in cystic lesions of the maxillary antrum. *Int J Otorhinolaryngol Head Neck Surg* 2020;6:2320-2.