

## Original Research Article

# Vascularized middle turbinate mucoperiosteal flap in skull base defects: follow-up analysis of 20 cases

Shibu George\*, Sandeep Suresh

Department of ENT, Government Medical College, Kottayam, Kerala, India

**Received:** 06 December 2016

**Accepted:** 20 December 2016

**\*Correspondence:**

Dr. Shibu George,

E-mail: [drshibugeorge@gmail.com](mailto:drshibugeorge@gmail.com)

**Copyright:** © the author(s), publisher and licensee Medip Academy. This is an open-access article distributed under the terms of the Creative Commons Attribution Non-Commercial License, which permits unrestricted non-commercial use, distribution, and reproduction in any medium, provided the original work is properly cited.

### ABSTRACT

**Background:** Vascularized flaps are preferred in repair of skull base defects since they provide quality tissue volume and allow rapid healing. Though nasoseptal flap is the gold standard it may not be available always and has its own share of pitfalls; this makes the middle turbinate flap a viable alternative. This descriptive study was designed to analyze the efficacy of middle turbinate flap in endoscopic closure of skull base defects and to define indications and limitations of the flap.

**Methods:** 20 patients who underwent endoscopic closure of small and medium sized skull base defects using middle turbinate mucoperiosteal flap were analyzed and followed up. Etiology, presentation, site and co-morbidities associated with such defects were studied. Effectiveness of closure was analyzed by the ability to cover fully, graft uptake and complications.

**Results:** Successful flap take up was noted in all 20 cases (100%) on long term follow up; transient cerebrospinal fluid leak was observed in 1 case (5%) during the immediate post-operative period which subsided fully. Spontaneous CSF rhinorrhea (n=11 [55%]) was the most common indication for closure and unilateral watery rhinorrhea was the commonest presentation (n=13 [65%]). Benign intracranial hypertension was found to have significant association with cerebrospinal fluid rhinorrhea. Most common site of leak was the medial lamella of cribriform plate (n=11 [55%]).

**Conclusions:** Middle turbinate flap is an effective alternative to nasoseptal flap for small and medium sized anterior skull base defects; efficacy in larger defects and posterior sellar defects cannot be substantiated.

**Keywords:** Surgical flaps, Pedicled flap, Turbinates, Skull base, Cerebrospinal fluid rhinorrhea

### INTRODUCTION

The aim of skull base reconstruction is to seal the defect and separate sinonasal tract from the cranial cavity so as to prevent CSF leak and consequent intracranial complications. Smaller defects are satisfactorily repaired by free grafts, but are limited by unacceptably high rates of CSF fistula in larger defects. Substantial improvement in these outcomes has been brought about by vascularized flaps providing larger volume, greater quality tissue, which promote rapid tissue healing by restoring blood supply around such large defects. The nasoseptal flap (NSF) designed by Hadad and Bassagasteguy is the most

popular option in current scenario sealing off even extensive defects with success rates in excess of 95%. However, NSF does have its own share of limitations and may not be available always. The vascularized middle turbinate flap (MTF) is a reliable technique for reconstruction of small and medium sized skull base defects either as the first choice or as an alternative when NSF is not available. It comprises of the mucoperiosteum of the middle turbinate based on the vascular pedicle from posterior-lateral nasal artery, a branch of sphenopalatine artery. Efficacy of the MTF in closure of skull base defects, either as first choice or as an

alternative to NSF was studied with an aim to define its indications and limitations.

## METHODS

20 patients who underwent endoscopic closure of skull base defects using vascularized middle turbinate mucoperiosteal flap between January 2011 to October 2015 in the department of ENT, Government Medical College Kottayam, Kerala, India, were taken up for follow-up analysis after obtaining the necessary approval and clearance from the Scientific Review Board and Ethical committee. Informed consent about the study was obtained from the patient or from the parent (if less than 18 years of age). Patients with small to medium sized skull base defects of size 0.5 cm<sup>2</sup>–3 cm<sup>2</sup> confined to cribriform plate and fovea were selected for MTF closure as a primary option. Patients with sellar defects where NSF was unavailable or not practical were also chosen for closure with MTF. Exclusion criteria included patients who had larger skull base defects (> 3 cm<sup>2</sup>) and sellar defects where NSF was available. Very small defects (< 0.5 cm<sup>2</sup>) needing only free grafts for closure and patients with previous history of surgery on middle turbinate or sphenopalatine artery ligation were also excluded. All patients were subjected to a detailed history and endoscopic endonasal examination. High resolution CT scan of PNS & skull base (1mm sections) were obtained; MRI evaluation was added for meningo-encephalocele or tumors. Septic foci or nasal allergy were adequately treated; ophthalmology evaluation was obtained for patients with spontaneous CSF leak to rule out benign intracranial hypertension. All other co-morbidities were managed appropriately and brought under control.

## Technique

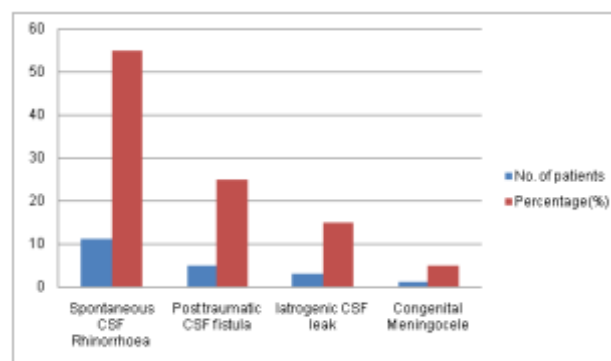
After infiltration, a sagittal incision was made anteriorly along the middle turbinate cutting right up to bone, from just below attachment on skull base to the tip. The turbinate bone was nibbled off after elevating the mucoperiosteum on either side; this was separated and mobilized from the lateral nasal wall by making a horizontal cut at the axilla, tracing backwards to the pedicle at sphenopalatine foramen. This posteriorly based vascularized mucoperiosteal flap was then rotated to the defect with the periosteal side applied to skull base. Primary plugging of the defect was done beforehand with abdominal fat after preparation by removal of the mucosa all round. A 'bath plug technique' was adapted in slightly larger anterior skull base defects to keep the fat in situ. The flap was placed over this fat layer and stabilized with surgical and tissue glue. A Foley's catheter inflated within the nose kept the flap well approximated to the skull base defect.

Patients were confined to bed or chair with toilet privileges for 2 days. Foley's catheter was removed on the 2nd day; antibiotics, Crystalline Penicillin and

Ceftriaxone started peri-operatively were continued for 5 days and discharged. They were called for 1st follow-up after 2 weeks when flap viability was assessed; further follow-ups were at 6 weekly intervals for a minimum period of 6 months. Analysis of patients by demographic characteristics, presentation, co-morbidities, site of skull base defect, peri-operative events and follow-up were made; ability of flap to fully cover the defect, graft take up and post-operative complications were noted.

## RESULTS

The youngest patient was 6-years old and oldest 71-years; average age-group of patients in the study was 39.6 years as shown in Table 1. Spontaneous CSF leak (n=11[55%]) constituted the single most common indication for surgical closure. Accidental trauma was the predisposing cause in 5 patients. There were 3 cases of iatrogenic CSF leaks following pituitary tumor surgery. 1 case was congenital meningocele in a 6-year old girl as in Figure 1.



**Figure 1: Bar diagram showing aetiology of skull base defects.**

Most common clinical presentation as in Table 2 was unilateral watery nasal discharge (n=13[65%]). Of these 10 patients had spontaneous CSF rhinorrhoea while 3 had history of trauma. 3 patients presented as recurrent meningitis, 2 following trauma and 1 after spontaneous CSF rhinorrhoea. CSF leak was a retrospective diagnosis in all 3 patients during investigations for recurrent meningitis. 3 patients had post-operative CSF fistula following pituitary tumor surgery and 1 patient with meningocele presented as unilateral nasal mass noticed in early childhood.

Patients with spontaneous CSF rhinorrhoea were found to have significant association with benign intracranial hypertension; it was seen in 6 patients with spontaneous leak. Other co-morbidities included diabetes mellitus, dyslipidemia, hypothyroidism, hypertension, coronary artery disease, bronchial asthma and Cushing's disease.

The site and size of skull base defect as in Figure 2 was initially estimated by pre-operative HRCT evaluation with 1mm sections; the findings were confirmed during endoscopic evaluation. Most common site was cribriform

plate (n=14[70%]); it was localized on the medial lamella of cribriform plate in 11 and on the lateral lamella, towards the fovea in the remaining 3. One patient had multiple defects (three) located along the cribriform plate antero-posteriorly while all other patients had only single defects. Cribriform plate was the site of leak in all patients with spontaneous CSF rhinorrhea, in 2 patients following trauma and in the child with congenital meningocele. 6 patients had defects of the sphenoid roof; post traumatic in 3 and iatrogenic in 3. All sellar defects were anterior towards the tuberculum sellae. Estimated mean size of the skull base defects was 1.8 cm<sup>2</sup>, with a range between 0.9-2.7 cm<sup>2</sup>. In general, defects in spontaneous CSF leaks localized to the cribriform plate region were smaller while the sellar defects, especially post-surgical were larger.

All patients underwent a nasal endoscopy to locate the site of CSF leak, verify presence of coexisting meningo-encephalocele, and look for associated anatomical abnormalities in the nose and plan flap selection. 7 patients had meningo-encephalocele, confirmed by MRI evaluation. Of these, 6 were associated with spontaneous CSF rhinorrhea while 1 was congenital. All herniations were located medial to the middle turbinate anteriorly in the region of cribriform plate. 2 patients had significant ipsilateral septal deviation with spur compressing the

middle turbinate and compromising space for manipulation on the same side; hence, had to undergo preliminary endoscopic septoplasty to improve space. The 3 patients with post-traumatic sellar defects had associated septal perforations making NSF unavailable; 3 patients with CSF fistulae after pituitary surgery needed a posterior septectomy during initial access into the sphenoid sinus and hence the NSF was not considered for reconstruction.

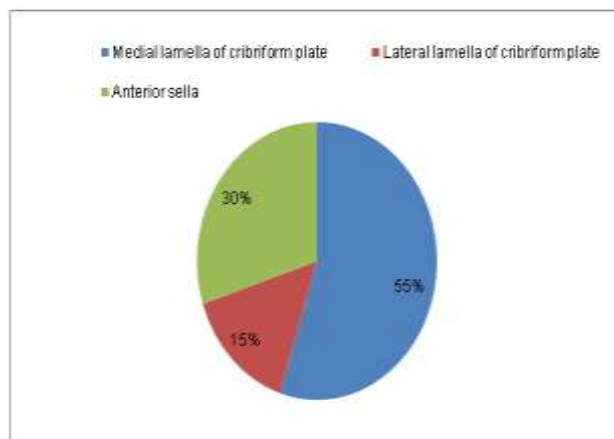


Figure 2: Pie chart showing site of skull base defects.

Table 1: MTF for skull base repair: age & sex distribution, comorbidities and results.

Age group (in years)	No. of males	No. of females	No. of cases with Meningo encephalocele	No. of cases with co-morbidities	No. of cases with successful graft uptake
6-25	1	2	1	0	3
26-50	5	5	3	4	10
51-75	3	4	3	6	7
<b>Total</b>	<b>9</b>	<b>11</b>	<b>7</b>	<b>10</b>	<b>20</b>

Table 2: Clinical presentation of patients who underwent endoscopic repair for skull base defects.

Clinical presentation	No. of patients (%)
Watery nasal discharge	13 (65)
Recurrent meningitis	3 (15)
Per-operative CSF fistula	3 (15)
Nasal mass	1 (5)

Table 3: MTF for skull base repair: postoperative complications.

Post-operative complications	No. of patients (%)
Transient CSF leak	1 (5)
Aseptic meningitis	1 (5)
Rhinosinusitis	1 (5)
Crusting	2 (10)
Synechiae	1 (5)
Minor epistaxis	2 (10)

There was satisfactory graft uptake in all patients (n=20[100%]) without any CSF leak on long term follow up. 1 patient developed transient CSF rhinorrhea in the immediate post-operative period. He was put on lumbar drain with a drainage volume of 100-200 ml per day and the leak subsided within 3 days without any further recurrence. 1 patient developed aseptic meningitis, presenting as fever, headaches and nuchal rigidity on the first post-operative day; recovered fully with conservative management. Sinusitis was observed in 1 patient in the second week and needed added antibiotics. Other observed complications included transient crusting, synechiae and minor nasal bleeding as presented in Table 3.

## DISCUSSION

Skull base defects result in abnormal communication between the intracranial cavity and sinonasal tract which might result in cerebrospinal fluid fistula, potential intracranial suppuration and pneumocephalus. In general,

small skull base defects less than 1 cm are well managed with free grafts while moderate and large defects need pedicled flaps since they provide larger, better quality tissue volume aiding in rapid healing without tissue necrosis.<sup>1,2</sup> The nasoseptal flap (NSF) designed by Hadad and Bassagasteguy with its robust vascular supply from posterior septal artery, large surface area of 15 cm<sup>2</sup> and very good arc of rotation is the most effective of the vascularized flaps. It allows near perfect reconstruction of even extensive defects with a success rate as high as 95%.<sup>1-3,11</sup> Reyes et al described it to be the “tip of the spear” of most endoscopic skull base repairs.<sup>2</sup> However, NSF has its own share of limitations. It needs pre-emptive harvesting even before the skull base defect is assessed and prepared. Elevation may not be practical after prior posterior septectomy which can sever the connection between the pedicle and residual septal mucoperichondrium; wide sphenoidotomy extending inferiorly to the sphenoid floor can injure the nasoseptal artery and compromise flap viability. There are also theoretical risks of producing nasal crusting and hyposmia.<sup>3</sup> This quandary has led to the search for alternate options when the NSF is deemed unavailable or not practical. MTF is based on the middle turbinate branch of the posterolateral nasal artery which after descending along the vertical plate of palatine bone enters the posterior aspect of middle turbinate and courses inferiorly dividing into two branches supplying both surfaces. MTF has been advocated in many studies as a viable alternative for the reconstruction of defects involving cribriform plate, fovea ethmoidalis, planum sphenoidale, and sella in patients for whom NSF is not available.<sup>2-7</sup>

In comparison to the NSF, size of MTF is small providing an effective surface area of only about 6 cm<sup>2</sup> which may not suffice in larger defects.<sup>4,6</sup> In many studies surface area as an independent factor did not correlate well with ability of the flap to cover sellar defects, while dimensions like length and width of the flap assumed more significance. Prevedello et al in a cadaveric feasibility study on the MTF, observed the average length to be 4-4.7 cm with a width of 1.5 cm.<sup>4</sup> Similarly, the average length of the MTF ranged between 3.8-4.2 cm with a superior width of 1.4-1.9 cm in an anatomical and surgical study conducted by Gras Carberizo et al.<sup>3</sup> The average length of the MTF in our series was roughly about 4 cm with a width of about 1.5cm. Larger flap was possible in presence of concha bullosa due to availability of greater surface area and vice versa when the turbinate size was small.

Majority of studies on the MTF are equivocal on its utility in covering defects of the cribriform plate, fovea and even up to the planum.<sup>2,4</sup> 14 patients in this study presented with defects of anterior skull base; 11 of these were in the medial lamella of cribriform plate while 3 were at the lateral lamella towards the fovea. The MTF was selected as the primary option here due to close proximity to the defect and ease of flap rotation and

placement. The nasoseptal flap was preserved as an alternative in these cases, if the middle turbinate flap procurement turned out to be technically difficult or in the event of failure of flap to seal the defect.

6 patients who had sellar defects in our series could be satisfactorily closed with the MTF. As per Gras Carberizo et al, reach of the MTF could be extended to the sellar region and even upto upper third of clivus.<sup>3</sup> Amin et al, used middle turbinate itself as a composite flap with bone, to close sellar defects after hypophysectomy with a success rate of 96%.<sup>5</sup> The NSF was our ideal first option in all sellar defects, but was deemed unsuitable due to septal perforations and posterior septectomy compromising the flap vascular pedicle viability; hence the MTF was tried as the alternative. Julian et al, has reported successful use of MTF for failed NSF after prior septectomy.<sup>6</sup> Yip et al, also has suggested MTF as alternative to the NSF, when it is not available due to tumor involvement or surgery of the septum.<sup>7</sup> However, the reach of this flap in posterior sellar defects remains circumscribed. In the study by Prevedello et al, MTF covered 100% of defects localized to ethmoidal groove but only 83% of sellar defects; flaps that were not suitable for repair of sellar defects were less than 4 cm in length.<sup>4</sup> In our series though all 6 sellar defects could be covered fully, the flap was only just sufficient in 2 cases; in one the turbinate was small with paradoxical curvature while in the other the flap could not be satisfactorily elevated. Limitation of MTF in covering sellar defects has been attributed to its due to its small size and limited pedicle reach.

MTF has the dual advantage of fast healing and low incidence of complications. Bhatki and Pant et al, attributes this to its satisfactory surface area, good arc of rotation and quick healing.<sup>8</sup> None among the 5 patients treated by Otto et al, developed postoperative CSF leak; In a study of 18 patients using MTF by Marks, there was 100% initial graft uptake and 94% on the longer run.<sup>9,10</sup> In our series, none of the 20 patients developed CSF leak on long term follow-up and repair deemed successful in all cases (100%). 1 patient who developed transient postoperative CSF leak had a sellar defect. Flap was just sufficient for full coverage of the defect due to want of length; it subsided fully within 3 days by conservative management with no further recurrences. In a study of 4 patients who had undergone MTF reconstruction of skull base defects, Wang et al, found that none of the 4 patients developed complications.<sup>11</sup> The major complication observed in our series was aseptic meningitis probably due to dural irritation by surgery. Other intracranial complications like pneumocephalus or intracranial abscess were not observed. Sinusitis was observed in 1 patient. Surgical manipulations during MTF harvest can result in malposition of uncinate and ostiomeatal unit oedema with consequent sinusitis. Careful inspection of the CT scan is hence prudent pre-operatively to determine the position or variations of the middle turbinate and uncinate process.

Among the pedicled flaps based on the sphenopalatine artery the MTF is technically most difficult due to anatomical variations of the turbinate, fixture instability and its thin mucosa.<sup>4,12</sup> Elevation of mucoperiosteum from the bone of the turbinate needs considerable skill since it may get torn off during the procedure. In the series by Bhatki and Carrau et al, the flap could not be used to cover sellar defect in a case since it was irreversibly torn during elevation.<sup>12</sup> This flap is difficult to harvest in patients with previous history of surgery on the middle turbinate, anatomical variations like paradoxical curvature and not practical in patients who have undergone previous ipsilateral sphenopalatine artery ligation. In our series MTF could be satisfactorily elevated and harvested in 16 cases; elevation was easier in presence of concha bullosa since it is possible to cut directly into the bulbous turbinate and bone being less adherent to the mucoperiosteum separation is much easier. Elevation of flap was difficult and was torn in the remaining 4 since the turbinate was small with paradoxical curvature making it unstable on manipulation. Elevation was also difficult and cumbersome when there was less space for manipulation due to ipsilateral septal deviation; 2 patients in our series underwent primary endoscopic septoplasty to improve space.

It is prudent to observe certain precautions during procurement of the flap which otherwise may result in inadequate elevation and improper cover. According to Patel et al, MTF is difficult to elevate since it is composed of a thin mucosal layer well adherent to bone.<sup>13</sup> Primary infiltration on to the turbinate should be in the sub-periosteal plane and incision straight and neat without jagged edges cut up to bone to allow for subperiosteal dissection. Identification of the pedicle by following it up to the sphenopalatine foramen allows for an increased length of the flap and a better arc of rotation into the skull base defect; this is especially true in sellar defects where a smaller length of less than 4 cm may not suffice.<sup>3,6,12</sup> Careful dissection at the anterior portion of the horizontal part of middle turbinate is warranted here to prevent inadvertent injury to the vascular pedicle. The recipient area should be adequately prepared beforehand and multilayer reconstruction after primary plugging with fat is always preferred.<sup>2,11,13</sup> The packing around the flap should not be too tight; Foley's catheter should be inflated under endoscopic control within the nose, since hyperinflation can result in compromise of the vascular pedicle, displacement of the tissues or even intracranial compression.

Apart from the technical and ergonomic issues of harvesting MTF there are other factors which need consideration. Middle turbinate is an important landmark in sinonasal surgeries and its preservation has been advocated since absence may influence future surgeries. Though removal of the turbinate may not have an immediate bearing on the nasal physiology issues in ventilation and humidification need be considered on

long term follow up.<sup>11,14</sup> Attachment of the middle turbinate makes skull base vulnerable during surgical manipulations with possible creation of iatrogenic defects and consequent CSF fistulae during the procedure. Special care hence need be taken throughout these maneuvers to avoid untoward traction on the middle turbinate to destabilize and cause fracture at its attachment to the skull base.

## CONCLUSION

The pedicled middle turbinate mucoperiosteal flap is an effective reconstruction option for small to medium sized skull base defects along the anterior skull base. It may be used as the primary reconstruction option in defects of cribriform plate and fovea, preserving the nasoseptal flap as a reserve for failures. The flap is also effective in anterior sellar defects in cases where the nasoseptal flap is unavailable or not practical. Skilled and refined endoscopic surgical technique is necessary for proper procurement of the flap and avoiding complications. The size and anatomical variations of the middle turbinate may influence the outcome during flap harvest. Middle turbinate flap is not practical in patient's undergone previous surgery on the turbinate or previous sphenopalatine artery ligation. Efficacy of the middle turbinate flap in large skull base defects and in posterior sellar defects cannot be substantiated.

## ACKNOWLEDGMENTS

We acknowledge the scientific review board and Ethical committee for granting necessary clearance for the study. We thank the Neurosurgery Department, Government medical college Kottayam for the kind referral of patients with skull base defects needing trans-nasal repair.

*Funding: No funding sources*

*Conflict of interest: None declared*

*Ethical approval: The study was approved by the Institutional Ethics Committee*

## REFERENCES

1. Hadad G, Bassagasteguy L, Carrau RL, Mataza JC, Kassam A, Snyderman CH, et al. A novel reconstructive technique after endoscopic expanded endonasal approaches: vascular pedicle nasoseptal flap. *Laryngoscope.* 2006;116:1882-6.
2. Reyes C, Mason E, Solares CA. Panorama of Reconstruction of Skull Base Defects: From Traditional Open to Endonasal Endoscopic Approaches, from Free Grafts to Microvascular Flaps. *Int Arch Otorhinolaryngol.* 2014;18(2):179-86.
3. Gras-Cabrerizo JR, Gras-Albert JR, Monjas-Canovas I, Garcia Garrigos, Montserrat Gilli JR, Sanchez Dell Campo, et al. Pedicle Flaps Based on the Sphenopalatine Artery: Anatomical and Surgical Study. *Acta Otorrinolaringol Esp.* 2014;65(4):242-8.

4. Prevedello DM, Barges-Coll J, Fernandez-Miranda JC, Morera V, Jacobson D, Madhok R, et al. Middle turbinate flap for skull base reconstruction: cadaveric feasibility study. *Laryngoscope.* 2009;119(11):2094-8.
5. Amin SM, Fawzy TO, Hagazy AA. Composite vascular pedicled middle turbinate flap for reconstruction of sellar defects. *Ann Otol Rhinol Laryngol.* 2016;125(9):770-4.
6. Julian JAS, Lloret PM, Ruiz-Valdepenas EC, Coll JB, Giner AB, Asuncion CB. Middle turbinate vascularized flap for skull base reconstruction after an expanded endonasal approach. *Acta Neurochirurgica.* 2011;153:1827.
7. Yip J, Macdonald KI, Lee J, Witterick IJ, Zadeh G, Gentili F, et al. The inferior turbinate flap in skull base reconstruction. *J Otolaryngol Head Neck Surg.* 2013;42(1):6.
8. Bhatki AM, Pant H, Snyderman CH, Carrau RL, Kassam AB, Prevedello DM, et al. Reconstruction of the cranial base after endonasal skull base surgery: Local tissue flaps. *Operative Tech Otolaryngol Head Neck Surg.* 2010;21(1):74-82.
9. Otto BA, Carrau RL, Prevedello DM, Old MO, Ditzel Filho LF, de Lara D, et al. Middle Turbinate Vascularized Flap: Applications in Skull Base Reconstruction. *J Neurol Surg B.* 2012;3:152.
10. Marks SC. Middle turbinate graft for repair of cerebral spinal fluid leaks. *Am J Rhinol.* 1998;12(6):417-9.
11. Wang X, Zhang X, Hu F, Gu Y, Xie T, Ge J. Middle turbinate mucosal flap in endoscopic skull base reconstruction. *Turkish Neurosurg.* 2016;26(2):200-4.
12. Bhatki AM, Carrau RL, Prevedello DM, Fernandez-Miranda JC, Snyderman CH, Gardner P, et al. The Posteriorly Pedicled Middle Turbinate Flap for Dural Reconstruction after Skull Base Surgery. *Skull Base.* 2009;19:53.
13. Patel MR, Stadler ME, Snyderman CH, Carrau RL, Kassam AB, Germanwala AV, et al. How to Choose? Endoscopic Skull Base Reconstructive Options and Limitations. *Skull Base.* 2010;20(6):397-404.
14. Nyquist GG, Anand VK, Brown S, Singh A, Tabaei A, Schwartz TH. Middle turbinate preservation in endoscopic transphenoidal surgery of the anterior skull base. *Skull base.* 2010;20(5):343-7.

**Cite this article as:** George S, Suresh S. Vascularized middle turbinate mucoperiosteal flap in skull base defects: follow-up analysis of 20 cases. *Int J Otorhinolaryngol Head Neck Surg* 2017;3:71-6.