

Review Article

Non invasive assessment of the frontal sinus: a review

Manish Munjal^{1*}, Sanjeev Puri¹, Anshu Soni², Vikramjit Kailey¹,
Navreen Pooni³, Shubham Munjal¹, Angad Harshbir Singh¹

¹Department of ENT HNS, ²Department of Anatomy, ³Department of Radiology, Dayanand Medical College, Ludhiana, Punjab, India

Received: 11 September 2020

Revised: 15 October 2020

Accepted: 16 October 2020

***Correspondence:**

Dr. Manish Munjal,

E-mail: manishmunjaldr@yahoo.com

Copyright: © the author(s), publisher and licensee Medip Academy. This is an open-access article distributed under the terms of the Creative Commons Attribution Non-Commercial License, which permits unrestricted non-commercial use, distribution, and reproduction in any medium, provided the original work is properly cited.

ABSTRACT

The Frontal sinus with its peculiar mucociliary drainage affected by pathology at the frontal recess necessitates an intervention, medical or surgical. Current review elaborates upon the role of basic imaging in pre treatment evaluation.

Keywords: Frontal sinus, Plain radiography, Computed tomography, Magnetic resonance imaging

INTRODUCTION

Radiography of the paranasal sinuses has been available since the early 1900s Reardon 2002.¹ Skull radiographs, computed tomography and magnetic resonance constitute the imaging studies which have a vital role in the prompt diagnosis and thus management of the frontal sinus pathologies.

REVIEW OF LITERATURE

Radiology of frontal sinus

In 1912 Mosher utilized a lateral radiograph while attempting to pass a probe into the frontal sinus.² In Water's or occipitomeatal view, the frontal sinuses are projected obliquely and their floors are clearly demarcated. In Caldwell's or occipitofrontal view, the frontal sinuses are also clearly visualized.³

The sinus is compartmentalized by the intrasinus septa and marginated by irregular bone. The loss of scalloped border, or the intrasinus septa, on plain radiographs indicates chronic infection as mentioned by Wigh et al.⁴

Radiographs of skull

Role of sinus radiographs is very controversial due to likelihood of false positive and false negative interpretations, particularly in infants and children. Normal sinuses are radiolucent; whereas diseased sinuses show varying degrees of opacity or a fluid level.⁵ Sinus radiographs are not reliable enough to be integral component of clinical decision-making process as they do not allow adequate evaluation of the disease of the frontal sinuses and the drainage pathways because of the overlapping structures. Lazar et al, Burke et al, Goldstein et al.⁶⁻⁸ The radiation exposure for Water's and lateral view radiographs is 40-60 mSv.² The paired sinuses are superimposed on each other, on lateral view but still the posterior table and extent of pneumatization can be determined.⁹

Evaluation of lateral head films

The lateral head films are oriented horizontally with the nasion sella line. The outer border of the frontal sinus is traced and the highest (SH) and lowest (SL) point of its extension is marked. Perpendicular to the interconnecting line SH-SL the maximum width of the frontal sinus is assessed as mentioned by Esturk et al.¹⁰ On the lateral

projection the paired sinuses are superimposed on one another and cannot, therefore be distinguished, indicated by MacKay and Lund.¹¹ The opacities or an air fluid level in the frontal sinus in plain radiographs of the paranasal sinuses are usually the result of disease processes in the frontal recess. Even with the extensive involvement of the frontal sinus the changes in the frontal recess appear to be slight and identified only by conventional tomography as reported by Stammler.¹²

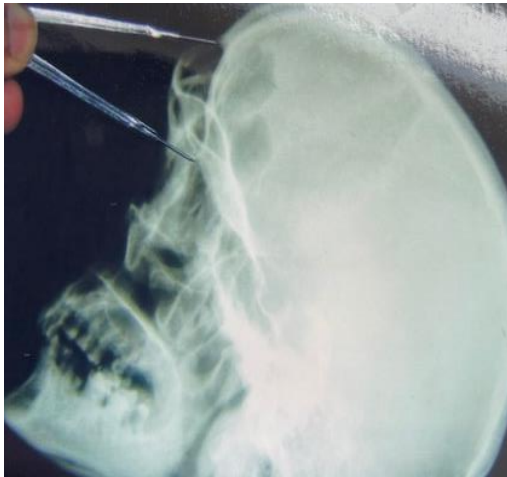

Figure 1: Plain radiograph lateral view skull, showing anterior and posterior frontal tables.

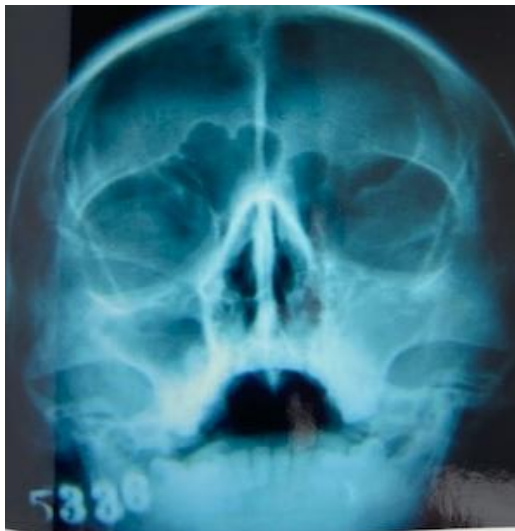

Figure 2: Caldwell's view showing lateral pneumatization of frontal sinuses.

Computed tomography (CT) and magnetic resonance imaging (MRI) of frontal sinus

Computed tomography and magnetic resonance imaging are the modalities of choice for delineating potential frontal malignancies, with arteriography reserved for the occasional highly vascular tumor. In general, malignancies erode bone, whereas benign

processes cause reactive thickening or remodeling of adjacent bone.¹³

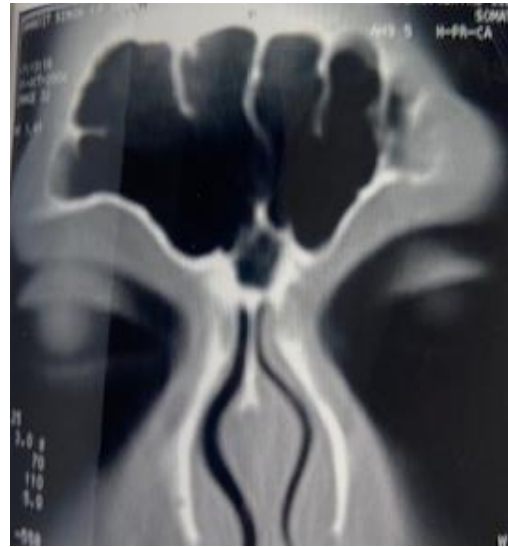

Figure 3: Coronal CT para-nasal sinuses showing scalloping in the well pneumatized frontal sinus.

CT is the most practical and cost-effective means to study the paranasal sinuses and assists in avoiding complications during surgery.¹⁴ Computed tomography scan is very reliable in demonstrating erosion of the bony sinus wall or perisinus extension.¹⁵ Over the years, it has established its place as the "investigation of choice" for evaluation of paranasal sinus pathology. In addition to evaluating the bony passages it also helps to demonstrate mucosal thickening, fluid or calcification in the sinuses. Soft tissues of the orbit and anterior cranial fossa can also be visualized.¹⁶

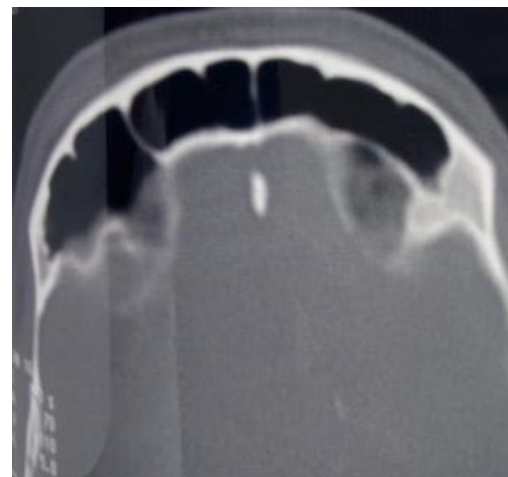


Figure 4: Axial CT paranasal sinuses showing septation in the frontal sinus.

Computed tomography of the frontal sinus is used to assess its: anatomical status; normal anatomy and anatomical variations, extent of pneumatization, presence

of agger nasi cells and its relation with vital structures, presence of congenital bony dehiscences, pathological status; delineation of pathology, site and extent, depth or invasion, details of mucosal abnormalities, possible cause of pathology, and most important probable cause of failure of surgery. It is considered ideal to have computed tomography sections in all the planes-coronal, axial and sagittal. Though technically it is difficult to get cuts in the sagittal plane, therefore formatted images are utilized.

Axial plane study of the frontal sinus

Axial computed tomographs clear up the misperception of the supraorbital pneumatization, which may appear to be continuous with the frontal sinus and also corroborates the frontal sinus septation seen on the coronal views. An axial section tells us the thickness of the anterior and posterior walls of the sinus, size of the sinus, number and position of septae, anatomical variations and surgical pathology if any.¹⁷

Thin axial section CT can be utilized to produce two-dimensional (sagittal or coronal) and three-dimensional reconstructions with new scanning modalities.¹⁸

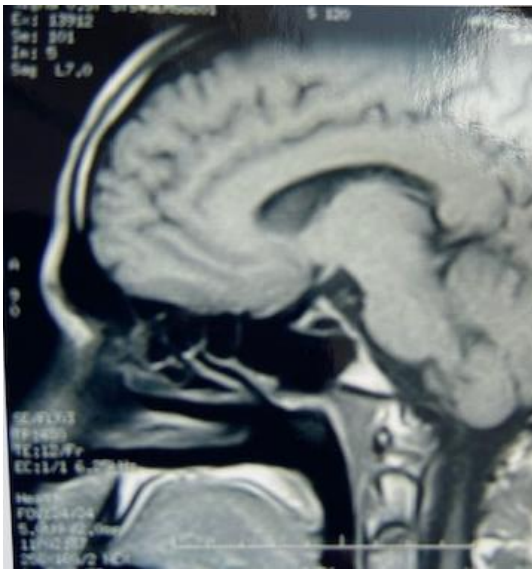


Figure 5: Sagittal view, MRI showing frontal sinus and drainage pathway.

Coronal plane study of the frontal sinus

It is the preferred plane for computed tomographic imaging prior to functional endoscopic sinus surgery because being synchronized with surgical steps; it serves as a guide (road map) to the endoscopist. The optimal technique consists of acquiring direct contiguous sections 3 mm thick in the coronal plane.¹⁹

Optimal detail is obtained by coronal and axial tomograms at 1.5 to 2 mm intervals with both, bone windows and soft tissue algorithms.²⁰ Tumours tend to have a soft tissue density on CT scans. Sinus secretions

have a lower density and with contrast secretions do not enhance unlike most tumors and inflamed mucosa.

The anatomic relationship of the agger nasi cell to the lacrimal fossa can be clearly demonstrated in the coronal views. Agger nasi cells lie below the level of frontal sinus and frontal recess and are located anterior to the attachment of middle turbinate.¹² The floor of the sinus is the thinnest wall and is formed by the roof of the orbit and slopes downwards and medially towards the frontal recess.²¹

Frontal cells on computed tomogram

The frontal cells are classified into four different types depending on their location.¹⁸ Type I; single frontal recess cell above the agger nasi cell, type II; tier of cells in frontal recess above agger nasi cell, type III; single massive cell pneumatizing cephalad into the frontal sinus, type IV; single isolated cell with in the frontal sinus the “loner cell”. Ethmoid configurations are classified on the basis of increasing length of ‘lateral lamellae.’²² Type I; lateral lamellae are short (1-3 mm). The olfactory fossa is shallow and the roof of the ethmoid is relatively even with the cribriform plate, type II; Lateral lamellae are longer (4-7mm in length), making the roof of the ethmoid significantly higher than the cribriform plate, type III; lateral lamellae are 8 to 16 mm long, the olfactory fossa is deep. The course from the roof of the ethmoid to the cribriform plate is quite steep. The upper border of ethmoid sinuses is known as fovea ethmoidalis. Height of the fovea can also be measured using foveal plane and foveal angle.²³ Foveal plane is a horizontal plane passing through the junction of the fovea with the medial orbital walls. High foveal plane; passing through the upper one third of the orbit, mid foveal plane: passing through the middle portion of the orbit, low foveal plane; lying below the mid orbital plane.

Foveal angle is the angle between the fovea and the lamina papyracea. Ideally a postoperative patient should be followed with coronal computed tomography to establish the type and extent of surgical intervention. The sinus boundaries and important anatomic relationship should be inspected particularly for any bony dehiscence or development of a cephalocele.

Sagittal plane study of the frontal sinus

Sagittal reformations are helpful in better defining the drainage pathway of the frontal sinus and frontal recess.

A true sagittal computed tomographic section is difficult to obtain, as it requires awkward positioning of the patient therefore sagittal reconstruction from the coronal scan acquisition is performed. 1.5 mm sections at 1.5 mm spacing are obtained.²⁴ Computed tomographic scanning for image guided surgery is used nowadays, thus minimizing the risk of operative complications in endoscopic sinus surgery. Computed tomographic scan is

very reliable in demonstrating bony sinus wall erosion or perisinus extension.¹⁵ Bone erosion is generally produced by malignant tumors but can also be seen with large expansile mucocoeles. Extra-cranial extension is a hallmark of malignant disease. It may represent a primary sinus tumor, a metastatic lesion or extension of an intracranial neoplasm.²⁵ Disadvantages of computed tomographic scanning include higher expenses, higher radiation dose and interference by artifacts such as extensive dental fillings.²⁶

Magnetic resonance imaging

MRI gives excellent delineation of soft tissues lesions and important structures adjacent to frontal sinuses, such as the orbit and anterior cranial fossa. All though it cannot differentiate usually between benign and malignant processes.²⁷ Inflamed mucosa, polyps and non-inspissated secretions with high water content have increased signal intensity on T2 weighted images whereas neoplasms have intermediate signal intensity.²⁸ Some sino-nasal malignancies, like minor salivary gland tumors, schwannomas, and haemangiomas, exhibit high signal intensity on T2 weighting.

Magnetic resonance imaging contrast enhanced with gadolinium is preferred for post-therapy assessment of frontal sinus malignancies.¹³ Magnetic resonance imaging is superior to computed tomographic scanning in differentiating tumor from the adjacent inflammatory sinus disease if complications of sinusitis or a neoplasm is suspected, the study of choice is contrast enhanced magnetic resonance imaging. Other advantages of MRI are; multiplanar capability, superior soft tissue contrast and lack of ionizing radiations.

The standard protocol for magnetic resonance imaging of paranasal sinuses is T1 weighted images in the sagittal, axial, and coronal planes and T2 weighted images in the axial plane. T1 weighted images assess anatomy; T2 weighted images assess disease brighter signal is produced by fluid containing structures whereas a lower signal is produced by malignant tumors.

Disadvantages of magnetic resonance imaging are; time consumed in scanning is about 30-45 minutes as compared to computed tomographic scan, which takes approximately 15 mins, more noisy and confining than computed tomographic scan and therefore claustrophobic patients are difficult to assess and the bony margins of the sinuses appear as a plane of absent signal on magnetic resonance imaging.¹²

Magnetic resonance imaging is not a reliable operative road map to guide the surgeon during functional endoscopic sinus surgery.²⁷ Singh et al listed the disadvantages of a magnetic resonance imaging scan; more expensive, more time consuming and bony detail not well delineated.¹⁷

The bony demarcation of the sinuses appears as a plane of absent signal on magnetic resonance imaging. Therefore, it is not a reliable road map to guide the surgeon during functional endoscopic sinus surgery.²⁸

CONCLUSION

Vis a vis imaging is the road map to the, functional endoscopic sinus surgery of the frontal sinus.

Funding: No funding sources

Conflict of interest: None declared

Ethical approval: Not required

REFERENCES

1. Reardon EJ. Navigational risks associated with sinus surgery and the clinical effects of implementing a navigational system for sinus surgery. *The Laryngoscope.* 2002;112(S99):1-9.
2. Mosher H. The applied anatomy and the intranasal surgery of the ethmoidal labyrinth. *Trans Am Laryngol Assoc.* 1912;34:25-39.
3. Scot-Brown WG. *Scott-Brown's Otolaryngology*, 6th ed. United States: CRC press; 1997;5-6.
4. Wigh R. Mucocoeles of the froto-ethmoid sinuses. *Radiology.*1950;54:579-90.
5. Warwick W. *Gray's anatomy.* 37th ed. London: Churchill Livingstone; 1989.
6. Lazar RH, Younis RT, Long TE. Functional endoscopic sinus surgery in adults and children. *Laryngoscop.*1993;103:1-5.
7. Burke TF, Guertler AT, Timmons JH. Comparison of sinus X-rays with computed tomography scans in acute sinusitis. *Acad Emerg Med.* 1994;1(3):235-9.
8. Goldstein JH, Philips CD. Current indications and techniques in evaluating inflammatory disease and Neoplasia of the sinonasal cavities. *Curr Probl Dagn Radio.* 1998;27:41-71.
9. Phelps PD. Radiology in paediatric otolaryngology. *Scott-Brown's otolaryngology.* 6th ed. United States: CRC press; 1997;23.
10. Ruf S, Pancherz H. Development of the frontal sinus in relation to somatic and skeletal maturity. A cephalometric roentgenographic study at puberty. *The European Journal of Orthodontics.* 1996 Jan 1;18(1):491-7.
11. Mackay IS, Lund VJ. Surgical management of sinusitis. *Scott-Brown's otolaryngology.* 6th ed. United States: CRC press; 1997;29.
12. Stammberger H. The evolution of functional endoscopic sinus surgery. *Ear Nose Throat J.* 1994; 73(7):454-5.
13. Mosesson RE, Som PM. The radiographic evaluation of sinonasal tumors: an overview. *Otolaryngol Clin North Am.* 1995;28(6):1097-115.
14. Maffee MF. Nonepithelial tumours of the paranasal sinuses and nasal cavity. *Radiol Clin North Am.* 1993;31:75-90.

15. Pearlman SJ, Lawson W, Biller HF, Friedman WH, Potter GD. Isolated sphenoid sinus disease. *Laryngoscope.* 1989;99:716-20.
16. Smith TL, Han JK, Loehrl TA, Rhee JS. Endoscopic management of the frontal recess in frontal sinus fractures: a shift in the paradigm?. *The Laryngoscope.* 2002 May;112(5):784-90.
17. Lloyd GA. Magnetic resonance imaging of the nose and paranasal sinuses. *Journal of the Royal Society of Medicine.* 1989 Feb;82(2):84-7.
18. Bent JP, Cuijly-Sillers C, Kuhn FA. The frontal cell as a cause of frontal sinus obstruction. *Amer J Rhinology.* 1994;8:185-91.
19. Kennedy DW, Bolger WE, Zinreich SJ. Diseases of the sinuses: diagnosis and management. United states: PMPH-USA; 2001.
20. Parsons JT, Kimsey FC, Mendenhall WM, Million RR, Cassisi NJ, Stringer SP. Radiation therapy for sinus malignancies. *Otolaryngol Clin North Am.* 1995;28(6):1259-68.
21. Lawson W. Frontal sinus. In: Blitzer A, Lawson W, Friedman WH, eds. *Surgery of the paranasal sinuses.* Philadelphia: WB Saunder; 1985:120.
22. Keros P. Uber die praktische bedeutung der nivea uunter-schiede der lamina cribrosa des ethmoids. *Laryngorhinootologic.* 1965;41:808-13.
23. Meyers RM, Valvassori G. Interpretation of anatomic variations of computed tomography scans of the sinuses: a surgeon's perspective. *The Laryngoscope.* 1998;108(3):422-5.
24. Bhatt NJ. *Endoscopic sinus surgery new horizons.* 1st ed. Karachi: Singular group; 1997.
25. Lawson W, Reino AJ. Isolated sphenoid sinus disease: an analysis of 132 cases. *The Laryngoscope.* 1997;107(12):1590-5.
26. Stammberger H, Hawke M. *Essentials of endoscopic sinus surgery.* United States: Mosby; 1993.
27. Zinreich SJ. Functional anatomy and computed tomography imaging of the paranasal sinuses. *Am J Med Sci.* 1998;316(1):2-12.
28. Oliverio PJ, Zinreich SJ. *Otolaryngology head and neck surgery.* 3rd ed. United States: Mosby; 1998.

Cite this article as: Munjal M, Puri S, Soni A, Kailey V, Pooni N, Munjal S, et al. Non invasive assessment of the frontal sinus: a review. *Int J Otorhinolaryngol Head Neck Surg* 2020;6:2150-4.