

Case Report

Ossifying pleomorphic adenoma presenting as a nasopalatine mass

Vikram K. Bhat*, Supreetha B. Shenoy, Bhavana Sangoli

Department of ENT, Karnataka Institute of Medical Sciences, Hubli, India

Received: 28 November 2016

Accepted: 23 December 2016

***Correspondence:**

Dr. Vikram K. Bhat,

E-mail: vikram.ent@gmail.com

Copyright: © the author(s), publisher and licensee Medip Academy. This is an open-access article distributed under the terms of the Creative Commons Attribution Non-Commercial License, which permits unrestricted non-commercial use, distribution, and reproduction in any medium, provided the original work is properly cited.

ABSTRACT

Pleomorphic adenomas are benign tumors that are uncommon in the nasal cavity. However, they can rarely arise from septum, erode hard palate and thus masquerade a bone tumor. We report one such rare case of septal pleomorphic adenoma with hard palatal extension and ossification. A combined endoscopic intranasal and transpalatal surgical approach was performed and tumor was excised completely. A high index of clinical suspicion and biopsy can diagnose such swellings.

Keywords: Pleomorphic adenoma, Salivary glands minor, Salivary gland neoplasm

INTRODUCTION

Pleomorphic adenoma is a frequent benign neoplasm in the head and neck region and accounts for 70% of all salivary gland tumors.¹ A small minority (8%) are located in the oral cavity, neck and nasal cavity.¹ Mostly, these tumors are benign, and only 1% are seen in the nasal cavity or epipharynx.² The usual age of occurrence is between third to sixth decades of life.³ Few studies state slight female predilection of this tumor.¹ Among all reported cases of pleomorphic adenomas in the nasal cavity, 80% arose from the mucosa of cartilaginous or bony septum and only 20% originated from the lateral nasal wall.³

CASE REPORT

A 17 year old female presented with mass in the oral cavity for 8 years that was insidious in onset and gradually increased in size. There was no associated pain or bleeding from the mass. Also the patient had no nasal complaints.

On examination of the oral cavity there was a solitary pinkish red smooth mass measuring 3x2x1cm in the

midline of hard palate extending more towards right which had a hard periphery and soft center [Figure 1]. Anterior rhinoscopy revealed a smooth bulge at the junction of septum and the floor in the right nasal cavity.

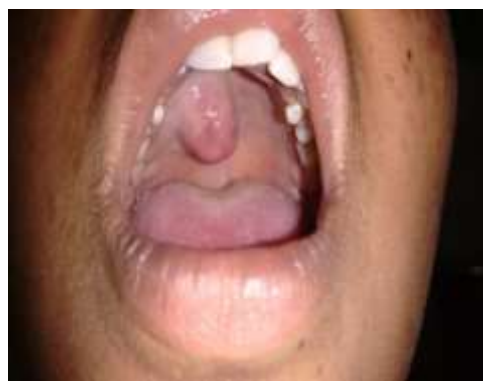

Figure 1: Hard palate mass.

Diagnostic nasal endoscopy confirmed the nasal mass that appeared to arise from the bony cartilaginous junction of septum on both sides of the nasal cavity, right [Figure 2a] more than the left [Figure 2b].

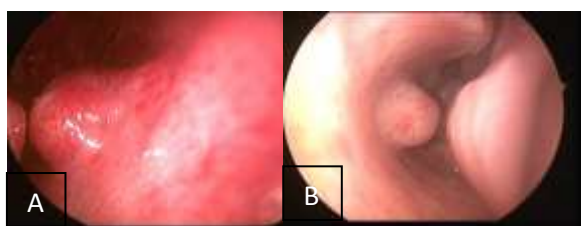


Figure 2: Nasal mass on either sides of septum (a) right, (b) left.

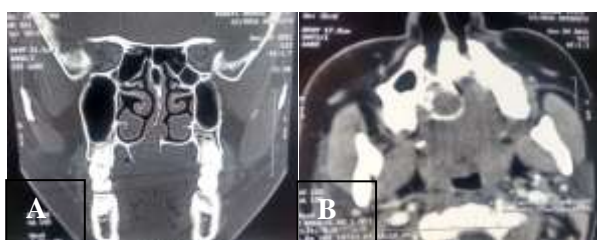


Figure 3: CT PNS coronal (3a) and axial cuts (3b) with palatal defect and peripheral calcification.

CT of paranasal sinuses showed well defined soft tissue density lesion measuring 21x17x15 mm involving the midline posterior hard palate and nasal septum [Figure 3a, b]. There was peripheral calcification of the mass and a defect in the maxillary crest. FNAC and incisional biopsy were done from the intraoral route that suggested pleomorphic adenoma.

A combined endoscopic intranasal and transpalatal surgical approach was chosen and tumor was excised completely. A part of septal cartilage was also excised and the bony rim in the hard palate was removed with microdrill. The defect was closed primarily by elevation and suturing of palatal mucosal flaps and further supported by a palatal obturator to prevent a fistula. Histopathological examination of excised specimen showed clusters of epithelial cells and myoepithelial cells with myxoid stroma features once again suggestive of pleomorphic adenoma.

Postoperative follow up of 6 months did not show any recurrence of the tumor.

DISCUSSION

Pleomorphic adenomas are mixed salivary gland tumors with epithelial, myoepithelial cells and stromal components and are most commonly found in parotid gland. However, among minor salivary glands hard palate is the most common site. Minor salivary glands are also found in the nasal cavity i.e, in septum and lateral nasal wall. Literature states that pleomorphic adenomas arise rarely from the nasal cavity.² Also involvement of the surrounding structures such as bone is rare since the tumors have sufficient space to expand within the nasal cavity.⁴

Core biopsy is more invasive but is more accurate compared to FNAC with diagnostic accuracy greater than 97%.⁵ Fine needle aspiration cytology and incisional biopsy can aid in the diagnosis of pleomorphic adenoma.⁶

CT is superior to MRI in evaluating bone, especially in diagnosing erosion and perforation of the bony palate and possible involvement of the nasal cavity or maxillary sinus.⁷

The morphology of the tumor in our case was rather unusual and is a matter of debate. It appeared as though the tumor arose from the bony septum and then descended to the hard palate. Instead of expanding in the roomy nasal cavity, it chose to erode the thick bone of hard palate in a circumferential manner causing a full thickness defect as if there was some affinity for bone. A bony collar was then formed around the palatal defect suggesting incomplete osteolysis and osteoneogenesis due to osteoid formation as revealed by the CT scan. This led to the impression of a bone tumor. There has been no report in literature of this kind of unusual palatal invasion from nasal septal pleomorphic adenoma cases until now to the best of our knowledge. Only 1 case of septal pleomorphic adenoma with calcification and ossification has been reported in the literature so far.⁸

Treatment of palatal pleomorphic adenoma involves wide local excision of tumor including its surrounding capsule, together with clear margins involving the periosteum and associated mucosa, followed by curettage of the underlying bone with a sharp spoon or burr under copious sterile normal saline irrigation, to avoid recurrence.⁸

CONCLUSION

Pleomorphic adenomas are benign tumors that rarely arise from septum with hard palate involvement. Bone erosion and new bone formation is unique in our case. The clinical presentation can be misleading when the tumors are disproportionate and do not grow and expand in the expected path of least resistance thereby delaying the proper diagnosis. They can masquerade a hard palate bone tumor especially when they violate the common pathway of tumor extension and spread.

In such cases, a high index of clinical suspicion and biopsy can diagnose these swellings. These tumors are best managed by combined transnasal and transpalatal approaches for resection.

Funding: No funding sources

Conflict of interest: None declared

Ethical approval: Not required

REFERENCES

1. Gana P, Masterson L. Pleomorphic adenoma of the nasal septum: A case report. J Med Case Rep. 2008;2:349.

2. Kumagai M, Endo S, Koizumi F, Kida A, Yamamoto M. A case of pleomorphic adenoma of the nasal septum. *Auris Nasus Larynx.* 2004;31:439-42.
3. Compagno J, Wong RT. Intranasal mixed tumors (pleomorphic adenomas): A Clinicopathologic Study of 40 cases. *Am J Clin Pathol.* 1997;68:213-8.
4. Avishay G, Yudith B, Fradis M. Pleomorphic nasoseptal adenoma. *J Otolaryngol.* 1997;26(6):399-401.
5. Clauser L, Mandrioli S, Dallera V, Sarti E, Galiè M, Cavazzini L. Pleomorphic adenoma of the palate. *J Craniofac Surg.* 2004;15(6):1026-9.
6. Rahnama M, Orzedala-Koszel U, Czupkallo L, Łobacz M. Pleomorphic adenoma of the palate: a case report and review of the literature. *Contemp Oncol (Pozn).* 2013;17(1):103-6.
7. Patigaroo SA, Patigaroo FA, Ashraf J, Mehfooz N, Shakeel M, Khan NA, et al. Pleomorphic Adenoma of Hard Palate: An Experience. *J Maxillofac Oral Surg.* 2014;13(1):36-41.
8. Singhal A, Yadav A, Yadav RC, Kukreja HK. Pleomorphic Adenoma of the Nose. *Indian Journal of Otolaryngology.* 1989;41(1):37-8.

Cite this article as: Bhat VK, Shenoy SB, Sangoli B. Ossifying pleomorphic adenoma presenting as a nasopalatine mass. *Int J Otorhinolaryngol Head Neck Surg* 2017;3:459-61.