

Original Research Article

Surgical alternative to tracheoesophageal prosthesis for voice preservation in selected hypopharyngeal carcinoma

Neena Chaudhary, Shweta Jaitly, Rajeev Kumar Verma*, Shashank Gupta, Para Chaudhary

Department of Otorhinolaryngology, VMMC and Safdarjung Hospital, New Delhi, India

Received: 26 July 2020

Revised: 09 September 2020

Accepted: 11 September 2020

*Correspondence:

Dr. Rajeev Kumar Verma,

E-mail: drrajeevkumar85@gmail.com

Copyright: © the author(s), publisher and licensee Medip Academy. This is an open-access article distributed under the terms of the Creative Commons Attribution Non-Commercial License, which permits unrestricted non-commercial use, distribution, and reproduction in any medium, provided the original work is properly cited.

ABSTRACT

Background: Pearson's near-total laryngectomy (NTL) is a voice-preserving alternative to total laryngectomy in patients with advanced but localized laryngeal and hypopharyngeal cancers, wherein lung-powered speech is achieved by creation of a dynamic biological trachea-pharyngeal shunt. Report our experience with NTL in a series of 24 patients.

Methods: A prospective case series analysis was done at VMMC and Safdarjung Hospital from January 2014-September 2019 after attaining ethical clearance. Twenty-four patients with lateralized, locally advanced hypopharyngeal carcinoma, not involving interarytenoid and post-cricoid areas were included in the study. Patients who had involvement of the post cricoid region, interarytenoid region or involvement of bilateral cricoarytenoid units were excluded from the study. The subjects underwent Pearson's NTL and were followed-up to examine for disease-control and functional results.

Results: 22 patients (91.6%) attained a good quality voice following surgery with 2 patients (8.3%) developing minor aspiration problems. 1 patient (4.16%) developed local recurrence after 5 months. Surgical complications were surgical site infection (20.8%), pharyngocutaneous fistula (16.67%) and shunt stenosis (4.16%).

Conclusion: NTL is an oncologically safe alternative to total laryngectomy in selected patients and is capable of achieving excellent functional results with minimal surgical complications and post-operative maintenance.

Keywords: NTL, Laryngectomy, Hypopharynx, Voice preservation, Tracheoesophageal prosthesis

INTRODUCTION

Concurrent chemoradiation has emerged as the 'standard of care' in the management of laryngeal and hypopharyngeal cancers.¹ However, for patients who are not suited for chemoradiation, total laryngectomy continues to be the treatment of choice. Total laryngectomy is associated with a permanent loss of voice, necessitating a tracheoesophageal prosthesis (TEP) for speech restoration. Although TEP has a high success rate of 90 percent, it is associated with serious limitations, which significantly hamper a patient's quality of life.²⁻⁴

Pearson et al, in 1980, described a voice preserving procedure called 'extended hemilaryngectomy', which after serial modifications, came to be known as NTL.⁵ From a surgical point of view, NTL resembles total laryngectomy more than it resembles a partial laryngectomy, and the patient is left with a permanent tracheostome at the end of the procedure. In patients who meet the selected criteria for the procedure, the entire larynx is resected except for a narrow postero-lateral strip connecting the trachea to the pharynx, and this strip functions as a dynamic tracheopharyngeal shunt responsible for preserving the patient's voice. NTL compares with total laryngectomy in terms of disease

clearance, with the added advantage of voice preservation through natural means.

The purpose of this study is to narrate the experience with NTL in a series of twenty-four patients, emphasize the functional results following the procedure, highlighting its various advantages over total laryngectomy and TEP.

METHODS

A prospective case series analysis was done at VMMC and Safdarjung Hospital from January 2014- September 2019 after attaining ethical clearance. Twenty-four patients with lateralized, locally advanced hypopharyngeal carcinoma, not involving interarytenoid and post- cricoid areas were included in the study. Patients who had involvement of the post cricoid region, interarytenoid region or involvement of bilateral cricoarytenoid units were excluded from the study. The subjects underwent Pearson’s NTL and were followed-up to examine for disease- control and functional results

Staging was done using a Contrast- Enhanced CT scan and a histological diagnosis established by a pre-operative direct laryngoscopic biopsy. None of the patients received pre- operative chemoradiation.

All patients underwent NTL according to the technique described by Pearson with ipsilateral neck dissection (steps highlighted in figures 1-3).⁵ The resected specimen is shown in Figure 4. At the end of the first post-operative week, oral intake was initiated and the first attempt at phonation was made when the sutures were removed (day 7-10). Adjuvant radiotherapy was administered to all twenty-four patients following surgery. The patients were regularly followed-up for a mean duration of twenty-eight months and thoroughly evaluated for disease recurrence, voice outcome, aspiration and other complications. Aspiration was graded according to the system described by Leipzig (Table 1), and phonation graded as per the grading system laid down by Aslan et al in their study (Table 2).^{6,7}

Table 1. The scaling system for functional evaluation of patients for aspiration.

Degree of aspiration	Description	No. of patients (%)
0	No aspiration	22 (91.67)
1 st	Minimum aspiration; the patient is not aware of it	0
2 nd	Aspiration exists; the patient is aware of it	2 (8.3)
3 rd	Aspiration is severe; the patient suffers from it	0
4 th	Complications of aspiration (weight loss, aspiration pneumonia)	0

Table 2: The scaling system for functional evaluation of patients for phonation.

Degree of phonation	Description	No. of patients (%)
0	No phonation	2 (8.3)
1 st	Patient phonates strenuously but cannot speak	0
2 nd	Patient is able to speak with strenuous effort	0
3 rd	Patient speaks without difficulty but is hard to understand in a noisy environment	6 (25)
4 th	Patient speaks easily and is intelligible in a noisy environment	16 (66.6)

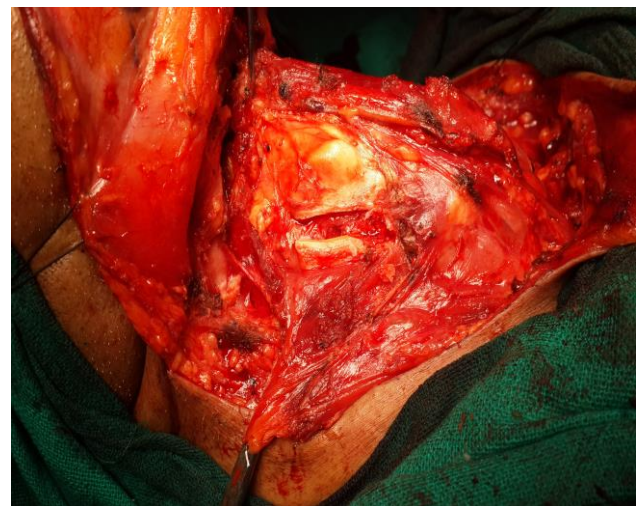


Figure 1: Creation of window in thyroid and cricoid cartilage on uninvolved side.

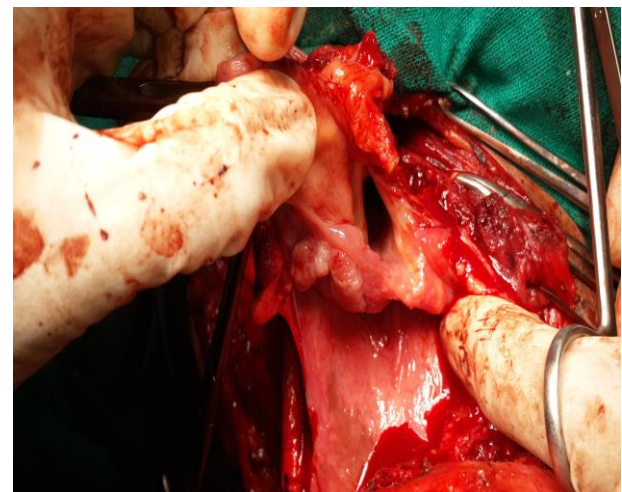


Figure 2: Trans vallecular entry followed excision of tumor while preserving one cricoarytenoid unit.

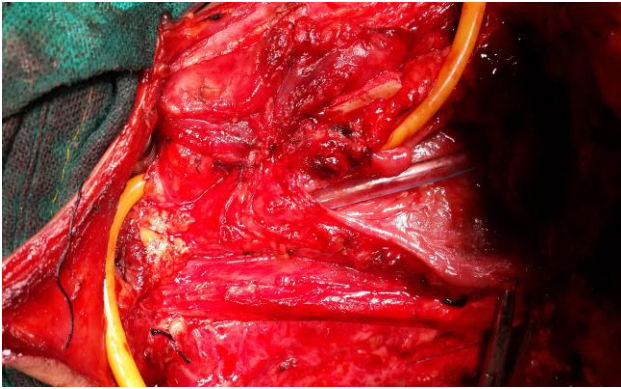


Figure 3: Foley's catheter 14F was used for creation of myomucosal shunt followed by neopharyngeal reconstruction over neoglottis.

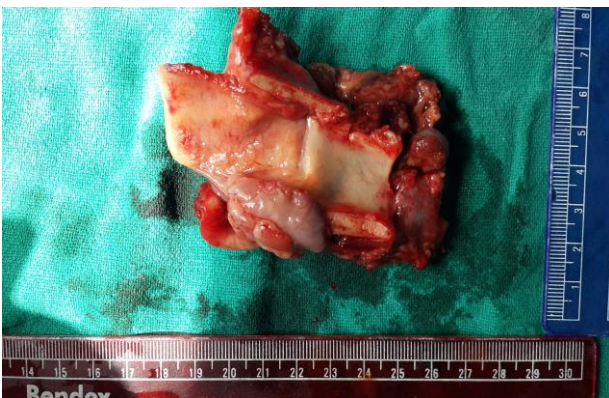

Figure 4: Resected specimen, growth in left pyriform sinus.

RESULTS

All 24 patients in the study were male aged between 50 and 70 years. All 24 patients were identified to have the primary lesion in the pyriform fossa. 15 (62.5 %) of these patients were staged T3 and 9 patients (39.1%) were staged to have T4a disease. 10 (43.4%) patients were found to have palpable cervical lymph nodes at presentation. Histological examination of the resected specimen revealed squamous cell carcinoma in all 24 patients with 15 of them showing tumor deposits in the cervical lymph nodes excised.

23 patients (95.8%) continued to be disease-free during the period of follow-up (mean duration- 28 months). 1 patient (4.16%) developed local recurrence 5 months after surgery for which he received adjuvant chemoradiation. 22 patients (91.6%) successfully achieved lung-powered speech falling under grade 3 (25%) and 4 (66.6%) as per the grading system described above, with the mean phonation time being 21 days. Minimal aspiration (2nd degree) was noted in 2 patients (8.33%). The most common early post-operative complication in our study was surgical site infection that developed in 5 patients (20.8%) and was managed with IV antibiotics. 4 patients (16.6%) developed a

pharyngocutaneous fistula which healed following conservative treatment and patients could successfully be started on oral diet. 1 patient (4.16%) developed shunt stenosis after radiotherapy.

DISCUSSION

Patients with advanced cancers of the larynx or hypopharynx have traditionally undergone total laryngectomy. Surgery was usually followed by voice rehabilitation using TEP which was simplified and popularized by Singer and Blom in 1980.⁸ NTL is a voice preserving surgery that is comparable to total laryngectomy in terms of oncological safety.^{11,15}

In NTL, the laryngeal tissue spared is used to create a dynamic tracheo-oesophageal speaking shunt that functions as a neo-glottis. It enables lung-powered voice during expiration and because of its myomucosal innervation (dynamic shunt), functions as a sphincter to prevent aspiration.⁷ The voice quality is as good if not better than that with a TEP.⁹

For TEP to achieve the desired function, the patient needs to know what the TEP is and how it works, requiring prolonged sessions with a speech pathologist. In addition, the economic costs of TEP should also be taken into consideration since it requires frequent replacement because of fungal ingrowths.⁷ Also, TEP causes tracheal and pharyngeal irritation, resulting in a disturbing cough.¹⁴ In comparison, NTL provides a permanent, biological shunt that requires no stent material, no maintenance or replacement, and no frequent hospital visits, reducing the overall cost of treatment. Also, postoperative radiotherapy does not have any corruptive effects on deglutitive function and phonation after NTL.¹¹ Therefore, radiation therapy can be initiated in the early postoperative period.¹⁰

In the experience, oncologically safe resection with adequate margins could be achieved in all cases. The rate of speech acquisition was 91.6% with good quality of speech (grades 3 and 4), which is comparable to the Mayo clinic experience.¹¹ On objective analysis of speech using voice analysis software, strong evidence for the superiority of quality of speech attained with biological shunt over TEP has been laid down in literature, with results approaching those for normal voice.¹ Satisfactory phonation following NTL even after radiotherapy has been reported by Terris et al.¹² The results were in concordance with theirs as all our patients had an intelligible voice after radiotherapy except one who developed shunt stenosis.

The results with respect to aspiration were encouraging as only 2 of patients (8.3%) developed minor aspiration problems, similar to Pearson's results (9%).¹¹ Both of these patients could be managed using various techniques of behavioural therapy. The most frequent complication following surgery in our study was surgical site infection,

which could be successfully treated with intravenous antibiotics. The rate of pharyngocutaneous fistula reported in literature ranges from 53% to 8.7%.^{13,14} In the study, 16.6% of the patients (n=4) developed this complication and all of them could be managed conservatively without the need for surgical intervention.

Limitations

A relatively smaller sample size was the limitation of this study.

CONCLUSION

NTL is an oncologically safe, voice preserving procedure for patients of advanced, but lateralized laryngeal and hypopharyngeal cancers and should be considered as a suitable alternative to total laryngectomy in such cases. It is capable of achieving excellent functional outcome with minimal surgical complications and no added discomforts of a voice prosthesis.

Funding: No funding sources

Conflict of interest: None declared

Ethical approval: The study was approved by the Institutional Ethics Committee

REFERENCES

1. D'Cruz AK, Sharma S, Pai PS. Current status of near-total laryngectomy: Review. J Laryngol Otolaryngol. 2012;126(06):556-62.
2. Silver CE. Surgery for cancer of the larynx and related structures. New York: Churchill Livingstone, 1981.
3. Müller R, Paneff J, Köllner V, Koch R. Quality of life of patients with laryngeal carcinoma: a post-treatment study. Eur Arch Otorhinolaryngol. 2001;258:276-80.
4. Gates GA, Ryan W, Cooper JC Jr, Lawlis GF, Cantu E, Hayashi T et al. Current status of laryngectomy rehabilitation: I. Results of therapy. Am J Otolaryngol. 1982;3:1-7.
5. Pearson BW, Woods RD, Hartman DE. Extended hemilaryngectomy for T3 glottic carcinoma with preservation of speech and swallowing. Laryngoscope. 1980;90:1950-61.
6. Leipzig B. Neoglottic reconstruction following total laryngectomy: A reappraisal. Ann Otol Rhinol Laryngol. 1980;89:534-537.
7. Aslan I, Baserer N, Yazicioglu E, Biliciler N, Hafiz G, Tinaz M et al. The functional and oncologic effectiveness of near-total laryngectomy. Am J Otolaryngol. 2002;23(4):196-202.
8. Singer MI, Blom ED. An endoscopic technique for restoration of voice after total laryngectomy. Ann Otol Rhinol Laryngol. 1980;89:529-33.
9. Pai PS, Pradhan SA. Near-total Laryngectomy. Otorhinolaryngology Clinics. Int J. 2010;247-52.
10. Aslan I, Baserer N, Yazicioglu E, Oysu C, Tinaz M, Kiyak E, et al. Near-total laryngectomy for laryngeal carcinomas with subglottic extension. Arch Otolaryngol Head Neck Surg. 2002;128:177-80.
11. Pearson BW, De Santo LW, Olsen KD, J R Salassa. Results of near-total laryngectomy. Ann Otol Rhinol Laryngol. 1998;107(10-1):820-5.
12. Terris DJ, Fee WE Jr, Goffinet DR. Potential success of near-total laryngectomy despite postoperative radiation therapy. Laryngoscope. 1996;106:1152-6.
13. Kavabata NK, Silva Neto AL, Gonçalves AJ, Alcadipani FA, Menezes MB. A nine-year institutional experience with near-total laryngectomy. Am J Surg. 2004;188:111-14.
14. Pradhan SA, D'Cruz AK, Pai PS, Mohiyuddin A. Near-total laryngectomy in advanced laryngeal and pyriform cancers. Laryngoscope. 2002;112:375-80.
15. DeSanto LW, Pearson BW, Olsen KD. Utility of near-total laryngectomy for supraglottic, pharyngeal, base of tongue and other cancers. Ann Otol Rhinol Laryngol. 1989;8:2-7.

Cite this article as: Chaudhary N, Jaitly S, Verma RK, Gupta S, Chaudhary P. Surgical alternative to tracheoesophageal prosthesis for voice preservation in selected hypopharyngeal carcinoma. Int J Otorhinolaryngol Head Neck Surg 2020;6:1850-3.