

Case Report

Chondroid syringoma of the upper lip: a rare entity

Ashiya Goel¹, Aman^{2*}, Vinny Raheja¹, Manisha Kumari³

¹Department of Otorhinolaryngology, Pt. B.D. Sharma PGIMS, Rohtak, Haryana, India

²Department of Otorhinolaryngology, Maharaja Agrasen Medical College, Agroha, Haryana, India

³Department of Anaesthesiology, Pt. B.D. Sharma PGIMS, Rohtak, Haryana, India

Received: 22 July 2020

Accepted: 05 September 2020

*Correspondence:

Dr. Aman,

E-mail: amanjakhar03022000@gmail.com

Copyright: © the author(s), publisher and licensee Medip Academy. This is an open-access article distributed under the terms of the Creative Commons Attribution Non-Commercial License, which permits unrestricted non-commercial use, distribution, and reproduction in any medium, provided the original work is properly cited.

ABSTRACT

Chondroid syringomas are uncommon cutaneous neoplasms of sweat gland origin which are slow-growing, nontender, subcutaneous or intracutaneous in location and often occurring in the head and neck region. Chondroid syringoma should be considered in the differential diagnosis of any subcutaneous nodule over the face. The clinician may miss the diagnosis of this lesion and if it is suspected, tumour should be excised with a margin of normal tissue and regular follow up should be done.

Keywords: Cutaneous, Syringoma, Lip, Chondroid

INTRODUCTION

Chondroid syringomas are rare, mixed skin tumours originating from the sweat glands. They have a very low incidence of only 0.01%-0.098%.¹ These tumours predominantly involve the head and neck region, although trunk and to a lesser extent extremity may also be affected. The commonest sites of presentation in the head and neck include nose, cheek, upper lip, scalp and chin respectively.² It most frequently manifests in middle aged and elderly males.

Billroth in 1859 first introduced mixed skin tumours.³ The term chondroid syringoma was coined by Hirsch and Helwig in 1961.⁴ Chondroid syringomas are usually benign, although a few malignant cases have also been reported. These mostly present as slow growing, nontender, firm, intradermal or subcutaneous nodules with surgical excision being the treatment of choice. Very few cases of chondroid syringoma are reported in literature. In this case report, we are reporting a rare case of chondroid syringoma of upper lip in a young male.

CASE REPORT

A 23 years old male presented to Ear, neck and throat (ENT) Department with a swelling over the upper lip since 6 months which was insidious in onset and gradually progressive in nature. On examination, a firm, lobulated, nontender mass of size about 1.5×1 cm was localised over the upper lip just lateral to the philtrum on the right side (Figure 1). The overlying skin was slightly shiny and erythematous. It was adherent to the skin without involvement of the underlying muscle or mucosa. On everting the lip, the mass could be visualized indenting the mucosal surface of the lip. No regional lymphadenopathy could be palpated. Ultrasonography revealed a heterogenous iso to hypoechoic lesion with thick internal echoes and well-defined margins measuring 15.5×9.5 mm, indicating a benign pathology (Figure 2). Colour doppler showed vascularization of intervening septae. On fine needle aspiration cytology, clusters of benign epithelial cells having round to oval nuclei, uniform chromatin and moderate to abundant eosinophilic cytoplasm were present. Few fragments of stroma were also seen.

The mass was excised under local anaesthesia with a rim of normal tissue. Histopathological examination showed a lobulated mass with chondroid and myxoid stroma with epithelial and myoepithelial cells within lobules and nests (Figure 3 and 4). Necrosis and mitosis were absent. These findings were suggestive of chondroid syringoma. Patient was kept on follow up for 18 months and no recurrence was observed.

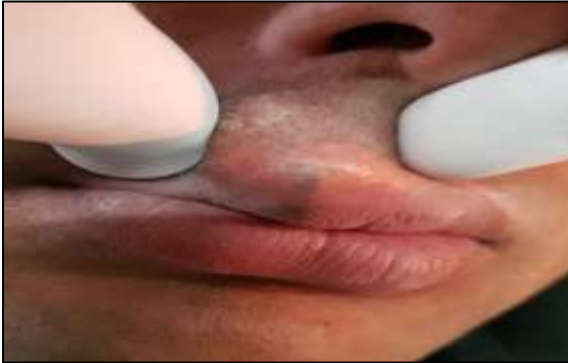

Figure 1: A solitary mass (1.5x1 cm) on right lateral esthetic unit of upper lip with shiny erythematous skin.

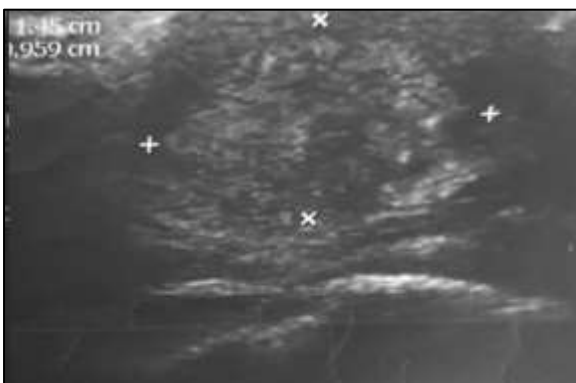

Figure 2: USG showing a cystic mass with heterogeneous echoes.

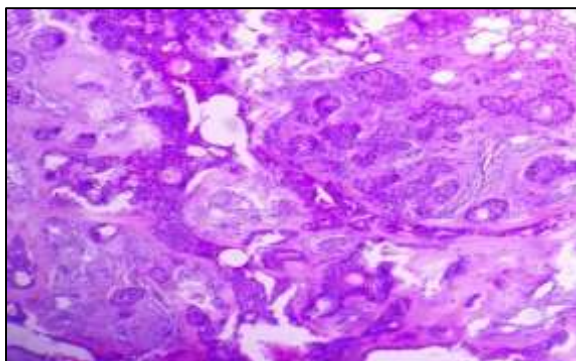


Figure 3: Photomicrograph showing irregular tubuloalveolar structures lined by two layers of epithelial cells (H and E, ×40).

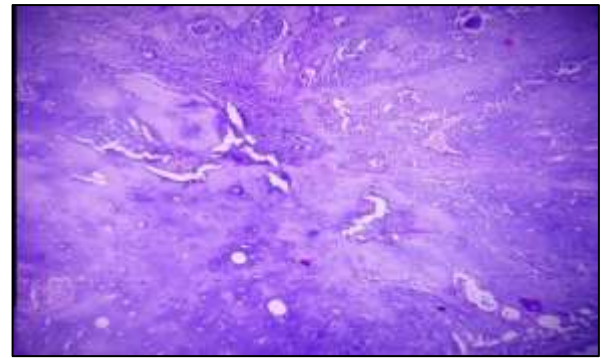


Figure 4: Photomicrograph with cystic tubular structures embedded in a myxoid to chondroid stroma (H and E, ×10).

DISCUSSION

Chondroid syringomas are benign skin adnexal tumours. These mixed tumours are histologically similar to pleomorphic adenomas of salivary glands, but their origin is from sweat glands.⁵ Chondroid syringoma are typically small, painless, slowly growing masses which appear as subcutaneous nodules and can be confused with simple cysts leading to enucleation.

Among the various modalities used for their diagnosis, radiological investigations like ultrasonography and magnetic resonance imaging are not useful as they can only help to determine the extent of the lesion and its relationship with the surrounding structures. Fine needle aspiration cytology is slightly helpful but definitive diagnosis can only be made by histopathological examination which has the following features:

A well circumscribed but unencapsulated, multilobulated mass with a prominent chondroid or myxoid stroma surrounding benign epithelial and myoepithelial cells that form secondary structures like glands and ducts, cysts, reticular lacelike networks, keratinous cysts and foci of squamous differentiation.⁶ Lobules are separated by fibrous septae. Few other cells including plasmacytoid, low cuboidal, spindled, clear cell, cells with follicular and pilomatrical differentiation and mature adipocytes may also be present. Based on the pattern of lumina, these tumours were classified by Hirsch into apocrine or eccrine type.² Treatment of chondroid syringoma is surgical excision.

Malignant form is also reported which may arise de novo or from an incompletely excised benign one. Malignant forms predominantly occur in females, arise from extremities and have no age predilection. They have more aggressive histopathological features such as nuclear atypia, increased mitosis and necrosis.^{7,8} Wide excision with broad margins is their treatment. Chemoradiation is not found to be beneficial in these except for skeletal metastasis.

CONCLUSION

Chondroid syringomas are rare benign subcutaneous tumours. These can be mistaken for epidermal cyst, pilar cyst, calcifying epithelioma, or solitary trichoepithelioma. They are most often benign but malignant transformation can occur. Therefore, early diagnosis and excision is beneficial. If a chondroid syringoma is suspected, a margin of normal tissue should be taken while excision and regular follow up should be done. It should always be taken in differential diagnosis of any subcutaneous nodule in head and neck.

Funding: No funding sources

Conflict of interest: None declared

Ethical approval: Not required

REFERENCES

1. Al-Omran Y, Mohamed R, Al-Omran MK. Chondroid syringoma of the ear lobule: a unique case. Ear Nose Throat J. 2014;93:E62-3.
2. Chen AH, Moreano EH, Houston B, Funk GF. Chondroid syringoma of the head and neck: clinical management and literature review. Ear Nose Throat J. 1996;75(2):104-8.
3. Sungur N, Uysal A, Gumus M, Ugur K, An unusual chondroid syringoma. Dermatol Surg. 2003;29:977-9.
4. Hirsch P, Helwig EB. Chondroid syringoma-mixed tumor of skin, salivary gland type. Arch Dermatol. 1961;84:835-47.
5. Lever WF, Schaumburg-Lever G. Tumors of the epidermal appendages. In Histopathology of the Skin. Philadelphia, JB Lippincott. 1983;6:560-2.
6. Mills SE. Mixed tumor of the skin. A model of divergent differentiation. J Cutan Pathol. 1984;11:382-6.
7. Harnett TJ, Aretz TH, Mihm MC, Jr, Evans GW, Rodriguez FL. Cutaneous malignant mixed tumor. Arch Dermatol. 1981;117(11):719-24.
8. Yavuzer R, Basterzi Y, Sari A. Chondroid syringoma: a diagnosis more frequent than expected. Dermatol Surg. 2003;29(2):179-81.

Cite this article as: Goel A, Aman, Raheja V, Kumari M. Chondroid syringoma of the upper lip: a rare entity. Int J Otorhinolaryngol Head Neck Surg 2020;6:1900-2.