

Original Research Article

Role of narrow band imaging in the detection of mucosal lesions of head and neck

Pranay Bhandari*, Kavita Sachdeva

Department of ENT, NSCB Medical College, Jabalpur, Madhya Pradesh, India

Received: 10 July 2020

Revised: 10 August 2020

Accepted: 11 August 2020

***Correspondence:**

Dr. Pranay Bhandari,

E-mail: pgpbvds@gmail.com

Copyright: © the author(s), publisher and licensee Medip Academy. This is an open-access article distributed under the terms of the Creative Commons Attribution Non-Commercial License, which permits unrestricted non-commercial use, distribution, and reproduction in any medium, provided the original work is properly cited.

ABSTRACT

Background: Head and neck mucosal lesions are difficult to diagnose at early stage; therefore, they usually present at an advance phase. Narrow band imaging (NBI) first came to use around 2005 and became one of the most used technologies for image enhanced endoscopy.

Material and method: In order to identify best method for early detection of mucosal lesion of head and neck, we examined patients with suspected lesions first under white light endoscopy then under NBI endoscopy. Patients underwent biopsy thereafter, and results were compared. Our aim was to evaluate the role of NBI as a screening tool in the early detection of mucosal lesions of head and neck.

Result: It was observed that NBI is useful tool in identifying mucosal lesions of head and neck early. 71 patients were included in our study and it was observed that NBI endoscopy shows 100% sensitivity, 96.36% specificity and 97.18% accuracy in identifying benign lesions. It shows 100% sensitivity, 94.74% specificity and 98.59% accuracy in identifying malignant lesions.

Conclusion: In our study we came to conclusion that NBI is very promising tool for early screening purposes of mucosal lesions of head and neck which were missed in routine examination.

Keywords: Narrow band imaging endoscopy, White light endoscopy, Head and neck mucosal lesion, Intraepithelial papillary capillary loops

INTRODUCTION

Due to the complex anatomy of head and neck, malignancies of upper aero digestive tract are often diagnosed at later stages. Hence the prognosis of head and neck cancer is worsened, which leads to various effects on speech and swallowing. Head and neck cancer can be best diagnosed at an early stage as possible of dysplasia or even carcinoma in situ.¹ It is very difficult to identify early lesions if they are <1 cm², even with multiple passes with endoscope.² Narrow band imaging (NBI) is based on image-enhanced optical digital technology, used in endoscopies. Around 2005 NBI was first came into use, after that in maximum parts of world NBI became one of the most used technologies for doing image-enhanced

endoscopy.³ The present study is to assess the value of NBI in the early detection of mucosal lesions of head and neck.

NBI is based on the principle that it produces blue light, which has less penetration into tissue, hence it alters the colour of capillary network found on mucosal surfaces.⁴ It aimed in such a way that on mucosal surface, blue filters corresponds to peak absorption spectrum of haemoglobin to enhance capillary vessels image (intraepithelial papillary capillary loops-IPCL). Submucosal vascular plexus gets penetrated by 540 nm (green) wavelength light. Brown is the colour shown by capillaries in superficial mucosal layer whereas cyan is the colour shown by deeper mucosal and sub-mucosal vessels. Charge coupled device (CCD) chip captures the reflection

and an image processor makes a composite pseudo-colour image, which will be shown on screen, resulting in NBI to enhance mucosal contrast.⁵ So NBI can detect superficial lesion on the basis of increased vascularity and neo-angiogenesis of the tumour, which were missed by regular white light during endoscopy.¹

Our aim was to evaluate the role of NBI as a screening tool in the early detection of mucosal lesions of head and neck.

METHODS

Study design

Study was prospective study.

Selection criteria

Inclusion criteria were all male and female patients of all ages who were suspected of having mucosal lesions of head and neck; or signs and symptoms suggestive of mucosal lesions of head and neck.

Exclusion criteria were all patients suspected of having vascular tumours and those who refuse to consent.

Collection of data

After evaluating patients in Department of Otorhinolaryngology in NSCB Medical College, Jabalpur (Madhya Pradesh) in period between February 2017 to August 2018. 71 patients were included in study, followed by thorough examination and endoscopy of nose, oral cavity and larynx with 0-degree, 30 degree and 70-degree endoscopes. First examination was done under white light, then with NBI. Lesions were defined on the basis of their morphological appearance as inflammatory, benign, premalignant and malignant.⁵⁻⁸

Under NBI normal mucosal surface is seen as cyan or green in colour with normal vasculature. Inflammatory lesions as brownish areas with ill-demarcated margins, benign lesions will show dilated and crossing IPCLs with clear border, premalignant lesions shows elongated and meandering IPCLs which are mostly associated with dysplasia with unclear border. Neoplastic lesions appear as areas with scattered spots, superficial vessels such as intrapapillary capillary loops (IPCL) are represented by brown spots, usual branching patterns of normal capillary beds is lost.

After examination of these lesions, biopsies were taken and send for histopathological report.

Statistical analysis

Purposive sampling method was applied. Considering the best availability of the patients by reviewing the previous records of this health facility to achieve the maximum sample size we will screen all patients who have fulfil the

inclusion and exclusion criteria and ready to give the written informed consent. All the records were recorded by using structured schedule (Case report form) and entered in Microsoft excel sheet. Considering histopathological report as standard, results from white light endoscopy and NBI endoscopy were compared on the basis of sensitivity, specificity and accuracy.

RESULTS

Out of 71 patients, on white light endoscope 16 lesions were considered as benign lesions. Out of 16 lesions 13 showed benign changes on histopathology report, while 1 showed premalignant change and 2 showed malignant changes. On NBI endoscopy 18 lesion showed benign features. Out of these 18 lesions, 16 lesions showed benign characteristics on histopathology report, except 2 which showed premalignant characteristics. 16 times on histopathology report, lesions showed benign features. Out of them 16 times NBI showed benign features, while white light showed benign features 13 times. Sensitivity for NBI in detecting in benign lesion is about 100% with 96.36% specificity and 97.14% accuracy. Sensitivity for white light for detecting benign lesion is 81.25% with 94.55% specificity and 91.55% accuracy. In figure 3, nasal polyp examined under white light endoscope (A), and then on NBI endoscopy (B). Lesion showed white tumour mass with thin and constant capillaries in NBI endoscopy, suspected as benign nasal polyp (biopsy confirmed the diagnosis).

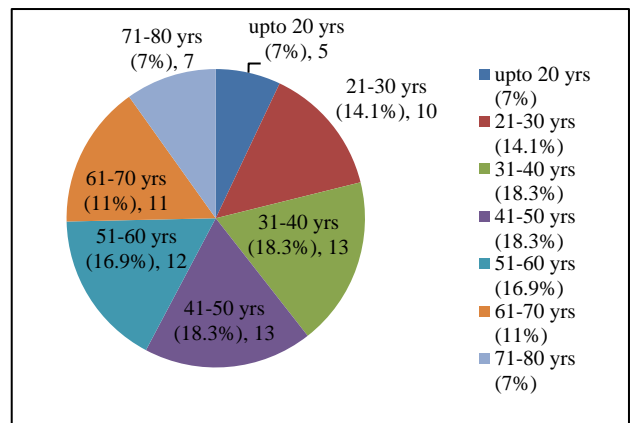


Figure 1: Patient distribution based on age.

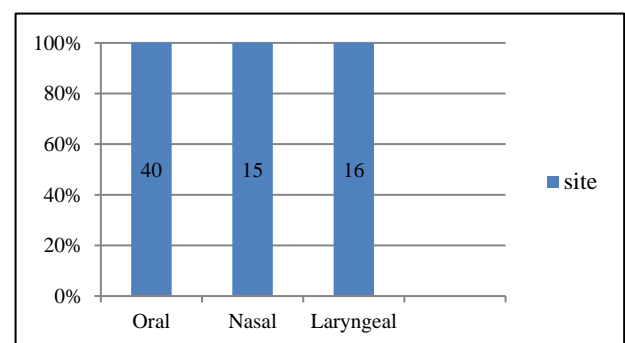


Figure 2: Site of lesion.

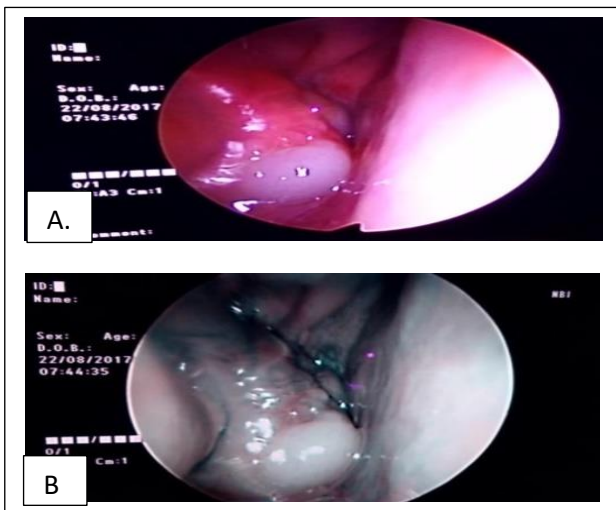


Figure 3: (A) Nasal polyp examined under White light endoscope and (B) on NBI endoscopy.

Table 1: Comparison of lesions considered as benign lesions under White light and NBI endoscopy.

Lesion classified as benign under white light		Lesion classified as benign under NBI	
Yes	No	Yes	No
16	55	18	53

On white light endoscopy 7 lesions were considered to have premalignant features. Out of these 7 lesions no lesion is considered as premalignant under NBI endoscope. On histopathology report out of these 7 lesions, 2 showed benign features while rest 5 showed malignancy. Importance of NBI can be understood as since 7 lesions which were considered as premalignant on White light endoscope, out of them 5 showed malignant features on histopathology report which were also considered as malignant under NBI endoscope.

White light endoscopy showed malignant features in about 44 cases. Out of these 44 lesions, 43 lesions showed malignant features on histopathology. The 1 lesion showed inflammatory features on histopathology was an invasive fungal nasal disease, which showed malignant like features on endoscopy. The same lesion was also considered as malignant on NBI also. On NBI endoscopy 53 lesions were considered as malignant. Out of this, 52 cases reported malignancy on histopathology except 1 nasal case which is described above. White Light endoscopy showed 82.69% sensitivity, 94.74% specificity and 85.92% specificity for detecting malignant lesions, while NBI endoscopy showed 100% sensitivity, 94.74% specificity and 98.59% accuracy.

In figure 4, lesion over tongue examined under White light endoscope (A) which appears to have whitish lesions, sort

of premalignant, then on NBI endoscopy (B) lesion shows ill-defined tumour mass with weaving and abnormal vascularity and increased capillaries (marked by arrows) suspected as malignant mass. Biopsy confirmed the diagnosis.

Table 2: Comparison of lesions considered as malignant lesions under WLI and NBI endoscopy.

Lesion classified as malignant under white light		Lesion classified as malignant under NBI	
Yes	No	Yes	No
44	27	53	18

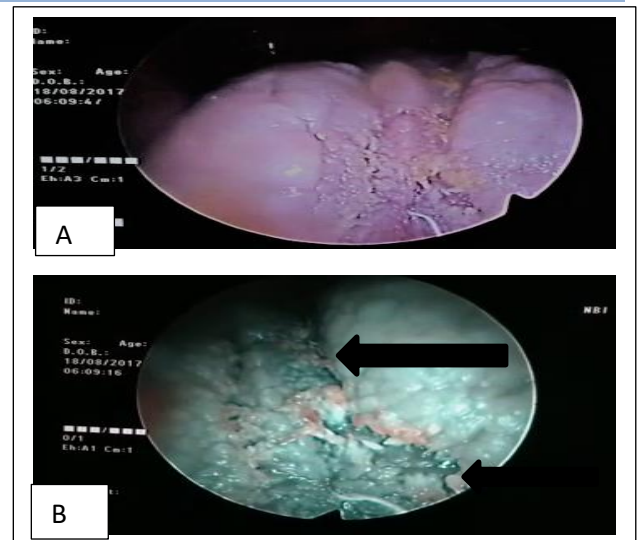


Figure 4: (A) Tongue lesion examined under White light endoscope and (B) on NBI endoscopy.

DISCUSSION

In past 15 years NBI has being subject of study as a promising tool for early detection of mucosal lesions of head and neck. Some of the studies which describe its importance are mentioned in the table 3.

A total of 71 patients were included in study. All 71 patients went under both white light endoscopy and NBI endoscopy. Biopsies were performed, histopathology report shows inflammatory features in 1 lesion, benign features in 16 lesions, premalignant features in 2 lesions and malignant features in 52 lesions. Taking histopathological reports as standard, results were compared from both endoscopies.

Age distribution

In present study maximum lesions were found in age group of 31-40 years and 41-50 years, about 13 cases each.

Table 3: Comparison of different studies on Narrow Band Imaging endoscopy.

Authors	Year of publication	Site	Conclusion
Muto et al ⁹	2004	Evaluating Oropharynx and hypopharynx for squamous cell carcinoma in oesophageal cancer.	34 lesions found in 18 patients. 72% (21 lesions) were histologically confirmed to be carcinoma in situ.
Uedo et al ¹⁰	2006	Evaluating intestinal metaplasia in gastric mucosa	They found 89% sensitivity, 93% specificity and 91% accuracy.
Watanabe et al ¹¹	2006	Endoscopic screening of oropharynx and hypopharynx in oesophageal cancer	NBI could increase sensitivity of detection rate than conventional endoscopy by two-fold.
Piazza et al ¹²	2010	Oropharyngeal SCC	NBI detect 27% times higher than white light.
Wen et al ¹³	2012	Diagnosing nasopharyngeal carcinomas	NBI has higher sensitivity (93.9%) in comparison to white light (71.2%).
Zhou et al ¹⁴	2018	Meta-analysis	NBI has 88.5% sensitivity, 95.6% specificity, 12.33 positive likelihood rate, 0.11 negative likelihood rate.

Site of lesion

Out of 71 cases 40 cases were oral (56.33%), out of 40 cases 33 were malignant (82.5%), 2 were premalignant (5%) and 5 were benign (12.5%). 15 cases were nasal (21.12%), out of them 3 were malignant (20%), 11 cases (73.33%) were benign and 1 case was inflammatory (6.66%). 16 (22.53%) cases were laryngeal all of them were malignant (100%).

Benign lesions

In present study we found that sensitivity for NBI in detecting in benign lesion is about 100% with 96.36% specificity and 97.14% accuracy. Sensitivity for white light for detecting benign lesion is 81.25% with 94.55% specificity and 91.55% accuracy. Yujiro Uchiyama et al in 2006 investigated the ability of magnifying endoscopy with NBI to diagnose and differentiate between benign and malignant ampullary tumours, they concluded that magnifying endoscopy with NBI has the ability and potential to predict histological characteristics of ampullary lesions.¹⁵

Malignant lesions

In present study we found that White Light endoscopy showed 82.69% sensitivity, 94.74% specificity and 85.92% specificity for detecting malignant lesions, while NBI endoscopy showed 100% sensitivity, 94.74% specificity and 98.59% accuracy. YI-Hui Wen et al in 2012 assess the Narrow Band Imaging as a screening tool in nasopharyngeal carcinoma and found that sensitivity and negative predictive values of NBI in nasopharyngeal carcinoma screening were significantly higher than those of WLI (93.9% vs 71.2%; and 98.1% versus 91.7%; respectively).¹³

CONCLUSION

In our study we found that it is difficult to differentiate between invasive fungal disease and malignant lesions merely on the basis of endoscopy. NBI can also be beneficial in highly confusing vascular tumours, by identifying their vascularity and indicating towards it, such as in angiofibroma's appearing in later stages. In our study we also found that white light endoscope could not be able to differentiate some lesions on morphological appearances only, in that instances NBI endoscopy helps to differentiate them on the basis of vascularity. NBI endoscopy shows 100% sensitivity, 96.36% specificity and 97.18% accuracy in identifying benign lesions and 100% sensitivity, 94.74% specificity and 98.59% accuracy in identifying malignant lesions. In our study we found that NBI has capability of identifying malignant lesions, which doesn't appear as malignant on white Light endoscopy. About 9 lesions which were not considered as malignant on white light were identified as malignant lesion on NBI endoscopy, which also showed malignant features on histopathology.

Advantages of narrow band imaging is it increases tissue contrast by differentiating superficial capillaries and neo-angiogenesis in abnormal mucosa, no special dyes are needed and it helps in easy evaluation of lesion and superficial vascular bed. NBI endoscopy is a non-invasive technique. In our study we conclude that narrow band imaging endoscopy provides a very promising tool for early screening purposes of mucosal lesions of head and neck.

Funding: No funding sources

Conflict of interest: None declared

Ethical approval: The study was approved by the Institutional Ethics Committee

REFERENCES

1. Piazza C, Dessouky O, Peretti G, Cocco D, De Benedetto L, Nicolai P. Narrow-band imaging: a new tool for evaluation of head and neck squamous cell carcinomas. Review of the literature. *Acta otorhinolaryngologica italica.* 2008;28(2):49.
2. Watanabe A, Tsujie H, Taniguchi M, Hosokawa M, Fujita M, Sasaki S. Laryngoscopic detection of pharyngeal carcinoma in situ with narrowband imaging. *The Laryngoscope.* 2006;116(4):650-4.
3. Gono K. Narrow band imaging. technology basis and research and development history. *Clin Endosc.* 1948(6):476-480.
4. Uedo N, Ishihara R, Iishi H, Yamamoto S, Yamada T, Imanaka K, et al. A new method of diagnosing gastric intestinal metaplasia: narrow-band imaging with magnifying endoscopy. *Endoscopy.* 2006;38(08):819-24.
5. Kamath G, Chatterjee I, Srikanth HS, Babshet M. Narrow-band imaging: Breakthrough at the forefront of medicine. *Indian Journal of Oral Sciences.* 2016;7(1).
6. Takano JH, Yakushiji T, Kamiyama I, Nomura T, Katakura A, Takano N, Shibahara T. Detecting early oral cancer: narrowband imaging system observation of the oral mucosa microvasculature. *Int J Oral Maxillofacial Surg.* 2010;39(3):208-13.
7. Yang SW, Lee YS, Chang LC, Hwang CC, Luo CM, Chen TA. Use of endoscopy with narrow-band imaging system in evaluating oral leukoplakia. *Head Neck.* 2012;34(7):1015-22.
8. Yang SW, Lee YS, Chang LC, Hsieh TY, Chen TA. Implications of morphologic patterns of intraepithelial microvasculature observed by narrow-band imaging system in cases of oral squamous cell carcinoma. *Oral oncology.* 2013;49(1):86-92.
9. Muto M, Nakane M, Katada C, Sano Y, Ohtsu A, Esumi H, et al. Squamous cell carcinoma in situ at oropharyngeal and hypopharyngeal mucosal sites. *Cancer: Interdisciplinary International Journal of the American Cancer Society.* 2004;101(6):1375-81.
10. Uedo N, Ishihara R, Iishi H, Yamamoto S, Yamada T, Imanaka K, et al. A new method of diagnosing gastric intestinal metaplasia: narrow-band imaging with magnifying endoscopy. *Endoscopy.* 2006;38(08):819-24.
11. Watanabe A, Tsujie H, Taniguchi M, Hosokawa M, Fujita M, Sasaki S. Laryngoscopic detection of pharyngeal carcinoma in situ with narrowband imaging. *The Laryngoscope.* 2006;116(4):650-4.
12. Piazza C, Cocco D, Del Bon F, Mangili S, Nicolai P, Majorana A, et al. Narrow band imaging and high definition television in evaluation of oral and oropharyngeal squamous cell cancer: a prospective study. *Oral oncology.* 2010;46(4):307-10.
13. Wen YH, Zhu XL, Lei WB, Zeng YH, Sun YQ, Wen WP. Narrow-band imaging: a novel screening tool for early nasopharyngeal carcinoma. *Archives of otolaryngology-head & neck surgery.* 2012;138(2):183-8.
14. Zhou H, Zhang J, Guo L, Nie J, Zhu C, Ma X. The value of narrow band imaging in diagnosis of head and neck cancer: a meta-analysis. *Scientific reports.* 2018;8(1):1-1.
15. Uchiyama Y, Imazu H, Kakutani H, Hino S, Sumiyama K, Kuramochi A, et al. Tsukinaga S, Matsunaga K, Nakayoshi T, Goda KI, Saito S. New approach to diagnosing ampullary tumors by magnifying endoscopy combined with a narrow-band imaging system. *Journal of gastroenterology.* 2006;41(5):483-90.

Cite this article as: Bhandari P, Sachdeva K. Role of narrow band imaging in the detection of mucosal lesions of head and neck. *Int J Otorhinolaryngol Head Neck Surg* 2020;6:1678-82.